

Periungual Bowenoid Papulosis Due to Human Papillomavirus Type 42[☆]

Papulosis bowenoide periungueal por virus del papiloma humano 42

To the Editor:

A 28-year-old man with no relevant past medical history consulted for a progressive, slow-growing exophytic lesion at the edge of the nail of the middle finger on the left hand. The lesion had been present for 2 years. The patient reported that he had had multiple sexual partners up to 6 years earlier.

Physical examination revealed a red-grayish exophytic periungual lesion measuring 0.7cm in diameter with a hyperkeratotic surface (Fig. 1). Histopathologic examination showed a hyperplastic epidermis with loss of normal cell architecture, moderate cellular atypia, dyskeratosis, and koilocytes in the epidermis (Fig. 2). Overexpression of the tumor suppressor protein p16 was also observed (Fig. 3). Based on a diagnosis of extragenital bowenoid papulosis, the patient was re-questioned, but he reported that neither he nor his current partner had had genital or anal warts. Lymphocyte counts (including CD4 and CD8 counts) were normal and serologic testing for human immunodeficiency virus (HIV) was negative. Human papillomavirus (HPV) DNA testing using the hybrid capture assay detected HPV 42. It was decided to excise the entire lesion and schedule periodic

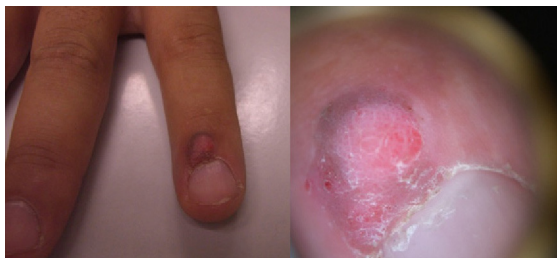

Figure 1 Red-grayish exophytic periungual lesion with a hyperkeratotic surface.

follow-up visits for the patient and his partner. The patient was asymptomatic a year after diagnosis.

The term *bowenoid papulosis* was introduced to describe multiple wart-like papules in the genital region that are histologically similar to Bowen disease and clinically similar to genital warts. The condition typically affects young, sexually active individuals and mainly involves the genital, crural, and perianal regions. However, there have also been reports of extragenital bowenoid papulosis with or without concomitant genital lesions in both immunocompetent and immunodeficient patients.¹

Bowenoid papulosis is associated with HPV infection. While there is a close link with HPV 16 infection,^{1,2} types 18, 31-35, 39, 42, 48, and 51-54 have also been implicated.¹⁻⁴

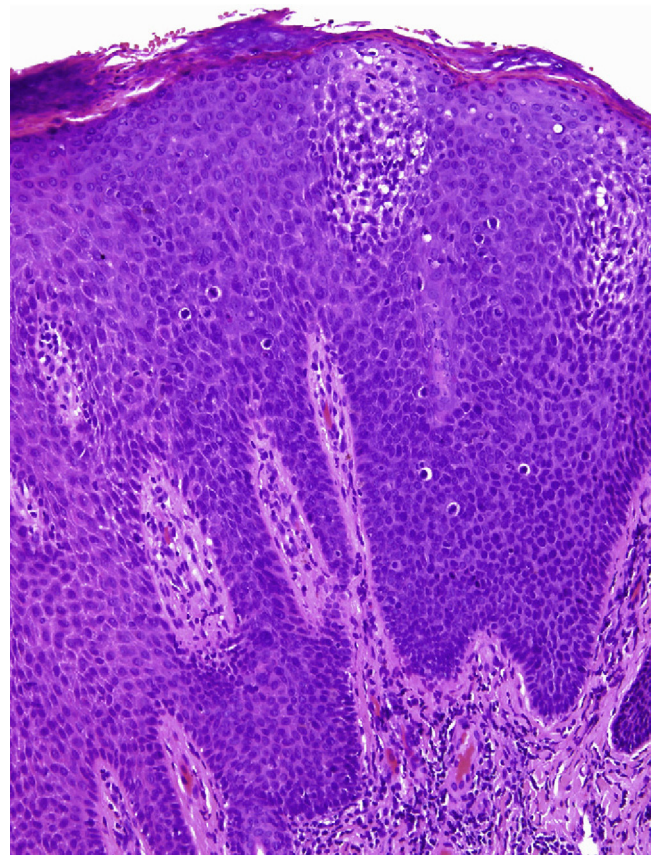


Figure 2 Hypoplastic epidermis with loss of normal cell architecture, moderate cellular atypia, dyskeratosis, and koilocytes (hematoxylin-eosin, original magnification $\times 40$).

HPV 16, 18, and 33 are considered to have the greatest oncogenic potential.

Bowenoid papulosis is considered to be a squamous cell carcinoma in situ and has an estimated risk of malignant transformation of 2.6%.² The oncogenic mechanism is probably initiated by HPV-induced genetic changes in infected cells. High-risk serotypes produce HPV oncoproteins E6 and E7, which are capable of inactivating the Rb and p53 tumor suppressor proteins, respectively, giving rise to uncontrolled cell proliferation.⁴ HPV has been detected in bowenoid papulosis lesions and adjacent healthy skin, indicating that HPV infection is a necessary but not sufficient factor in the development of bowenoid papulosis. Other alterations, such as additional genetic mutations in the host cell, may be necessary.^{3,4}

Bowen papulosis is histologically similar to Bowen disease, but exhibits more focal and less intense changes.^{1,5,6} To distinguish between the 2 entities, it is always necessary to correlate clinical and histologic findings.

The prevalence of Bowenoid papulosis is unknown, as the lesions are commonly confused with other wart-like lesions and are frequently destroyed without histological examination.⁷ Since the lesions tend to recur and have malignant potential, patients and their sexual partners should be referred for periodic follow-up and an immunological study in the case of persistent or recurrent lesions.⁷ The clinical course is variable, with some lesions

[☆] Please cite this article as: Gómez Vázquez M, Navarra Amayuelas R. Papulosis bowenoide periungueal por virus del papiloma humano 42. *Actas Dermosifiliogr*. 2013;104:932-934.

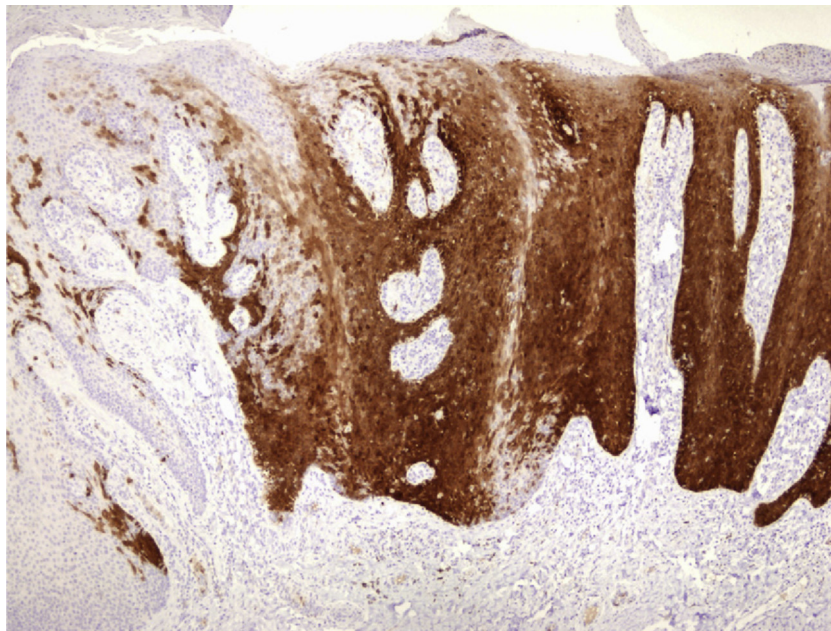


Figure 3 Overexpression of tumor suppressor protein p16.

progressing to chronic or malignant forms and others spontaneously regressing. Conservative treatment involving destruction of the lesions by simple excision, electrocoagulation, or cryosurgery is the most effective therapeutic approach.^{6,8}

Bowenoid papulosis generally occurs with concomitant genital lesions or in patients with a history of HPV-induced lesions⁸⁻¹⁰ (Table 1). Transmission is believed to occur through direct contact, autoinoculation, or fomites.^{1,2,7,9} These transmission mechanisms would explain the involvement of different parts of the body. Reports in the literature describe lesions affecting the neck, the abdomen, the shoulder, the chin, and the periungual area, among others.¹⁻¹⁰

We have reported a new case of bowenoid papulosis affecting the periungual area of a finger in a patient with no past or present history of genital lesions. Two similar cases of extragenital bowenoid papulosis have been reported in the literature. One of the patients had bowenoid papulosis lesions in the perianal area that were detected on diagnosis of the nail lesion¹⁰ and the other patient had HIV infection.⁴ We believe that lesions in young sexually active patients should be examined histologically, even when they are located at a distance from the genital region. The possibility of immunosuppressive conditions should be investigated, as should the presence of genital lesions in the patients and their partners.

Table 1 A Selection of Published Cases of Extragenital Bowenoid Papulosis.

Cases	Immunodeficiency	Site	HPV Detected	Transmission	Genital Lesions
Bart ⁵	Not known	Chin	Not tested		Not known
Grussendorg-Conen ⁶		Neck	HPV 16		No
Rüdlinger et al. ³	No	Periungual	HPV 35	Direct contact	Yes
Grob et al. ⁷	No	Neck	HPV 16	Razor	No
Johnson et al. ¹	No	Neck	42	Razor	No
Fader et al. ²	HIV	Neck	HPV 31, 33, 35	Razor	Yes (in the past)
Baron et al. ⁹		Neck	18		
Purnell et al. ¹⁰	Idiopathic CD4 ⁺ lymphocytopenia	Finger	18		No
Papadopoulos et al. ⁴	No	Shoulder	6, 1, 42, 43, 44		No
	HIV	Abdomen	Not identified		No
Oh et al. ⁸	No	Toe webs	16	Tinea pedis	No
Our case	No	Periungual	42		No

Abbreviation: HIV, human immunodeficiency virus; HPV, human papillomavirus.

References

1. Johnson TM, Saluja A, Fader D, Blum D, Cotton J, Wang TS, et al. Isolated extragenital bowenoid papulosis of the neck. *J Am Acad Dermatol.* 1999;41:867–70.
2. Fader DJ, Stoler MH, Anderson TF. Isolated extragenital HPV-thirties-group-positive bowenoid papulosis in an AIDS patient. *Br J Dermatol.* 1994;131:577–80.
3. Rüdinger R, Grob R, Yuan XY, Rus WS. Human papillomavirus-35-positive bowenoid papulosis of the anogenital area and concurrent human papillomavirus-35-positive verruca with bowenoid dysplasia of the periungual area. *Arch Dermatol.* 1989;125:655–9.
4. Papadopoulos AJ, Schwartz RA, Lefkowitz A, Tinkle LL, Jänniger CK, Lambert WC. Extragenital bowenoid papulosis associated with atypical human papillomavirus genotypes. *J Cutan Med Surg.* 2002;6:1117–9.
5. Bart R. Bowenoid papulosis of the chin. *J Dermatol Sug Oncol.* 1984;10:821–3.
6. Grussendorf-Conen EI. HPV-16 induzierte pigmentierte bowenoid papulosis am hals. *Akt Dermatol.* 1988;14:317–9.
7. Grob JJ, Zarour H, Jacquemier J, Hassoun J, Bonerandi JJ. Extra-anogenital HPV16-related bowenoid papulosis. *Genitourin Med.* 1991;67:18–20.
8. Oh SH, Lee JH, Lee KY, Lee KH. Isolated extragenital bowenoid papulosis of the toe-webs. *Acta Dermatol Venereol.* 2009;89:212–3.
9. Baron JM, Rübber A, Grussendorf-Conen EI. HPV-18 induced pigmented papulosis of the neck. *J Am Acad Dermatol.* 1999;40:633–4.
10. Purnel D, Illchyshyn A, Jenkins D, Salim A, Seth R, Snead D. Isolated human papillomavirus 18-positive extragenital bowenoid papulosis and idiopathic CD4+ lymphocytopenia. *Br J Dermatol.* 2001;144:619–21.

M. Gómez Vázquez,* R. Navarra Amayuelas

Servicio de Dermatología, Hospital Municipal de Badalona, Badalona Serveis Assistencials, Barcelona, Spain

*Corresponding author.

E-mail address: mergova@terra.es (M. Gómez Vázquez).

Extensive Bowenoid Papulosis of the Vulva Treated by Carbon Dioxide Laser in a Patient With AIDS[☆]

Tratamiento con láser de dióxido de carbono de una papulosis bowenoide vulvar extensa en paciente con sida

To the Editor:

Bowenoid papulosis of the genitalia in immunocompromised patients is associated with a high risk of recurrence and transformation to infiltrating squamous cell carcinoma on the one hand, and poor response to treatment on the other.^{1,2}

We describe the case of a 50-year-old female smoker diagnosed with human immunodeficiency virus (HIV) infection in 1989 and invasive cervical cancer in 2000. She also had chronic hepatitis C infection complicated by cirrhosis. She had had histopathologically confirmed bowenoid papulosis since 2004. Treatments had included electrocoagulation, cryotherapy, podophyllin resin, as well as imiquimod, but with poor response and tolerance.

When the patient first visited our hospital in March 2005, she had a brownish plaque with well-defined borders and a verrucous surface covering almost the entire area of the external genitalia and the perianal area (Fig. 1A). A new biopsy confirmed the diagnosis of bowenoid papulosis. In December 2005, we decided to administer continuous-wave carbon dioxide (CO₂) laser therapy at a power of 7.5 W to treat the affected area and the acetowhite lesions identified; a lateral safety margin of 4 to 5 mm was also

treated due to the possible presence of subclinical human papillomavirus (HPV) infection. The procedure was performed with the patient under epidural anesthesia. The treated areas were subsequently cleaned and dressed with an antibiotic ointment, and prophylactic valacyclovir was prescribed at a dose of 500 mg every 8 hours until complete reepithelization. Total clinical resolution of the lesions was observed at 1 month. The patient underwent follow-up examinations every 3 to 6 months, in addition to 4 treatment sessions with the same anesthesia, fluence, and postoperative care in October 2006, December 2007, April 2009, and June 2009. Complete clinical resolution was achieved each time (Fig. 1 B-G). The patient's CD4 count during follow-up is shown in Fig. 2. The control biopsies showed typical features of bowenoid papulosis, with no signs of infiltrating squamous cell carcinoma. During follow-up, the patient was diagnosed with hepatocellular carcinoma in 2008 and with a high-grade anal neoplasm in 2009. The respective treatments were chemoembolization and surgery followed by consolidation radiation therapy.

In all, over a period of 6 years we performed 5 sessions of CO₂ laser therapy, the last of which was in April 2009; no adverse effects were observed in any of the sessions. The patient remained free of lesions in the vulvar area from September 2009 until December 2010, when she died following progression of her hepatocellular carcinoma. The only treatment required during this period was cryotherapy of isolated lesions in the area.

CO₂ laser therapy causes minimal postoperative pain³ and produces better cosmetic results than other methods, especially when used on the external genitals.⁴ It has been used since 1988 to treat large bowenoid papulosis lesions that are difficult to treat with other methods.⁵ The primary complications described to date are vesicovaginal fistulas⁶ and vulvodinia, especially of the posterior commissure or the vulval vestibule.⁷ CO₂ laser therapy for bowenoid papulosis lesions achieves complete response, and the rate of recurrence is between 12.5% and 21%.⁸ The

[☆] Please cite this article as: Llamas-Velasco M, Vargas E, Delgado Y, García-Diez A. Tratamiento con láser de dióxido de carbono de una papulosis bowenoide vulvar extensa en paciente con sida. *Actas Dermosifiliogr.* 2013;104:934–936.