

PL can occur at any age, but it is particularly common in children, with incidence peaking at 2, 5, 10, and 12 years of age.³ It is very rare in the first year of life. In our review of the literature, we found only 9 cases of onset before the age of 12 months. These included 1 congenital case,⁴ 3 cases with onset at 8 months of age,⁵⁻⁷ and 1 case with onset at 11 months of age.⁸ We also found mention of an additional 4 cases in children aged under 1 year in a retrospective study of 124 children with PL.³ In the 9 cases described in the literature, all the patients (8 boys and 1 girl) were otherwise healthy. There was just 1 case with a history of previous infection, in which pneumococci and *Haemophilus influenza* were isolated.⁶ Six of the patients had lesions clinically consistent with PLEVA, with ulceronecrotic lesions that resolved with topical corticosteroid therapy in a maximum of 2 months.^{3,7,8} The remaining 3 patients had lesions that were clinically and histologically consistent with PL chronica.⁴⁻⁶ The disease followed an indolent course in 2 patients, 1 of whom developed an indurated plaque in the right iliac fossa after a year and a half. The plaque was initially compatible with lymphomatoid papulosis but 2 years later, it was histologically diagnosed as cutaneous T-cell lymphoma.⁵ The second patient developed parapsoriasis at 10 years of follow-up.⁶

Given the scarcity of cases in the literature, no clear conclusions can be drawn, but based on our review, PL would appear to be very rare in children under 12 months of age, with just 10 cases, including ours, reported to date. Within this age group, PL is more common in boys and tends to occur in an acute form and to resolve spontaneously without complications. Nevertheless, given the possible association with lymphoproliferative disorders, long-term monitoring is recommended.

References

- Dereure O, Levi E, Kadin ME. T-Cell clonality in pityriasis lichenoides et varioliformis acuta: a heteroduplex analysis of 20 cases. *Arch Dermatol.* 2000;136:1483-6.
- Romani J, Puig L, Fernández-Figueras M, De Moragas JM. Pityriasis lichenoides in children: clinicopathologic review of 22 patients. *Pediatr Dermatol.* 1998;15:1-6.
- Ersoy-Evans S, Greco F, Mancini AJ, Subasi N, Paller AS. Pityriasis lichenoides in childhood: a retrospective review of 124 patients. *J Am Acad Dermatol.* 2007;56:205-10.
- Chand S, Srivastava N, Khopkar U, Singh S. Pityriasis lichenoides chronica: onset at birth. *Pediatr Dermatol.* 2008;25:135-6.
- Thomson KF, Whittaker SJ, Russel-Jones R, Charles-Holmes R. Childhood cutaneous T-cell lymphoma in association with pityriasis lichenoides chronica. *Br J Dermatol.* 1999;141:1146-8.
- Niemczyk UM, Zollner TM, Wolter M, Staib G, Kaufmann R. The transformation of pityriasis lichenoides chronica into parakeratosis variegata in an 11-year-old girl. *Br J Dermatol.* 1997;137:983-7.
- Gelmetti C, Rigoni C, Alessi E, Ermacora E, Berti E, Caputo R. Pityriasis lichenoides in children: a long-term follow-up of eighty-nine cases. *J Am Acad Dermatol.* 1990;23:473-8.
- Hoshina D, Akiyama M, Hamasaka K, Shimizu H. An infantile case of pityriasis lichenoides et varioliformis acuta. *Br J Dermatol.* 2007;157:194-6.

M.T. López-Villaescusa,^a Á. Hernández-Martín,^{b,*} I. Colmenero,^c A. Torrelo^b

^a Servicio de Dermatología, Complejo Hospitalario Universitario de Albacete, Albacete, Spain

^b Servicio de Dermatología, Hospital Infantil Niño Jesús, Madrid, Spain

^c Servicio de Anatomía Patológica, Hospital Infantil Niño Jesús, Madrid, Spain

* Corresponding author.

E-mail address: ahernandez_hnj@yahoo.es (Á. Hernández-Martín).

<http://dx.doi.org/10.1016/j.adengl.2012.08.023>

Periungual Acral Fibrokeratoma: Surgical Excision Using a Banner Flap[☆]

Fibroqueratoma acral periungueal: exéresis quirúrgica en bandera

To the Editor

The surgical treatment of periungual tumors is complicated by the risk of causing irreversible nail dystrophy. However, incomplete resection leads to a high risk of recurrence, and

surgery must therefore eliminate the whole tumor while preserving the germinal cells of the nail matrix.

We present the case of a 31-year-old man who was seen in outpatients for a firm, pink, digitiform tumor of about 5 × 3 mm that had been present on the fifth toe of the left foot for about 5 months (Fig. 1). The base of the lesion was beneath the eponychium but above the nail plate. The patient did not recall any history of trauma, and there was no family history or presence of other lesions suggestive of tuberous sclerosis. The clinical diagnosis was periungual fibroma and, as the patient reported discomfort due to friction against his footwear, it was decided to excise the lesion as an elective procedure.

The operation was performed under local anesthesia with 2% mepivacaine, and a glove was tied around the proximal part of the digit as a tourniquet to provide a bloodless

[☆] Please cite this article as: Yélamos O, Alegre M, Garcés JR, Puig L. Fibroqueratoma acral periungueal: exéresis quirúrgica en bandera. *Actas Dermosifiliogr.* 2013;104:830-832.

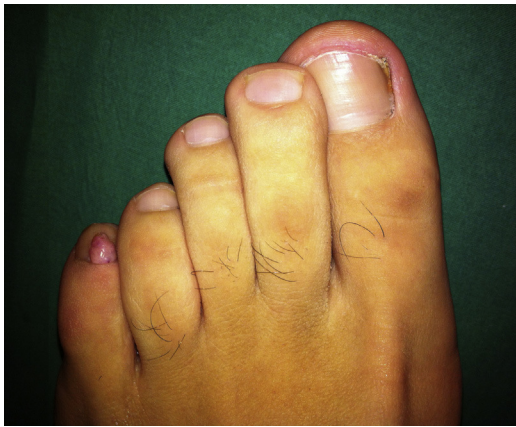

Figure 1 Acral fibrokeratoma on the fifth toe of the left foot.

surgical field. Two longitudinal incisions were then made into the proximal nail fold, one on each side of the lesion. The proximal nailfold was then elevated (Fig. 2), exposing the whole tumor and enabling us to dissect and excise the lesion completely. During the procedure, special care was taken not to damage the matrix.

After resection, the flap was replaced to cover the defect and was sutured with interrupted 5/0 silk sutures, starting at the part closest to the cuticle. As the flap was narrow, the knots were placed outside its borders in order to prevent ischemia. Hemostasis was ensured by the application of Monsel solution with a swab onto the surgical wound, and there were no complications on removal of the tourniquet. Finally, mupirocin ointment was applied and the area was covered with tulle gras, gauze, and an adhesive dressing. Histology of the surgical specimen revealed stromal fibrosis with vascular ectasia, compatible with fibrokeratoma. Follow-up at 1 year showed no nail dystrophy and no recurrence of the lesion.

Acral fibrokeratoma is a benign and typically solitary tumor. It is the color of normal skin and may be dome- or horn-shaped. This tumor may arise secondary to trauma.¹ The term *acral fibrokeratoma* encompasses several entities, including acquired digital fibrokeratoma, acquired periungual fibrokeratoma, “garlic-clove” fibroma, and the

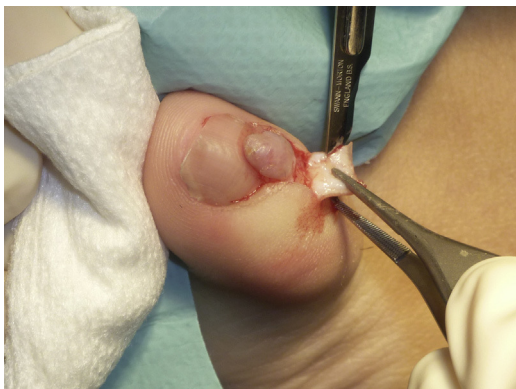

Figure 2 Banner flap: 2 longitudinal incisions are made into the proximal nail fold, one on either side of the lesion.

subungual and periungual fibromas characteristic of tuberous sclerosis.² These tumors should be excised when they cause symptoms or significant cosmetic problems.

Various surgical techniques can be used to resect these tumors, depending on whether they arise from above or below the nail plate. Lesions beneath the nail plate require partial or total removal of the nail. Lesions above the nail plate, on the other hand, can be removed by shaving followed by phenolization,³ carbon-dioxide laser vaporization,⁴ or, more usually, surgical resection after lifting the proximal nail fold as a banner flap.⁵

Surgical resection is usually performed under nerve block anesthesia. Two oblique incisions are made in the proximal nail fold, one at each end of the eponychium; the whole proximal nail fold can then be lifted to expose the lesion. This allows the base of the lesion to be evaluated and complete excision performed, preventing future recurrence, without damaging the nail matrix.^{6–8} We used a simpler variant of this technique in which the 2 incisions were made along the borders of the tumor instead of making them at the medial and lateral ends of the eponychium.

It is important to note that this type of lesion has a tendency to bleed despite suturing, and correct hemostasis is therefore essential. The use of vasoconstrictors is not recommended in acral regions due to the risk of distal ischemia; a simple digital tourniquet will adequately control bleeding. In addition, Monsel solution—a ferric sulphate solution that has a high local hemostatic potential—can be used to ensure correct hemostasis.⁹ Monsel solution is applied directly with a cotton bud or gauze swab after suturing.

We thus propose this technique as a useful alternative to wedge or punch excision. These other procedures usually provide poorer visualization of the lesion, with a higher risk of recurrence due to incomplete excision of the lesion or nail dystrophy if the resection is too wide. In addition, the technique described preserves the supralesional skin of the proximal nail fold, which reduces tension in the scar and achieves excellent cosmetic results. The banner flap is therefore a simple and very practical technique for small periungual lesions.

References

1. Hare PJ, Smith PA. Acquired (digital) fibrokeratoma. *Br J Dermatol.* 1969;81:667–70.
2. Weedon D. *Weedon's Skin Pathology.* 3rd ed. London: Churchill Livingstone Elsevier; 2010. p. 812–3.
3. Mazaira M, del Pozo Losada J, Fernández-Jorge B, Fernández-Torres R, Martínez W, Fonseca E. Shave and phenolization of periungual fibromas, Koenen's tumors, in a patient with tuberous sclerosis. *Dermatol Surg.* 2008;34:111–3.
4. Berlin AL, Billick RC. Use of CO₂ laser in the treatment of periungual fibromas associated with tuberous sclerosis. *Dermatol Surg.* 2002;28:434–6.
5. Vázquez-Doval FJ. Cirugía de la región ungueal. In: *Atlas de enfermedades de las uñas.* Barcelona: ESMONpharma; 2008. p. 112–3.
6. Saito S, Ishikawa K. Acquired periungual fibrokeratoma with accessory germinal matrix. *J Hand Surg Br.* 2002;27:549–55.

7. Lee CY, Lee KY, Kim KH, Kim YH. Total excision of acquired periungual fibrokeratoma using bilateral proximal nail fold oblique incision for preserving nail matrix. *Dermatol Surg.* 2010;36:139–41.
8. Carlson RM, Lloyd KM, Campbell TE. Acquired periungual fibrokeratoma: a case report. *Cutis.* 2007;80:137–40.
9. Epstein E, Maibach HI. Monsel's solution: history, chemistry, and efficacy. *Arch Dermatol.* 1964;90:226–8.

O. Yélamos,* M. Alegre, J.R. Garcés, L. Puig

Servicio de Dermatología, Hospital de la Santa Creu i Sant Pau, Barcelona, Spain

* Corresponding author.

E-mail address: oyelamos@santpau.cat (O. Yélamos).

<http://dx.doi.org/10.1016/j.adengl.2012.10.014>

Fox-Fordyce Disease With an Atypical Clinical Presentation[☆]

Enfermedad de Fox-Fordyce con presentación clínica atípica

To the Editor:

Fox-Fordyce disease (FFD), or apocrine miliaria, is a rare inflammatory disease of the apocrine glands characterized by the presence of pruritic follicular papules in apocrine-rich areas of the skin. We present a case of histologically confirmed FFD with extensive involvement of 2 unusual sites, the chest and abdomen.

A 39-year-old woman was referred for evaluation of an asymptomatic rash that had appeared 2 years earlier. There was no significant personal or family medical history. The rash had first appeared in the presternal area and had then spread over the abdomen to the pubic region. The rash consisted of multiple minute nonconfluent red-to-yellow

papules on the breasts and especially the lower chest and abdomen, as far as the pubic region (Fig. 1). The axillae, areolae, and genitals were uninvolved.

Histologic examination of a papule from the lower presternal region revealed dilatation and hyperkeratotic plugging of the follicular infundibulum, which was surrounded by abundant foamy histiocytes (xanthomized macrophages) (Fig. 2); a mild-to-moderate periadnexal chronic lymphocytic inflammatory response; and clusters of apocrine cells, with a tendency to cystic dilatation, between the reticular dermis and hypodermis (Fig. 3).

There were no relevant findings in the blood panel and the basic hormone panel, which included testosterone, dehydroepiandrosterone sulfate, progesterone, estradiol, luteinizing hormone, and follicle-stimulating hormone.

No improvement was noted after successive attempts at topical treatment with tretinoin, corticosteroids, and clindamycin.

FFD was first described by Fox and Fordyce in 1902.¹ This rare skin condition is most common in women aged 13 to 35 years. The etiology and pathogenesis of FFD are unknown,

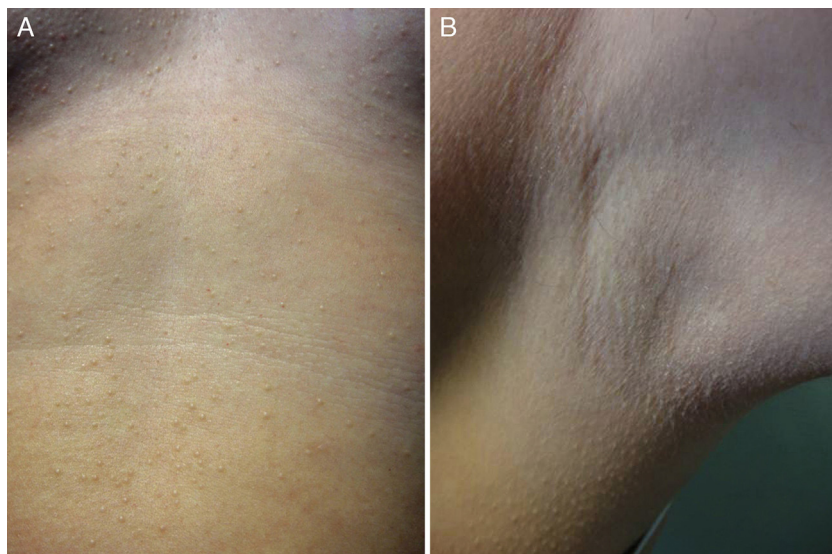


Figure 1 A, Multiple minute nonconfluent red-to-yellow papules on the chest and abdomen. B, The axillae were not involved.

[☆] Please cite this article as: Ballester I, López-Ávila Á, Ortiz S. Enfermedad de Fox-Fordyce con presentación clínica atípica. *Actas Dermosifiliogr.* 2013;104:832–834.