



ACTAS Derma-Sifiliográficas

Full English text available at
www.actasdermo.org



CASE AND RESEARCH LETTERS

Superficial Granulomatous Pyoderma. Report of 2 Cases Treated With Topical Tacrolimus[☆]

Pioderma granulomatoso superficial. Presentación de 2 casos tratados con tacrolimus tópico

To the Editor:

Superficial granulomatous pyoderma (SGP) or pyoderma vegetans is a rare inflammatory disease first described by Wilson-Jones and Winkelmann in 1988.¹ Although considered a superficial, vegetative variant of pyoderma gangrenosum (PG), SGP has distinguishing features such as a chronic and slowly progressive course, lack of association with other diseases, shallower ulcers, the presence on histology of characteristic 3-layered granulomas,² and better response to treatment (Table 1).

We present 2 cases of SGP that were successfully treated with topical tacrolimus, with no recurrence after 5 years.

Case 1

A 77-year-old man with a history of hypertension and type 2 diabetes mellitus presented in July 2003 with erosive papular lesions, some of them with follicular dominance. The lesions coalesced to form plaques prone to ulceration and the formation of crusts on the buttocks and scalp (Fig. 1A). On the upper back he had a horseshoe-shaped ulcer measuring 7 × 10 cm with an atrophic center and erythematous-violaceous borders (Fig. 1B). The lesions had first appeared several months earlier and had been treated with topical antibiotics and oral cephalosporins. No improvement was observed. Cultures for bacteria, fungi, and mycobacteria were negative. Skin biopsy revealed an acute and chronic inflammatory infiltrate that was predominantly follicular, with rupture of the follicular

epithelium and a granulomatous reaction with giant cells (Fig. 1C). Results of laboratory tests were within the normal range. The patient received successive treatments with corticosteroids and topical antibiotics, oral tetracyclines, trimethoprim-sulfamethoxazole, colchicine, and isotretinoin, but little improvement was noted. Finally, after 6 months of treatment with topical tacrolimus 0.1% the lesions healed, leaving cribriform scars (Fig. 1D and 1E).

Case 2

A 33-year-old woman with a history of schizophrenia came to our clinic with lesions on the right breast that had appeared a year earlier. She reported a history of right breast abscess that had required drainage by her gynecologist. Since then she had had erosive lesions with erythematous-violaceous borders on the upper outer quadrant of the breast that had not improved with topical antibiotics (Fig. 2A). Cultures for bacteria, fungi, and mycobacteria were negative. A biopsy revealed a dense, mixed dermal infiltrate of plasma cells and suppurative granulomas (Fig. 2B). No microorganisms or foreign bodies were observed. Laboratory tests revealed only subclinical hypothyroidism. Following application of tacrolimus 0.1% ointment twice daily for 12 months, the lesions resolved.

SGP is a rare condition for which we found some 60 references in the literature. It usually presents on the trunk as a slow-growing, painless superficial ulcer with vegetative borders, although SGP lesions have been reported on the face, the limbs, and even the scrotum.^{3,4} When SGP is located on the face it is important to consider a diagnosis of Wegener disease.³ Although SGP has a more indolent course than PG and usually responds better to treatment, chronicity and recurrence are common.

SGP rarely accompanies systemic diseases, although isolated cases have been associated with chronic lymphatic leukemia, polymyalgia rheumatica, IgA paraproteinemia, sarcoidosis, rheumatoid arthritis, and ulcerative colitis.⁵

Histology characteristically reveals a superficial dermal abscess or ulcer which tends to form granulomas in 3 layers: a central zone with neutrophils, cellular debris, and evidence of bleeding; a surrounding layer of histiocytes and giant cells; and an outer layer of plasma cells and eosinophils.² Although not all cases have this characteris-

[☆] Please cite this article as: Ormaechea-Pérez N, et al. Pioderma granulomatoso superficial. Presentación de 2 casos tratados con tacrolimus tópico. Actas Dermosifiliogr. 2013;104:721–4.

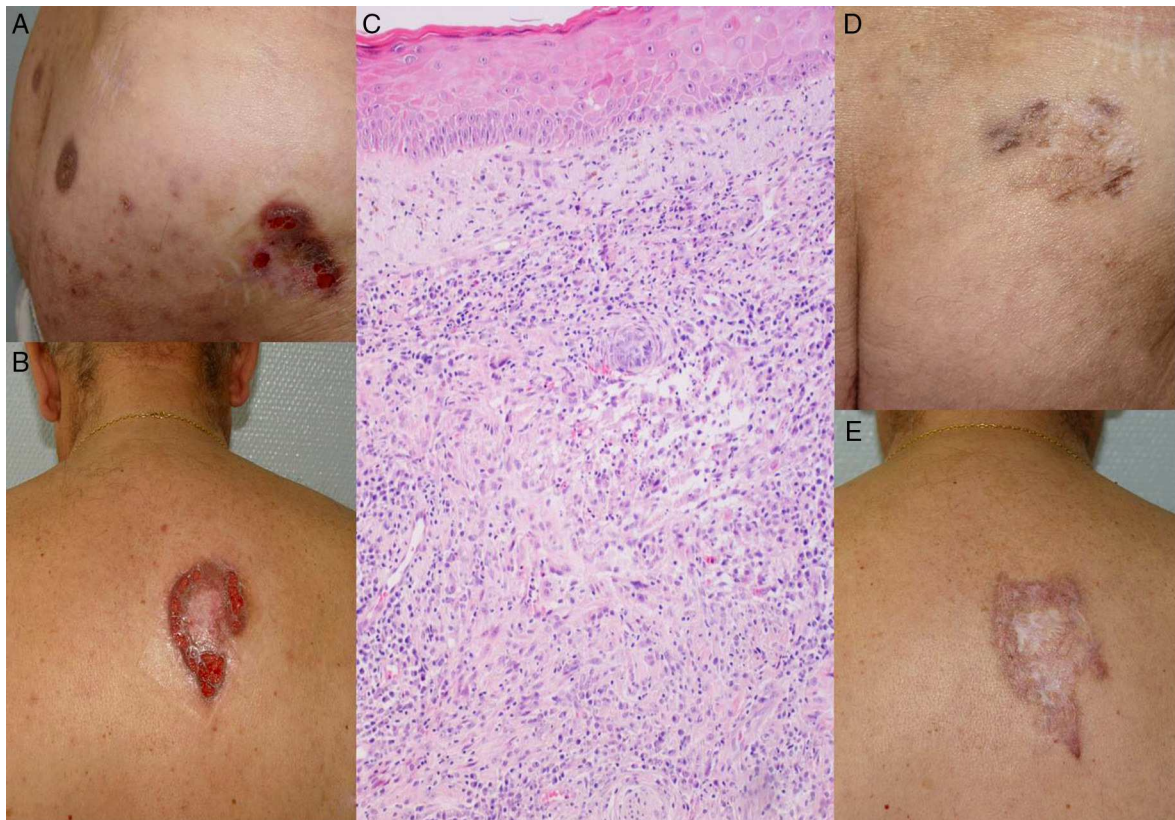


Figure 1 A, Plaques with ulcers on the buttocks. B, Horseshoe-shaped ulcer measuring 7 × 10 cm with an atrophic center and erythematous-violaceous borders on the upper back. C, Predominantly follicular inflammatory infiltrate with rupture of the follicular epithelium and granulomatous reaction with giant cells (hematoxylin-eosin, original magnification ×100). D, Residual scars on the buttocks. E, cribriform scars on the back.

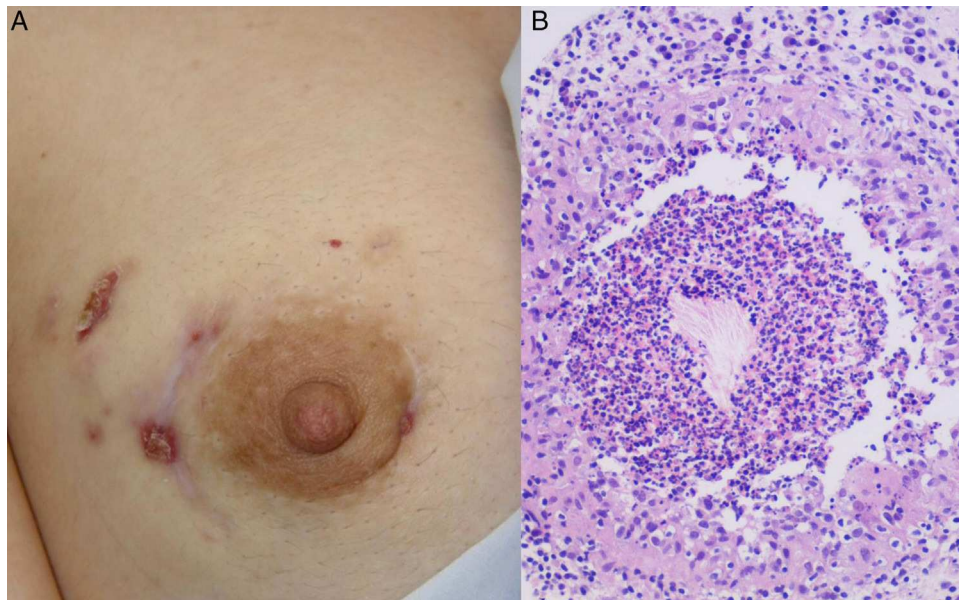


Figure 2 A, Erosions and scabs on the upper outer quadrant of the breast. B, 3-layer granuloma composed of a central zone with neutrophils, a surrounding layer with granulomatous inflammation, and an outer layer of plasma cells and eosinophils (hematoxylin-eosin, original magnification ×40).

Table 1 Differential Characteristics of Superficial Granulomatous Pyoderma and Pyoderma Gangrenosum.

| Type of Feature | Superficial Granulomatous Pyoderma | Pyoderma Gangrenosum |
|--------------------|---|---|
| Signs and symptoms | Superficial ulcer, clean base Painless Located on trunk Single lesion Less often associated with systemic disease Slow growth | Deep ulcer, necrotic center Painful Located on lower limbs Multiple lesions Associated with inflammatory bowel disease, rheumatoid arthritis, lymphoid tumors, etc. |
| Histology | Chronic granulomatous inflammatory infiltrate (eosinophils, plasma cells) Formation of fistulous tracts Foreign bodies such as hair and suture material may be found. | Acute diffuse inflammatory infiltrate (neutrophils) No fistulous tracts No foreign bodies |
| Treatment | Topical: corticosteroids, tacrolimus Oral: corticosteroids, tetracyclines, dapsone, ciclosporin, infliximab, intravenous immunoglobulins | Topical: corticosteroids, tacrolimus Oral: corticosteroids, ciclosporin, dapsone, clofazimine, minocycline, oral tacrolimus, mycophenolate mofetil, TNF, intravenous immunoglobulins |
| Prognosis | Good prognosis Frequent recurrence | Frequent relapses Often requires maintenance treatment |

tic histology, granulomatous inflammation is a consistent finding. The presence of eosinophils, plasma cells, and granulomas and the lack of involvement of the hypodermis help differentiate SGP from PG.⁶ Moreover, sinus tracts and foreign bodies such as hair, suture material, and vegetable matter are usually observed in SGP but not in PG.¹

In both PG and SGP, definitive diagnosis is by exclusion. Differential diagnosis should include mycobacterial and fungal infections, ulcerative sarcoidosis, foreign body granuloma, and halogenoderma.

The pathogenesis is unknown. Characteristics supporting the hypothesis that SGP has a different etiology to PG are the presence of foreign bodies and the inflammatory infiltrate composed of giant cells, plasma cells, and eosinophils, in addition to neutrophils. SGP therefore seems to be a local response of the skin to an as yet unidentified element or to a normal tissue that the disordered immune response identifies as foreign.¹

The treatment of SGP is different to that of PG.⁷ Spontaneous healing is not unusual, although recurrence is common. SGP located on the face is more refractory to treatment.⁸ As in PG, surgical removal of SGP is not recommended because of the risk of pathergy. Since SGP has a more indolent clinical course than PG, aggressive treatments are not usually required in principle (Table 1). The response to topical corticosteroids is usually good, though slow.⁹ Good responses to topical tacrolimus have also been reported.^{5,10} Our positive experience with tacrolimus in 2 patients leads us to think it could be considered a first-line treatment.

In conclusion, we have presented 2 cases of SGP, an uncommon diagnosis. We emphasize the favorable response to topical tacrolimus, although complete cure took several months to achieve.

References

1. Wilson-Jones E, Winkelmann RK. Superficial granulomatous pyoderma: a localized vegetative form of pyoderma gangrenosum. *J Am Acad Dermatol.* 1988;18:511–21.
2. Winkelmann RK, Wilson-Jones E, Gibson LE, Quimby SR. Histopathologic features of superficial granulomatous pyoderma. *J Dermatol.* 1989;16:127–32.
3. Akhras V, Sarkany R, Walsh S, Hyde N, Mariden A. Superficial granulomatous pyoderma treated preoperatively with infliximab. *Clin Exp Dermatol.* 2009;34:e183–5.
4. Calikoglu E. Superficial granulomatous pyoderma of the scrotum: an extremely rare cause of genital ulcer. *Acta Derm Venereol.* 2000;80:311–2.
5. Tao W, Tao Q, Yue-Hua L. Superficial granulomatous pyoderma accompanied with ulcerative colitis successfully treated with tacrolimus ointment. *J Dermatol.* 2011;38:1105–8.
6. Heredero M, Yus E, Gómez-Calcerada M, Sánchez M, Fernández R, Murillo E. Superficial granulomatous pyoderma. *Dermatology.* 1998;196:358–60.
7. Suárez-Pérez JA, Herrera-Acosta E, López-Navarro N, Vilchez-Márquez F, Prieto JD, Bosch RJ, et al. Pioderma gangrenoso: presentación de 15 casos y revisión de la literatura. *Actas Dermosifiliogr.* 2012;103:120–6.
8. Cheung ST, Zanetto U, Diaz C. Facial superficial granulomatous pyoderma treated with cyclosporine: not always a benign condition. *Acta Derm Venereol.* 2006;86:362–4.
9. Martínez González MC, del Pozo J, Martínez W, Vereá M, Carro E, Fonseca E. Pioderma granulomatoso superficial, resolución completa con corticoide tópico. *Piel.* 2008;23:4–6.
10. Miller J, Yentzer BA, Clark A, Jorizzo JL, Feldman SR. Pyoderma gangrenosum: a review and update on new therapies. *J Am Acad Dermatol.* 2012;62:646–54.

N. Ormaechea-Pérez,^{a,*} A. López-Pestaña,^a
C. Lobo-Morán,^b A. Tüneu-Valls^a

^a Servicio de Dermatología, Hospital Donostia, San Sebastián, Guipúzcoa, Spain

^b Servicio de Anatomía Patológica, Hospital Donostia, San Sebastián, Guipúzcoa, Spain

* Corresponding author.

E-mail address: nereaorma@hotmail.com

(N. Ormaechea-Pérez).

Adult Dermatomyositis Associated With Lipodystrophy[☆]

Dermatomiositis del adulto asociada a lipodistrofia

To the Editor:

Lipodystrophy is a rare disease characterized by loss of adipose tissue that can be associated with metabolic disorders and autoimmune diseases, primarily juvenile dermatomyositis. Lipodystrophy in association with adult-onset dermatomyositis, however, is very rare.

A 23-year-old woman consulted for erythema and bilateral palpebral edema that had appeared 1 year earlier and skin lesions on the dorsum of the interphalangeal joints of both hands. The patient reported that she had experienced muscle pain and weakness over the last 6 months, as well as joint pain in her hands, wrists, elbows, and knees. She also mentioned a progressive loss of fat in the facial region and arms over the last 2 months. The patient had no past history of interest and was not taking any medication. She also reported no family history of connective tissue disease.

In the physical examination, we observed a marked loss of adipose tissue in the face and arms; the trunk and lower limbs were unaffected by this loss (Fig. 1). There were atrophic erythematous lesions on the skin of the elbows and interphalangeal joints of the fingers (Fig. 2). We also detected the presence of periorbital erythema and periungual telangiectasia (Fig. 3). The patient had rigidity in the joints of the hands, with no signs of arthritis, and proximal muscle weakness (grade 4-5 according to the Medical Research Council scale).

The blood tests showed normal levels of creatine kinase and aldolase. The results of the antinuclear antibody test were positive, with a titer of 1:320 and a granular pattern. The C3 and C4 fractions of the complement were within normal limits. The anti-Jo1, anti-Ro, anti-La, anti-nRNP, anti-Sm, anti-ssDNA and anti-dsDNA antibody test results were negative. We detected no abnormalities in serum lipid or glucose levels.

Biopsy of the hand lesions showed lichenoid dermatitis with hydropic degeneration of the basement membrane and upper dermal edema. There were no immunoglobulin (Ig) G, IgA, fibrinogen, or complement deposits in the direct immunofluorescence assay. An electrophysiological study showed no abnormalities. We therefore performed a muscle biopsy, which revealed muscle fiber necrosis and a lymphoplasmacytic inflammatory infiltrate. Magnetic resonance

imaging showed thickening of the perimuscular fascia of the arms, shoulders, buttocks, and thighs. Based on the above findings, we arrived at the diagnosis of dermatomyositis. Given this diagnosis in an adult, we followed up with positron emission tomography, which ruled out underlying neoplastic disease at the time of the visit and 2 years later.

Lipodystrophy is a rare disease characterized by the loss of subcutaneous adipose tissue. It is classified as inherited or acquired and, depending on its location, as generalized, partial (relatively extensive but not generalized), or localized.¹ When lipodystrophy is generalized or partial, it is often associated with metabolic disorders, such as insulin resistance and hypertriglyceridemia.¹

Acquired lipodystrophy has been associated with infections, antiretroviral therapy for the treatment of human immunodeficiency virus infection and with autoimmune

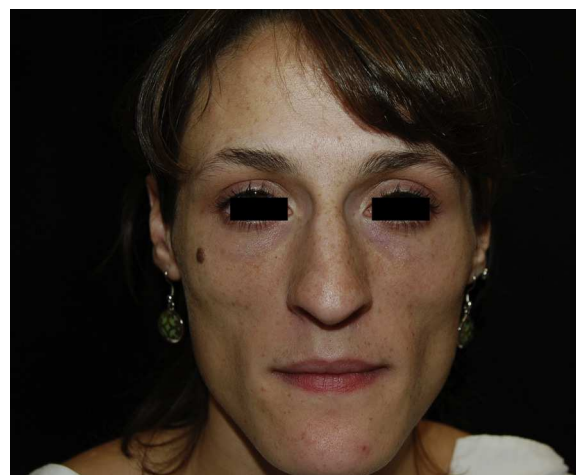

Figure 1 Palpebral erythema and loss of fatty tissue in both cheeks.

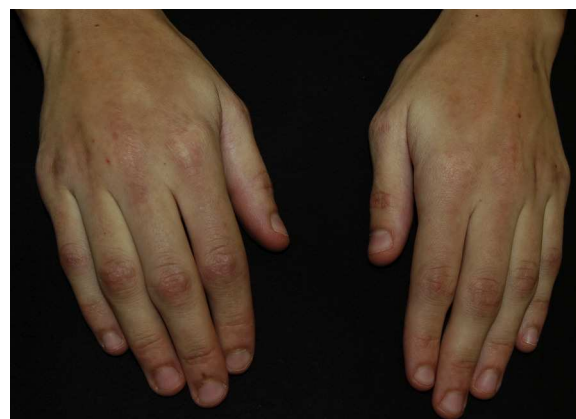

Figure 2 Atrophic erythematous lesions in the interphalangeal joints of the fingers.

[☆] Please cite this article as: Pretel M, et al. Dermatomiositis del adulto asociada a lipodistrofia. *Actas Dermosifiliogr.* 2013;104:724–5.