

## CASE FOR DIAGNOSIS

### Nodular Lesion on a Woman's Earlobe<sup>☆</sup>

#### Lesión nodular en el lóbulo de la oreja de una paciente

#### Medical History

A 32-year-old woman sought care for a fast-growing nodular lesion of 2 months' duration on her right earlobe. The patient had no relevant medical history and denied previous injury to the area.

#### Physical Examination

Physical examination showed a well-circumscribed, violaceous erythematous nodular lesion with a diameter of 8 mm on the right earlobe (Fig. 1)

#### Histopathology

Histologic examination following complete surgical excision showed spindle cells arranged in a storiform pattern

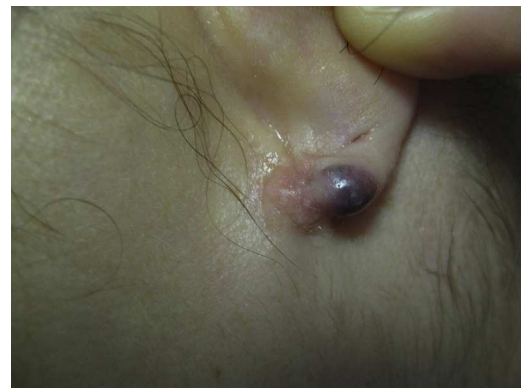

Figure 1

with hemosiderin-laden Touton-type multinucleated giant cells surrounding cleft-like vascular spaces without epithelial lining (Fig. 2). No cellular atypia or mitotic figures were observed.

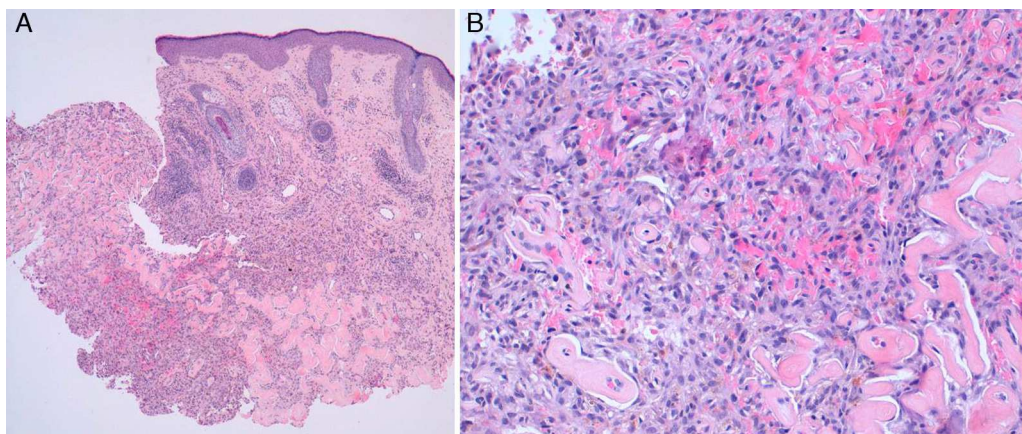


Figure 2 A, Hematoxylin-eosin, original magnification  $\times 4$ . B, Hematoxylin-eosin, original magnification  $\times 20$ .

<sup>☆</sup> Please cite this article as: López V, Giner F. Lesión nodular en el lóbulo de la oreja de una paciente. Actas Dermosifiliogr. 2013;104:437-8.

What Is Your Diagnosis?

## Diagnosis

Aneurysmal dermatofibroma.

## Clinical Course and Treatment

The patient remained asymptomatic after surgical removal of the lesion, with no signs of recurrence after 2 years of follow-up.

## Comment

Dermatofibroma is a very common benign tumor that can be of fibroblastic or histiocytic origin. There are several histologic variants depending on the cells that make up the tumor. Diagnosis is generally easy, but atypical forms or variants can sometimes present challenges.

Aneurysmal dermatofibroma is a rare variant that accounts for less than 2% of all these tumors.<sup>1,2</sup> This tumor is also known as aneurysmal benign fibrous histiocytoma, a term coined by Santa Cruz and Kyriakos<sup>1</sup> to describe nodular lesions with a smooth surface located primarily on the extremities and the trunk of middle-aged patients, and women in particular.<sup>3</sup> These lesions can, however, occur in any location and in patients across a wide age range (12–92 years). To our knowledge, ours is the first report of an aneurysmal dermatofibroma on an earlobe. The aneurysmal lesions tend to measure between 0.5 and 4 cm and are generally larger than typical dermatofibromas. They vary in color, presenting as red, red-violaceous, blue, black, or yellow, and can grow quickly and cause pain due to intralesional bleeding.<sup>2</sup> Very occasionally, previous injury to the site has been reported.

Histologic features include the presence of multiple vascular spaces devoid of endothelial lining, with an interspersed infiltrate composed of histiocytes, fibroblasts, multinucleated giant cells, and abundant hemosiderin deposits.<sup>3</sup> Hemosiderotic dermatofibroma is considered to be a precursor of aneurysmal dermatofibroma in which extravasation of blood from the capillaries of the lesion leads to the formation of hemosiderin, which is then phagocytosed by dermal histiocytes and tumor cells. If the extravasation continues, histology will show the large spaces typically seen in aneurysmal dermatofibroma.

Considering the clinical features of these lesions, it is surprising that a diagnosis of aneurysmal dermatofibroma is rarely considered initially. It is possible to confuse these tumors with benign angiomatous lesions or malignant tumors with similar clinical manifestations, as well as with spindle cell melanocytic tumors. The differential diagnosis should therefore include cutaneous melanoma, Kaposi sarcoma, spindle cell hemangioendothelioma, angiomatoid malignant fibrous histiocytoma, angiosarcoma, hemangiomas, adnexal tumors, and cysts.

Two recent reports described a set of dermoscopic features that might aid in the diagnosis of aneurysmal

dermatofibroma.<sup>4,5</sup> In a series of 6 patients, Zaballos et al.<sup>4</sup> described the presence of pigmented, homogeneous areas ranging in color from a bluish gray to a reddish brown, with fine white linear structures corresponding to fibrosis, a delicate pigment network, and vascular structures including dotted vessels, comma vessels, and/or irregular vessels.

The treatment of choice for aneurysmal dermatofibroma is surgery, but it is important to bear in mind that, compared with other variants, the aneurysmal form of this tumor has a stronger tendency to recur locally (20% of cases) and can also, albeit very rarely, metastasize after incomplete excision. Several factors have been associated with an increased risk of metastasis; these include lesion size, the presence of tumor necrosis, a history of local recurrence, and certain histologic features such as pronounced cellular pleomorphism, a high mitotic index, and aneurysmal changes.<sup>6</sup>

We have presented the case of a rare variant of dermatofibroma on the earlobe of a female patient. Considering the clinical characteristics of this lesion, we believe that aneurysmal dermatofibroma should be considered in the differential diagnosis of violaceous erythematous lesions of the ear.

## Conflicts of Interest

The authors declare that they have no conflicts of interest.

## References

1. Santa Cruz DJ, Kyriakos M. Aneurysmal ("angiomatoid") fibrous histiocytoma of the skin. *Cancer*. 1981;47:2053–61.
2. McKenna D, Kavanagh G, McLaren K, Tidman M. Aneurysmal fibrous histiocytoma: an unusual variant of cutaneous fibrous histiocytoma. *J Eur Acad Dermatol Venereol*. 1999;12:238–40.
3. Calonje E, Fletcher CD. Aneurysmal benign fibrous histiocytoma: clinicopathological analysis of 40 cases of a tumour frequently misdiagnosed as a vascular neoplasm. *Histopathology*. 1995;26:323–31.
4. Zaballos P, Llambrich A, Ara M, Olazaran Z, Malveyh J, Puig S. Dermoscopic findings of haemosiderotic and aneurysmal dermatofibroma: report of six patients. *Br J Dermatol*. 2006;154:244–50.
5. García-Millán C, Martín-González M, González-García C, Jaén P. Lesión pigmentada de dos años de evolución. *Actas Dermosifiliogr*. 2008;99:565–6.
6. Guillou L, Gebhard S, Salmeron M and Coindre J. Metastasizing fibrous histiocytoma of the skin: A clinicopathologic and immunohistochemical analysis of three cases. *Mod Pathol*. 200; 13:654.

V. López,\* F. Giner

*Servicios de Dermatología y Anatomía Patológica, Hospital Quirón y Hospital Clínico Universitario de Valencia, Spain*

\*Corresponding author.

*E-mail address: veronica.17@live.com (V. López).*