

Angiolymphoid Hyperplasia With Eosinophilia: Analysis of 7 Cases[☆]

Hiperplasia angiolinfoide con eosinofilia. Revisión de 7 casos

To the Editor:

Angiolymphoid hyperplasia with eosinophilia (ALHE), also known as epithelioid hemangioma, is a chronic, benign vascular proliferation for which no cases of malignant transformation have been reported to date. Spontaneous resolution has been described in some patients,¹ particularly in those with small lesions. ALHE is characterized by a high rate of recurrence (approximately 30%), regardless of treatment modality.^{2,3}

We describe the clinical and pathologic characteristics of 7 cases of ALHE diagnosed in our hospital between 2005 and 2011 (Table 1). Six of the patients were women; 5 of these were in their 40s and 1 was aged 75 years when the disease was diagnosed. The seventh patient was a 43-year-old man. The predominant clinical presentation was erythematous papules and plaques (Fig. 1). Subcutaneous masses were observed in 2 cases. In all 7 patients, the lesions were located on the head and neck, specifically in retroauricular areas, on the helix of the ear, on the nose, on the temple, in the posterior cervical region, and in the frontal region (2 cases). The most common treatment was surgical excision (5 cases). This produced a satisfactory clinical outcome, although recurrence was observed in 4 cases. Recurrent lesions were treated with cryotherapy, intralesional corticosteroid injections, and electrocoagulation, resulting in complete resolution in 1 case; the remaining lesions remained stable. Spontaneous involution following biopsy was observed in 1 patient with a single papular lesion on the nasal dorsum.

None of the patients had peripheral eosinophilia, palpable lymph nodes, or a history of trauma in the area of the

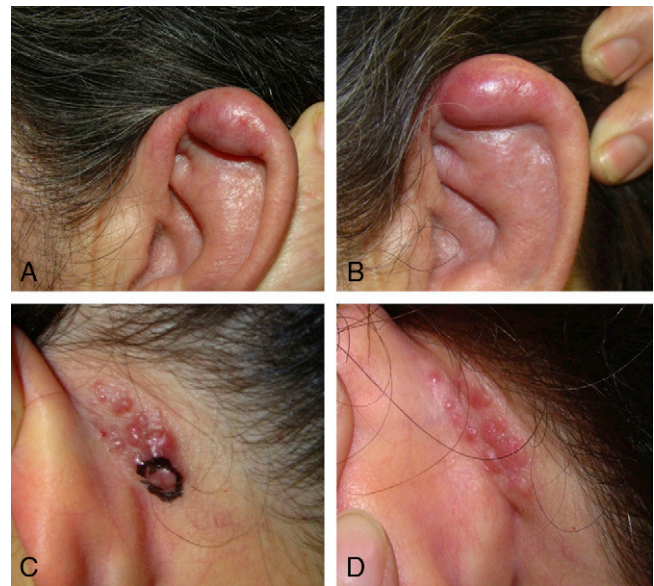

Figure 1 A, Angiolymphoid hyperplasia lesion before treatment. B, Angiolymphoid hyperplasia lesion after treatment with intralesional corticosteroids. C, Original retroauricular angiolymphoid hyperplasia lesion. D, Angiolymphoid hyperplasia lesion that recurred after surgery.

lesions. Dermoscopic evaluation of 1 of the lesions showed a lacunar pattern similar to the characteristic pattern seen in hemangiomas (Fig. 2).

ALHE is considered a rare entity, although it is also believed to be underdiagnosed because of its diverse clinical presentations. Histology, therefore, has a key diagnostic role in this disease. Characteristic findings include prominent epithelioid-like endothelial cells lining the vascular lumen and surrounded by a mixed, predominantly eosinophilic, inflammatory infiltrate (Fig. 2).^{4,5}

The differential diagnosis is very wide, with Kimura disease generating the most controversy.⁶ Until recently, ALHE

Table 1 Review of 7 Cases of Angiolymphoid Hyperplasia With Eosinophilia Treated at our Hospital Between 2005 and 2011.

	Sex	Age, y	Clinical Presentation	Lesion Site	Treatment	Recurrence
1.	F	35	Reddish papules	Temple	Surgery Cryotherapy Electrocoagulation	Yes
2.	F	36	Reddish papules	Retroauricular area	Surgery	Yes
3.	F	75	Violaceous tumor	Ear	Corticosteroids	Yes
4.	F	39	Reddish tumor	Neck	Surgery	No
5.	M	43	Subcutaneous mass	Forehead	Surgery Corticosteroids	No
6.	F	41	Subcutaneous mass	Forehead	Surgery Corticosteroids	Yes
7.	F	56	Reddish papule	Nose	Spontaneous involution	No

Abbreviations: F, female; M, male.

[☆] Please cite this article as: Padilla-España L, et al. Hiperplasia angiolinfoide con eosinofilia. Revisión de 7 casos. *Actas Dermosifiliogr*. 2013;104:353–5.

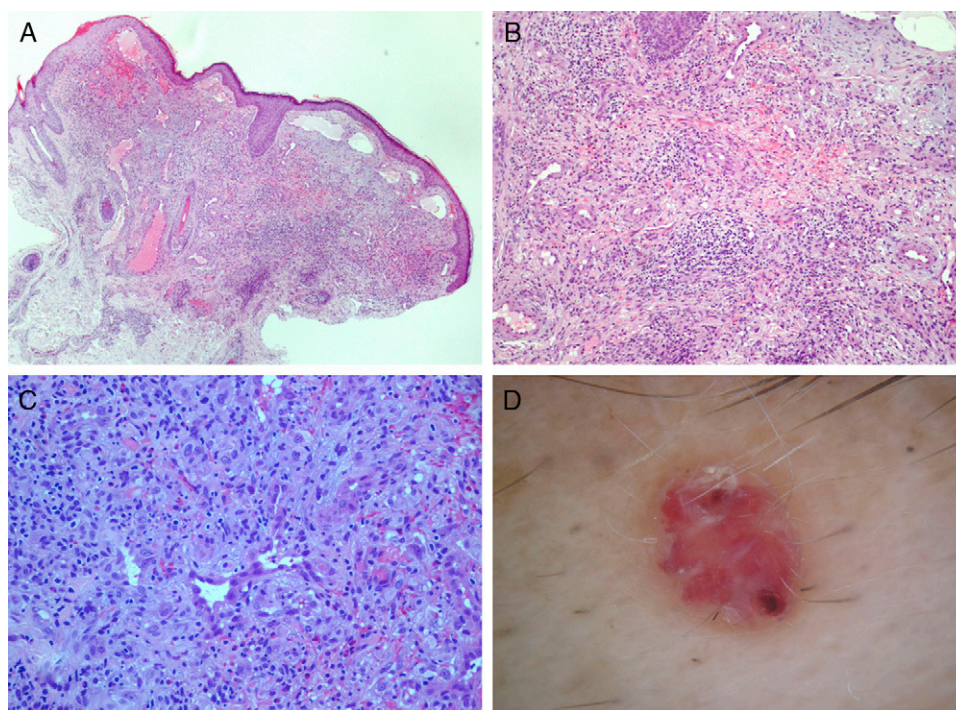


Figure 2 Histologic features of angiolymphoid hyperplasia. A, Hematoxylin-eosin, original magnification $\times 40$. B, Hematoxylin-eosin, original magnification $\times 100$. C, Hematoxylin-eosin, original magnification $\times 200$. D, Dermoscopic image of angiolymphoid hyperplasia.

and Kimura disease were considered to represent opposite ends of the same entity, but they are now considered to be separate diseases due to their clinical and histologic differences. Considering the large number of disorders in the differential diagnosis, biopsy of lesions is a key diagnostic tool in ALHE. There are many treatment options for ALHE, the most common of which are surgical excision, cryotherapy, and intralesional corticosteroids. Cryotherapy was used to treat papular lesions on the face of 1 of our patients, with favorable clinical and cosmetic results. Considering that it is fast and simple, this treatment modality is a viable option for superficial lesions. Electrocoagulation is also useful for superficial lesions, particularly when they are small. We achieved control of a lesion located on the edge of the helix of an elderly patient with intralesional corticosteroids, although the lesion did not resolve completely. The patient refused to undergo more invasive treatment. Surgical excision is perhaps the most viable therapeutic option for subcutaneous masses in ALHE.⁷

Less common treatments described in the literature include laser therapy (considered the first-line alternative for superficial lesions), pentoxifylline, indomethacin, retinoids, chemotherapeutic agents (bleomycin, vinblastine, fluorouracil), levamisole, and interferon.⁸

As seen, many treatment options exist for ALHE, but there is no consensus on the treatment of choice due to the shortage of studies. Considering that ALHE is a benign condition that follows a chronic, recurrent course, perhaps the best option in the majority of cases is a conservative, watch-and-wait approach.

The largest series of ALHE cases identified in our review of the literature was one involving 116 patients (with a pre-

dominance of men) reported in 1985.⁹ In Spain, the largest series published to date involved 5² and 3¹⁰ patients. In this second study, good results were achieved with vascular laser therapy.

With 7 cases, ours is the largest series of ALHE to be published in Spain to date. We have performed a review of the literature on this entity and described the first—to our knowledge—dermoscopic analysis of an ALHE lesion.

References

1. Del Pozo J, Cuevas J, Fonseca E. Hiperplasia angiolinfoide con eosinofilia. *Piel*. 2003;18:298–305.
2. Vargas Castrillón J, Perez-Seoane Orduña C, Zarco Olivo C, Iglesias Diez L. Hiperplasia angiolinfoide con eosinofilia: estudio clinicopatológico de 5 casos. *Actas Dermosifiliogr*. 1989;80:401–4.
3. Milena A, Londoño A, Restrepo R. Hiperplasia angiolinfoide con eosinofilia: manifestación clínica atípica. *Rev Asoc Colomb Dermatol*. 2011;19:163–6.
4. Pancorbo J, Sánchez L, Ingar B, Regis A, Sialer MC. Hiperplasia angiolinfoide con eosinofilia. *Dermatol Perú*. 2003;13:57–60.
5. Segura J, Solís E, Gonzalez Serrano T. Hemangioma epitelioido en localización profunda y extrafacial. A propósito de dos casos y revisión de la literatura. *Rev Esp Patol*. 2008;41:138–41.
6. Wei-Sheng C, Anjula T, Chee-Leok G. Kimura's disease and angiolymphoid hyperplasia with eosinophilia: Two disease entities in the same patient. Case report and review of the literature. *Int J Dermatol*. 2006;45:139–45.
7. Martínez de Salinas A, Roncero Riesco M, Escalonilla García-Patos P, Martín Pascual A. Nódulo asintomático en la frente. *Actas Dermosifiliogr*. 2006;97:543–5.

8. Redondo P, Del Olmo J, Idoate M. Angiolymphoid hyperplasia with eosinophilia successfully treated with imiquimod. *Br J Dermatol.* 2004;151:1110–1.
9. Olsen TG, Helwig EB. Angiolymphoid hyperplasia with eosinophilia: clinicopathologic study of 116 patients. *J Am Acad Dermatol.* 1985;12:781–96.
10. Alcántara-González J, Boixeda P, Truchuelo Diez T, Perez García B, Jaen Olasolo P. Angiolymphoid hyperplasia with eosinophilia treated with vascular laser. *Laser Med Sci.* 2011;26: 285–90.

L. Padilla-España,* T. Fernández-Morano, J. del Boz, R. Fúnez-Liébana

Servicio de Dermatología y Anatomía Patológica, Hospital Costa del Sol, Marbella, Málaga, Spain

*Corresponding author.

E-mail address: eplaura85@hotmail.com
(L. Padilla-España).

Extramammary Paget Disease with Frontotemporal Involvement: A Case Report and Review of the Literature[☆]

Enfermedad de Paget extramamaria con afectación de la región fronto-temporal. Presentación de un caso y revisión de la bibliografía

To the Editor:

Extramammary Paget disease (EMPD), first described by Crocker¹ in 1889, is a form of intraepidermal adenocarcinoma that generally occurs in areas with a high density of apocrine glands. It presents as a scaly, erythematous lesion simulating inflammatory conditions, tumors, and infections. Isolated cases that occur in locations where there are usually no apocrine glands are called ectopic EMPD.² We report a case of EMPD in the right frontotemporal region, which is only the third case of EMPD affecting the face that has been reported in the literature (Table 1).^{2,3}

A 64-year-old woman presented with a plaque measuring 5 cm in the right frontotemporal region that extended into the preauricular region; the lesion had appeared 3 years earlier. The plaque had an erythematous, slightly scaly center and slightly pigmented borders (Fig. 1A). A diagnosis of intraepidermal squamous cell carcinoma or seborrheic dermatitis was made and treatment with corticosteroids resulted in a slight improvement.

Histologic study of 2 biopsies, 1 from the center and 1 from the edge of the lesion, revealed the occupation of the epidermis by a population of large cells with clear cytoplasm and atypical nuclei, arranged singly or in nests and accompanied by little melanin pigment. These cells had spread to the adnexa but there was no dermal infiltration (Fig. 2 A and B). The atypical cells occupying the epidermis were positive for cytokeratin 7 (Fig. 2G) and cytokeratin CAM5.2, but these markers were not expressed in the surrounding epidermis. The nuclei tested positive for estrogen receptors (Fig. 2C). Her2 membrane expression was intense and continuous (Fig. 2D). Other positive markers were carcinoembryonic antigen (Fig. 2E), gross cystic disease fluid

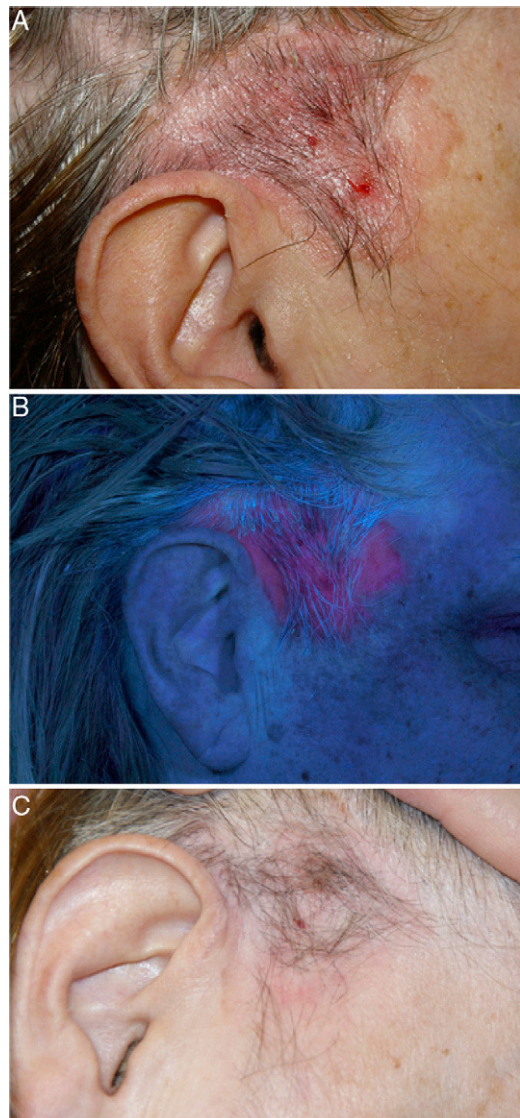


Figure 1 A, Erythematous plaque measuring 5 cm located in the right temporal region and extending towards preauricular hairless skin, with a periphery marked by linear pigmentation. B, Plaque displaying intense red fluorescence after a 3-hour incubation period with methyl aminolevulinate. C, Complete remission 2 months after the second photodynamic therapy session.

[☆] Please cite this article as: Córdoba A, et al. Enfermedad de Paget extramamaria con afectación de la región fronto-temporal. Presentación de un caso y revisión de la bibliografía. *Actas Dermosifiliogr.* 2013;104:355–7.