



ACTAS Derma-Sifiliográficas

Full English text available at
www.elsevier.es/ad



CASE AND RESEARCH LETTERS

Response to Photodynamic Therapy for Pustular Dermatitis of the Scalp and Hypertrophic Actinic Keratosis[☆]

Respuesta a terapia fotodinámica en paciente con dermatosis pustulosa del cuero cabelludo y queratosis actínicas hipertróficas

To the Editor:

Erosive pustular dermatosis of the scalp is a rare inflammatory skin disease that mainly affects older patients and is characterized by the presence of sterile pustules and scabs. Recently, several authors have reported the usefulness of photodynamic therapy in the treatment of this condition.¹

We present the case of a 79-year-old man with skin phototype III and actinic keratosis of the face and scalp, occasionally treated with cryotherapy, after which the patient would complain of painful erosions in the treated area. On one of his check-up visits he had an outbreak of pustules and scabs that mainly affected the posterior part of the parietal region. The pustules had an erythematous base, and painful erosions and scabs were also visible. Biopsy revealed areas of fibrosis, a predominantly perifollicular neutrophil infiltrate, and areas of scarring. The diagnosis was erosive pustular dermatosis of the scalp, which responded favorably to topical treatment with fusidic acid plus betamethasone cream and healed with scarring alopecia. Thereafter, actinic keratoses in this patient were successfully treated with topical imiquimod to prevent outbreaks of pustulosis. During follow-up, however, he presented with hypertrophic actinic keratoses in the occipital region and numerous pustules that coalesced into lakes of pus (Fig. 1). These actinic keratoses did not respond to imiquimod and the erosive pustular dermatosis of the scalp worsened with the use of this agent. It was then decided to try treatment with photodynamic therapy (PDT). At the first session, curettage of the most hypertrophic actinic keratoses was performed and this was followed by an application of Metvix[®] (160 mg/g methyl aminolevulinic acid hydrochloride cream; manufac-

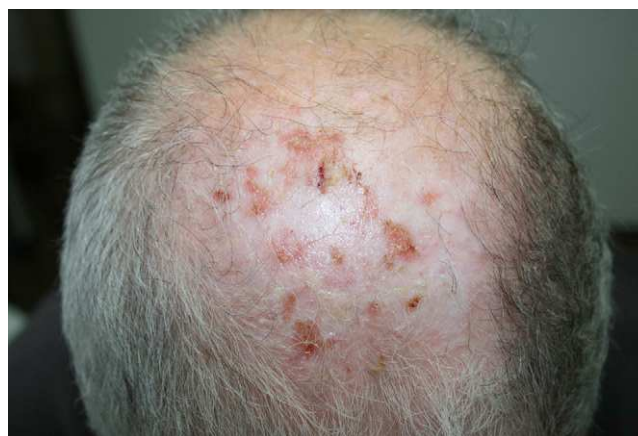

Figure 1 Active lesions of erosive pustular dermatosis of the scalp together with actinic keratoses.

tured by Penn Pharmaceutical Services Ltd, distributed by Galderma) under occlusion for 3 hours. Wood light showed intense uptake in the area (Fig. 2), which was then infiltrated with local anesthetic. Irradiation was by red light (Aktilite CL128, Photocure ASA, Oslo, Norway) at a wavelength of 630 nm, with a fluence of 37 J/cm². A good response was observed after a week but several actinic keratoses and pustules still remained. A second session 3 weeks later cleared the actinic keratoses and the erosive pustular dermatosis of the scalp was rendered inactive (Fig. 3).

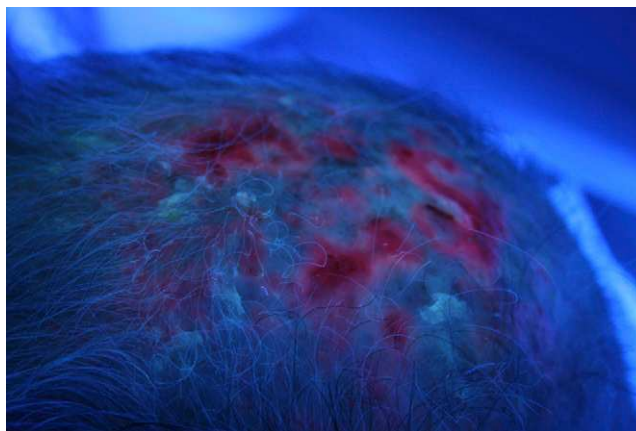


Figure 2 Intense uptake by actinic keratoses as well as by the lesions of erosive pustular dermatosis of the scalp.

[☆] Please cite this article as: Monteagudo AF, et al. Respuesta a terapia fotodinámica en paciente con dermatosis pustulosa del cuero cabelludo y queratosis actínicas hipertróficas. Actas Dermosifiliogr. 2013;104:351–2.

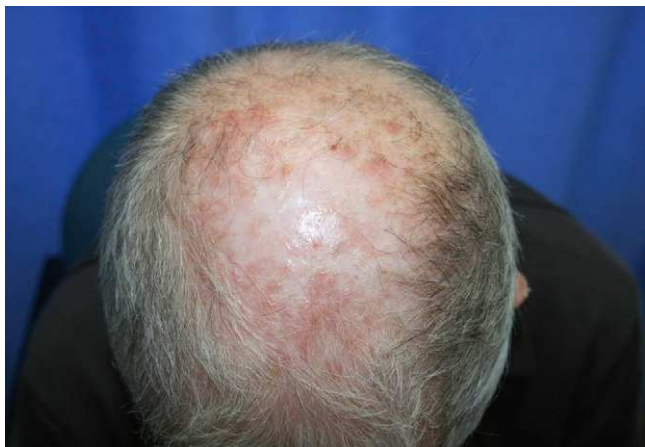

Figure 3 Note the improvement after 2 sessions of PDT.

Six months later, the improvement in the treated area was maintained and the patient is currently awaiting a further session on the occipital region to treat new actinic keratoses.

Erosive pustular dermatoses are rare inflammatory skin diseases of unknown origin that typically arise either on the legs or on the scalp. Erosive pustular dermatosis of the scalp mainly affects older patients. It is characterized by confluent sterile pustules, erosions, and scabs on the scalp that heal with scarring alopecia. Factors such as local trauma, cryotherapy, and radiotherapy¹ can trigger or worsen this condition. The differential diagnosis includes bacterial folliculitis, inflammatory tinea, blistering diseases such as cicatricial pemphigoid, dissecting cellulitis, and pyoderma gangrenosum.^{1,2} Treatment is complex and the disease tends to recur. Medium- to high-potency topical corticosteroids have been used successfully, sometimes in conjunction with a topical antibiotic. Topical tacrolimus can also be effective³ and prevents the adverse effects of long-term topical corticosteroid therapy. Other treatments include oral corticosteroids, dapson, oral retinoids (isotretinoin), and topical calcipotriol. In our patient, treatment of actinic keratoses with cryotherapy probably worsened the erosive pustular dermatosis of the scalp, and cryotherapy was therefore avoided after this second diagnosis was made.

PDT is a well-established treatment for actinic keratoses and other premalignant or malignant conditions.⁴ It is particularly useful for the treatment of actinic keratoses in patients with multiple lesions or frequent recurrences. There is evidence of the value of PDT in erosive pustular dermatosis of the scalp,^{1,2} attributed to its immunomodulatory effect on inflammatory cells.⁵ Meyer et al¹ reported

the case of a 75-year-old woman with erosive pustular dermatosis of the scalp successfully treated with PDT. Recently, Eleftheriou et al² published a case similar to ours of a 72-year-old man with actinic keratoses and underlying erosive pustular dermatosis of the scalp. Two sessions of PDT separated by 12 weeks led to resolution of the lesions. However, Guarneri et al⁶ described the case of a 93-year-old woman who had an outbreak of erosive pustular dermatosis of the scalp after 2 sessions of PDT for actinic keratoses in the same area. Their patient received a higher fluence than ours (75 J/cm² compared to 37 J/cm², respectively), and this may have resulted in the appearance of erosive pustular dermatosis of the scalp.

We report a patient with erosive pustular dermatosis of the scalp and multiple hypertrophic actinic keratoses on the scalp; both conditions responded to treatment with PDT. Two sessions of PDT led to considerable improvement, which was maintained at the 6-month follow-up. Experience of using PDT in inflammatory dermatoses like erosive pustular dermatosis of the scalp is limited, but our case provides more evidence that it can be a good therapeutic option for a disorder that is difficult to manage.

References

1. Meyer T, López-Navarro N, Herrera-Acosta E, Jose A, Herrera E. Erosive pustular dermatosis of the scalp: a successful treatment with photodynamic therapy. *Ann Dermatol.* 2010;22:232–4.
2. Eleftheriou LI, McIntee TJ, Stratman EJ. Aminolevulinic acid photodynamic therapy in the treatment of erosive pustular dermatosis of the scalp. *Arch Dermatol.* 2011;147:1368–70.
3. Cenkowsky MJ, Silver S. Topical tacrolimus in the treatment of erosive pustular dermatosis of the scalp. *J Cutan Med Surg.* 2007;11:222–5.
4. Ballester I, Belinchón I, Guijarro J, Oltra F, Toledo F, Cuesta L. Photodynamic therapy of vulvar intraepithelial neoplasia using methyl aminolevulinate. *J Dermatolog Treat.* 2012;23:156–8.
5. Orringer JS, Hammerberg C, Hamilton T, Johnson TM, Kang S, Sachs DL, et al. Molecular effects of photodynamic therapy for photoaging. *Arch Dermatol.* 2008;144:1296–302.
6. Guarneri C, Vaccaro M. Erosive pustular dermatosis of the scalp following topical methylaminolevulinate photodynamic therapy. *J Am Acad Dermatol.* 2009;60:521–2.

A.F. Monteagudo,* I. Belinchón, N. Latorre, J.F. Silvestre
Servicio de Dermatología, Hospital General Universitario de Alicante, Alicante, Spain

* Corresponding author.

E-mail address: almudenamonteagudo@gmail.com
 (A.F. Monteagudo).