

ACTAS Derma-Sifiliográficas

Full English text available at
www.elsevier.es/ad



CASE AND RESEARCH LETTERS

Leukocytoclastic Vasculitis Related to Cocaine Use[☆]

Vasculitis leucocitoclástica asociada a consumo de cocaína

To the Editor:

Vasculitis is a rare complication of cocaine abuse and poses significant diagnostic and management problems. We report a case of this type of vasculitis.

A 45-year-old woman with a history of cocaine abuse from age 23 years consulted because of a 20-day history of a widespread skin condition that affected practically the whole body surface, was accompanied by fever and intense pain, and prevented her from walking. At the time of admission, the patient was underweight, had facies dolorosa, normal vital signs, and dry mucosas. Physical examination revealed multiple ulcers of varying shape and size, with a purulent, foul-smelling exudate; several were covered by necrotic slough (Fig. 1).

Additional tests, based on a suspected clinical diagnosis of systemic vasculitis, gave the following results: white blood cell count, 12 500/ μ L; hemoglobin, 9.8 g/dL; reactive thrombocytosis, 658 000/ μ L; hypoalbuminemia, 2.0 g/dL; alanine aminotransferase, 68 U/L; aspartate aminotransferase, 62 U/L; γ -glutamyltransferase, 181 U/L; alkaline phosphatase, 326 U/L; creatinine clearance, 88.3 mL/min with renal function of 86.6%; C-reactive protein, 1.40 mg/dL; a negative Venereal Disease Research Laboratory test, negative rheumatoid factor; antineutrophil cytoplasmic antibodies (c-ANCA), 1:40; perinuclear (p) ANCA, 1:2560 U/mL; p-ANCA antilactoferrin, 48.2 U/mL; culture of the skin exudate, *Escherichia coli*; positive total hepatitis A virus antibody; negative anti-hepatitis B and anti-hepatitis C virus antibodies; negative human immunodeficiency virus (enzyme-linked immunosorbent assay). Skin biopsy revealed leukocytoclastic vasculitis (Fig. 2).

The otorhinolaryngology department reported perforation of the cartilaginous portion of the nasal septum, confirmed by computed tomography, but biopsy of the nasal mucosa only revealed chronic inflammation. The

psychiatry department diagnosed the patient as having a mixed personality disorder and treatment was initiated with amitriptyline, perphenazine, and diazepam. The general surgery department then performed surgical debridement of the ulcers and escharectomy. The patient was treated with antibiotics (trimethoprim-sulfamethoxazole, 160/800 mg, administered intravenously every 12 hours for 14 days), analgesics, and thalidomide (100 mg/d); prednisone (0.5 mg/kg) was added after achieving control of the infection. The response was satisfactory and the patient was discharged

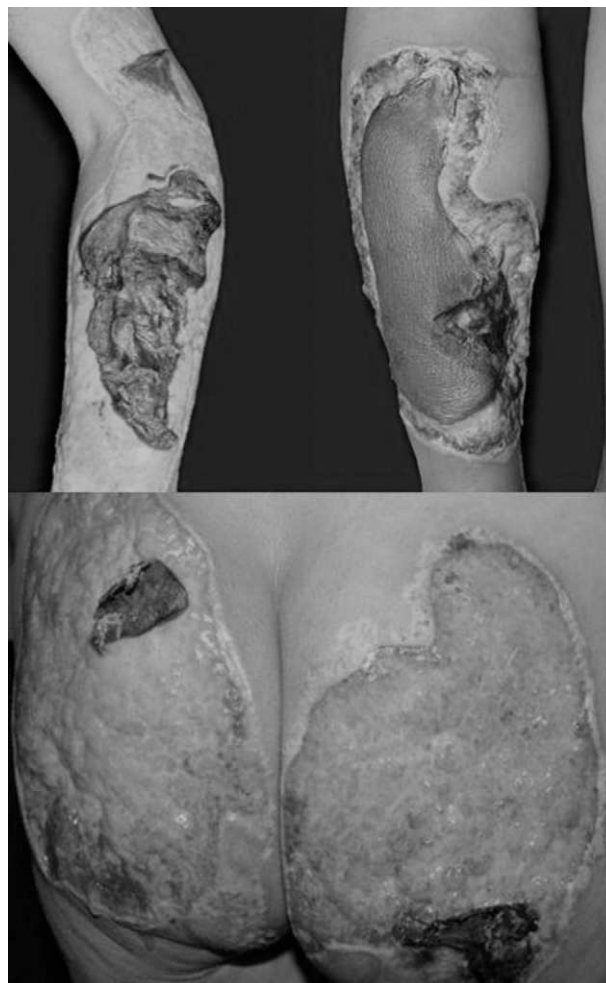

Figure 1 Photograph at presentation. Ulcers with a purulent exudate and covered with necrotic slough.

[☆] Please cite this article as: Salas-Espíndola Y, et al. Vasculitis leucocitoclástica asociada a consumo de cocaína. Actas Dermosifiliogr. 2011;102:825-826.

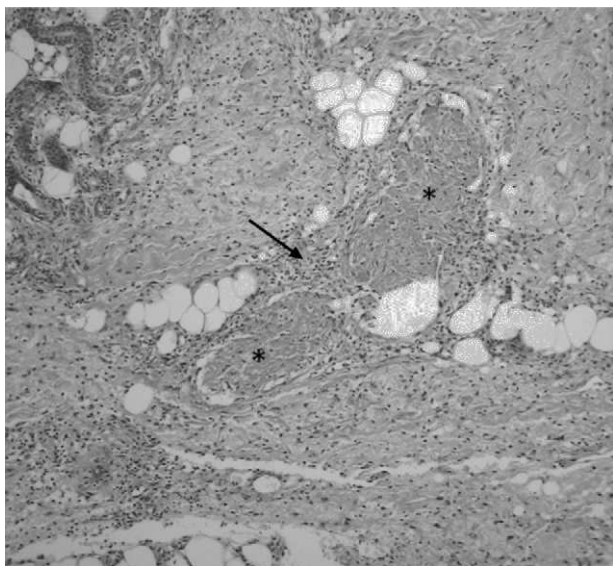


Figure 2 Histopathology: mainly neutrophilic, abundant perivascular inflammatory infiltrate that infiltrates and partially destroys blood vessel walls; prominent leukocytoclasia and multiple foci of vascular thrombosis (periodic acid-Schiff, original magnification x40).

after 37 days, with the presence of granulation tissue and partial reepithelialization of the ulcerated areas. Diagnosis at discharge was cocaine-related vasculitis based on the clinical findings, histopathological study, the positivity of serum markers (p-ANCA and lactoferrin), a history of long-term consumption of the drug, and the exclusion of other causes.

Follow-up confirmed the reepithelialization of most lesions, which developed into hypertrophic scars and retractile keloids, currently awaiting surgical treatment by the plastic surgery department (Fig. 3).

Cocaine consumption is increasing worldwide, leading to a rise in related diseases. The spectrum of skin lesions caused by cocaine is broad and has been related to digital vasospasm, bullous diseases, small- and medium-vessel vasculitis, which present as purpura, necrotizing vasculitis, urticarial vasculitis, ulcers, livedo reticularis,

Buerger disease, pyoderma gangrenosum, and gangrene.^{1,2} Some authors hold levamisole, an adulterant found in the end product, responsible for the damage in cases involving microvascular thrombosis and neutropenia.³ There are reports of cocaine consumption in patients with Wegener granulomatosis,⁴ and since both may cause midline destructive lesions of the face, distinguishing between them can be difficult. In our patient, the absence of granulomatous vasculitis of the respiratory tract, renal involvement, and high titers of c-ANCA enabled us to rule out this possibility.

The study protocol for cocaine-related vasculitis is identical to drug-related vasculitis and includes a blood count, erythrocyte sedimentation rate, routine biochemistry, chest x-ray, urinalysis, liver function tests, and fecal occult blood. More specific studies should subsequently be considered, such as histopathology with or without direct immunofluorescence, anticardiolipin antibodies, homocysteine levels, proteins S and C, and cryoglobulins. Serum levels of ANCA, antinuclear antibodies, rheumatoid factor, complement, and hepatitis B and C virus antibodies should also be determined, together with human immunodeficiency virus serology.⁵

The case presented here was a drug-dependent patient whose clinical lesions were compatible with necrotizing vasculitis confirmed by histopathology, with a diagnosis of an ANCA-positive cutaneous vasculitis (p-ANCA, 1:2560 U/mL, antilactoferrin antibodies, 48.2 U/mL). The differential diagnosis included other forms of ANCA-positive small-vessel vasculitis. The role of ANCA in the pathogenesis of vasculitis is still unclear. One hypothesis suggests that ANCA stimulate neutrophil degranulation, activation, and apoptosis, leading to direct and indirect endothelial damage.⁶ Drug-induced ANCA show a perinuclear fluorescence pattern (p-ANCA) and positivity to several antigens (myeloperoxidase, cathepsin G, proteinase 3, azurocidin, bactericidal/permeability-increasing protein, lactoferrin, and human neutrophil elastase). Reports in the literature suggest that the presence of lactoferrin and human neutrophil elastase supports the diagnosis of a cocaine-related syndrome.^{3,7}

The management of these patients is still a matter of debate, but good outcomes have been reported with the use of systemic steroids, nonsteroidal immuno-

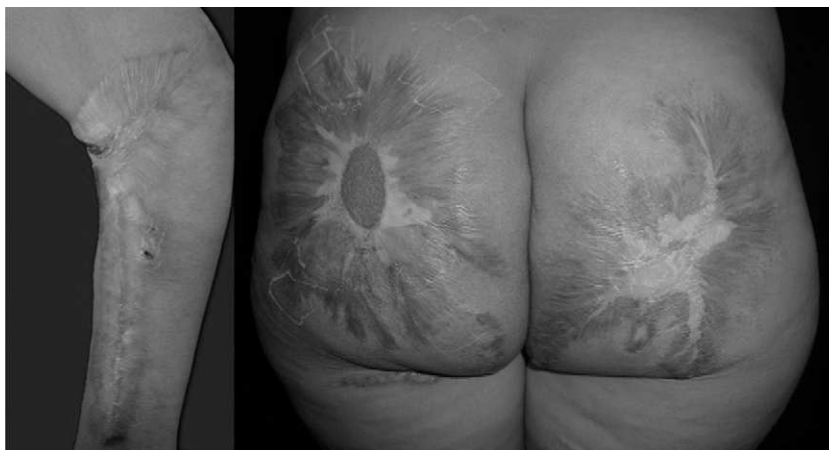

Figure 3 Photograph at 7 months of follow-up. There is reepithelialization of the lesions and scarring.

suppressants, antihistamines, dapsone, pentoxifylline, and intravenous immunoglobulin.⁸ Our patient stopped taking cocaine and was treated with thalidomide and systemic corticosteroids. Although the outcome was excellent, significant scarring could not be avoided.

References

1. Stone JH. Vasculitis: a collection of pearls and myths. *Rheum Dis Clin North Am.* 2007;33:691–739.
2. Roche E, Martínez-Menchón T, Sánchez-Carazo JL, Oliver V, Alegre de Miquel V. Piodermas gangrenosas eruptivas asociadas al consumo de cocaína inhalada. Presentación de dos casos. *Actas Dermosifiliogr.* 2008;99:727–30.
3. Walsh NMG, Green PJ, Burlingame RW, Pasternak S, Hanly JG. Cocaine related retiform purpura: evidence to incriminate the adulterant, levamisole. *J Cutan Pathol.* 2010;37:1212–9.
4. Neynaber S, Mistry-Burchardi N, Rust C, Samtleben W, Burgdorf WHC, Seitz MA, et al. PR3-ANCA-positive necrotizing multi-organ vasculitis following cocaine abuse. *Acta Derm Venereol.* 2008;88:594–6.
5. Merkel PA. Drug-induced vasculitis. *Rheum Dis Clin North Am.* 2001;27:849–62.
6. Khasnis A, Langford CA. Update on vasculitis. *J Allergy Clin Immunol.* 2009;123:1226–36.
7. Csernok E, Lamprecht P, Gross WL. Clinical and immunological features of drug-induced and infection-induced proteinase 3-antineutrophil cytoplasmic antibodies and myeloperoxidase-antineutrophil cytoplasmic antibodies and vasculitis. *Curr Opin Rheumatol.* 2010;22:43–8.
8. Pham T, Heinly C, Herman C, Selim MA. P-ANCA positive cocaine associated vasculitis: a case report. *J Cutan Pathol.* 2008;32:109.

Y. Salas-Espindola,^a A. Peniche-Castellanos,^{a,*}
I. López-Gehrke,^a P. Mercadillo-Pérez^b

^a *Servicio de Dermatología, Hospital General de México, México, D.F*

^b *Servicio de Dermatopatología, Hospital General de México, México, D.F*

*Corresponding author.

E-mail address: amelia_peniche@yahoo.com.mx
(A. Peniche-Castellanos).

Alopecia Areata After Biologic Therapy: Report of a Case Related to Adalimumab[☆]

Alopecia areata y terapias biológicas. Presentación de un caso asociado a adalimumab

To the Editor:

Alopecia areata (AA) is an autoimmune disorder causing non-scarring hair loss. It is an organ-specific response at the cellular level and is mediated by CD4⁺ and CD8⁺ T cells. These lymphocytes may be activated by autoantigens at the hair root, inducing inflammation that eventually leads to hair loss. The increased use of biologic therapies has recently led to a growing number of publications discussing the possible link between these treatments and autoimmune disorders, including AA.

A 39-year-old man with plaque psoriasis on a regimen of adalimumab (40 mg) twice weekly presented with 2 alopecia plaques after 1 year of treatment. The plaques, located on the cranial vertex, had appeared over the previous few weeks (Fig. 1). The patient had no family or personal history of AA and reported no events involving infection, vaccination, or stress prior to the loss of hair. AA was diagnosed, adalimumab treatment was stopped, and a daily application of clobetasol propionate 0.05% cream was prescribed. After 6 months the diameter of both alopecia plaques had not changed despite the withdrawal of adalimumab.

Adalimumab is a recombinant and fully humanized monoclonal antibody that works against tumor necrosis factor

α (TNF- α) and has been approved for the treatment of rheumatoid arthritis, ankylosing spondylitis, Crohn disease, psoriasis, and psoriatic arthritis. TNF- α is a proinflammatory cytokine in the body's immune system, but when it is neutralized by anti-TNF- α antibodies like adalimumab, autoimmune disorders such as systemic sclerosis and systemic lupus erythematosus have been known to develop.¹ The role of TNF- α in the physiopathology of these processes is complex, but the cytokine has been shown to originate in the mononuclear cells that surround the hair follicle in AA¹ and inhibit hair follicle growth during in vitro testing.² TNF- α is thus linked to hair loss. Accordingly, anti-TNF- α medications and other biologic therapies have been used to treat AA, but with poor results; in some sporadic cases satisfactory responses have been reported, but no large study has demonstrated any significant therapeutic effects of etanercept,³ alefacept,⁴ or efalizumab.⁵

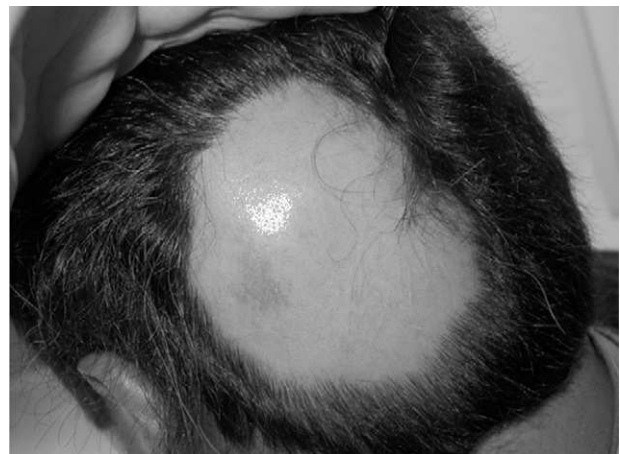

Figure 1 Alopecia areata plaque located on the cranial vertex after a year of adalimumab treatment.

[☆] Please cite this article as: Neila J, et al. Alopecia areata y terapias biológicas. Presentación de un caso asociado a adalimumab. *Actas Dermosifiliogr.* 2011;102:827-828.