

# ACTAS Derma-Sifiliográficas

Full English text available at  
www.elsevier.es/ad



## CASE FOR DIAGNOSIS

### Long-Standing Thickening of a Nail in a Mechanic

### Engrosamiento ungueal de años de evolución en un mecánico

#### Medical History

A 47-year-old man working as a mechanic and with no other relevant past history consulted for an abnormality of the nail of the right index finger that had appeared 4 years earlier with no apparent trigger. The lesion had increased progressively in size but the patient reported no associated clinical symptoms.

#### Physical Examination

Physical examination revealed a clearly defined grayish-yellow thickening of the lateral border of the nail accompanied by increased transversal curvature of the nail plate (Figure 1). Small orifices were present on the free border of the nail. Fine projections were seen at the proximal end of the lesion during excision.

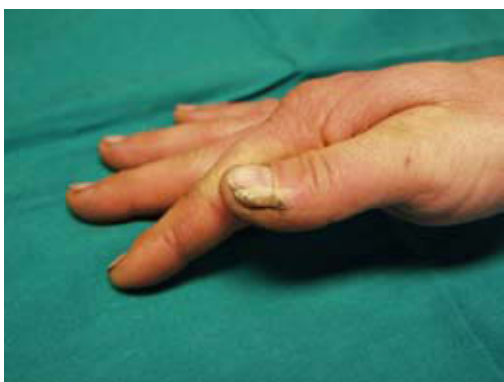

Figure 1

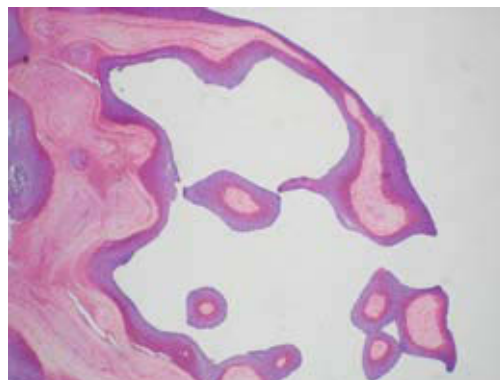


Figure 2 Hematoxylin-eosin, original magnification  $\times 40$ .

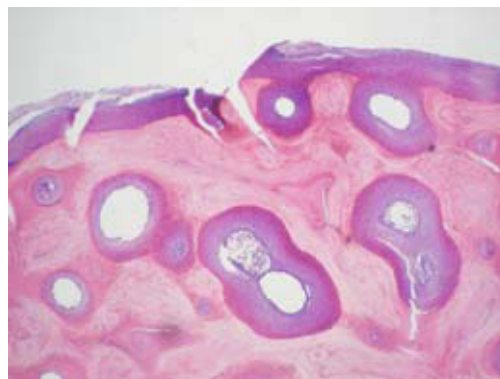

Figure 3 Hematoxylin-eosin, original magnification  $\times 40$ .

#### Histopathology

Histology of the proximal area showed a stratified squamous epithelium typical of a nail matrix with the absence of a granular layer and the presence of spikes and V-shaped areas of keratinization (Figure 2). A transverse section from a slightly more distal position showed epithelial projections with a fibrovascular core and some optically empty cavities in the thickness of the nail plate. The number of empty cavities increased and the number of papillary projections decreased toward the distal border of the nail plate (Figure 3).

#### What Is Your Diagnosis?

## Diagnosis

Onychomatricoma.

## Clinical Course and Treatment

The nail deformity was corrected through excision of the tumor with a lateral matricectomy. There was no recurrence after 9 months of follow-up.

## Comment

Onychomatricoma is a rare tumor of the nail plate first described by Baran and Kint<sup>1</sup> in 1992, with fewer than 50 cases described. The condition appears in middle age, most commonly on the hands.

Typical clinical characteristics include longitudinal thickening of the nail plate, increased transverse curvature, a whitish-yellow color, splinter hemorrhages in the proximal area and multiple cavities in the distal border of the thickened nail.<sup>2</sup> During excision, filiform projections were seen to emerge from the nail matrix. Histology showed a nail plate with projections with a fibrovascular core covered by normal epithelial matrix that keratinized with no granular layer alternating with optically empty cavities.

The etiology is unknown. Cases have been described of giant onychomatricoma affecting the entire nail plate in patients with a history of local trauma.<sup>3</sup> Trauma is frequently considered a possible cause in onychomatricoma as the condition is more commonly found on the hands than the feet, especially on the right hand—relevant in this case as the patient was a mechanic by trade.

Cañueto Álvarez et al<sup>4</sup> showed a possible link between onychomatricoma and genomic loss on chromosome 11 in their analysis of array-based comparative genomic hybridization.

Perrin et al<sup>5</sup> recently described various forms of the condition: onychomatricoma located in the lateral nail fold with a verrucous surface, similar to a wart or Bowen disease, total dystrophy of the nail mimicking squamous cell carcinoma, and a third pseudofibrokeratoma type. Differentiation from these other conditions is based on clinical examination and histopathology.

In 1998, Perrin et al<sup>2</sup> described histological characteristics differentiated into 2 areas: a proximal area from the root to the cuticle with epithelial invaginations and V-shaped areas of keratinization, a thickened nail plate with an undulating inferior border ending in unguis spurs, and a fibrillary stroma clearly demarcated from the undersurface; and a distal area corresponding to the lunula, characterized by multiple linear “glove-finger” projections running in an antero-oblique direction, lined with matrix epithelium

around connective tissues axes, and perforation of the nail plate by numerous cavities that, at the distal border of the lunula, become filled with serous fluid.

In cases where there is any doubt, magnetic resonance imaging provides findings considered pathognomic, including proximal Y-shaped figures oriented longitudinally in the nail plate and a transverse image showing cavities.<sup>6</sup>

This type of tumor is possibly underdiagnosed as the patient may not consult, the doctor may not diagnose it due to the rarity of the condition, or because of inherent difficulties in the histological study resulting from poor orientation of the planes of section or fragmentation of the tissue specimen.

## Conflict of Interest

The authors declare that they have no conflict of interest.

## References

1. Baran R, Kint A, Onychomatricoma. Filamentous tufted tumour in the matrix of a funnel-shaped nail: a new entity (report of three cases). *Br J Dermatol.* 1992;126:510-5.
2. Perrin C, Goettmann S, Baran R. Onychomatricoma: clinical and histopathologic findings in 12 cases. *J Am Acad Dermatol.* 1998;39:560-4.
3. Estrada-Chavez G, Vega-Memije ME, Toussaint-Caire S, Rangel L, Domínguez-Cherit J. Giant onychomatricoma: report of two cases with rare clinical presentation. *In J Dermatol.* 2007;46:634-6.
4. Cañueto J, Santos-Briz A, García JL, Robledo C, Unamuno P. Onychomatricoma: Genome-wide analyses of a rare nail matrix tumor. *J Am Acad Dermatol.* 2011;64:573-8.
5. Perrin C, Baran R, Balaguer T, Chignon-Sicard B, Cannata GE, Petrella T, et al. Onychomatricoma: new clinical and histological features. A review of 19 tumors. *Am J Dermatopathol.* 2010;32:1-8.
6. Goettmann S, Drapé JL, Baran R, Perrin C, Haneke E, Belich S, et al. Onychomatricome: deux nouveaux cas. Intérêt de la resonance magnétique nucléaire. *Ann Dermatol Venereol.* 1994; 121(Suppl 1):145.

C. López-Obregón,<sup>a,\*</sup> M.A. Arregui,<sup>a</sup> J.M. Arrinda<sup>b</sup>

<sup>a</sup>*Servicio de Dermatología, Hospital Donostia, San Sebastián, Guipúzcoa, Spain*

<sup>b</sup>*Servicio de Anatomía Patológica, Hospital de Bidasoa, Guipúzcoa, Spain*

\*Corresponding author.

*E-mail address:* cris\_lopez\_obregon@hotmail.com (C. López-Obregón).