

5. Ferreres JR, Maevo A, Marcoval J. Melanoma primario múltiple. *Actas Dermosifiliogr.* 2009;100:414-9.
6. Stanganelli I, Testori A, Pizzichetta MA, Cochran AJ. Dermatoscopic and histopathological diagnosis of primary and metastatic melanoma: report of a workshop at the Third Research Meeting on Melanoma, Milan, Italy, May 2003. *Melanoma Res.* 2004;14:231-5.
7. Conejo-Mir JS, Camacho F, Ríos JJ, González-Cámpora R. Epidermotropic metastasis coexisting with multiple primary cutaneous malignant melanomas. *Dermatology.* 1993;186:149-52.
8. Kornberg R, Harris M, Ackerman AB. Epidermotropically metastatic malignant melanoma: differentiating malignant

melanoma metastatic to epidermis from malignant melanoma primary in epidermis. *Arch Dermatol.* 1978;114:67-9.

M. Contreras-Steysl,\* E. Herrera-Acosta, B. Moyano, E. Herrera

*Servicio de Dermatología, Hospital Clínico Universitario Virgen de la Victoria, Málaga, Spain*

\*Corresponding author.

*E-mail address:* torosmar1@hotmail.com (M. Contreras-Steysl).

## Neoplasia de células dendríticas plasmocitoides

### Plasmacytoid Dendritic Cell Tumor

*To the Editor:*

We describe 3 cases of the rare disorder known as plasmacytoid dendritic cell tumor.<sup>1</sup>

Case 1 corresponds to a 68-year-old man who presented with a 3-month history of asymptomatic, solid, erythematous-violaceous nodules and plaques on the trunk and extremities (Figure 1A). Skin biopsy revealed a dense infiltrate in the dermis that extended to the hypodermis, and the presence of a Grenz zone, with no invasion of the blood vessels or skin appendages. The pleomorphic infiltrate was composed of cells with a myelodysplastic appearance and prominent nucleoli, together with other elongated, hyperchromatic cells (Figure 2). Immunohistochemistry was positive for the CD4, CD7, CD43, CD45, CD56, and CD123 (Figure 2C) and for terminal deoxynucleotidyl transferase (TdT) (Table). A radiological extension study revealed subcentimeter lymph nodes, but no neoplastic cells were observed in a bone marrow biopsy. Treatment with 5 cycles of cyclophosphamide, doxorubicin, vincristine and prednisone (CHOP) chemotherapy led to remission of the skin lesions, but the patient died 4 months later as a consequence of disease progression.

The second patient was a 70-year-old man who presented with generalized violaceous macules, papules and flat tumors that spared the face and acral regions (Figure 1B). Histology and immunophenotype (Figure 3, A and B) were identical to the previous case, except for a positive result for type 1 T-cell lymphoma (TCL-1). The extension study revealed enlarged inguinal lymph nodes and polymorphic blast cell infiltration of the bone marrow. Administration of the acute leukemia protocol developed by PETHEMA (Spanish Program for the Study and Treatment of Hematological Malignancies) for medically fragile patients resulted in a 6-month remission, after which the disease progressed and the patient died.

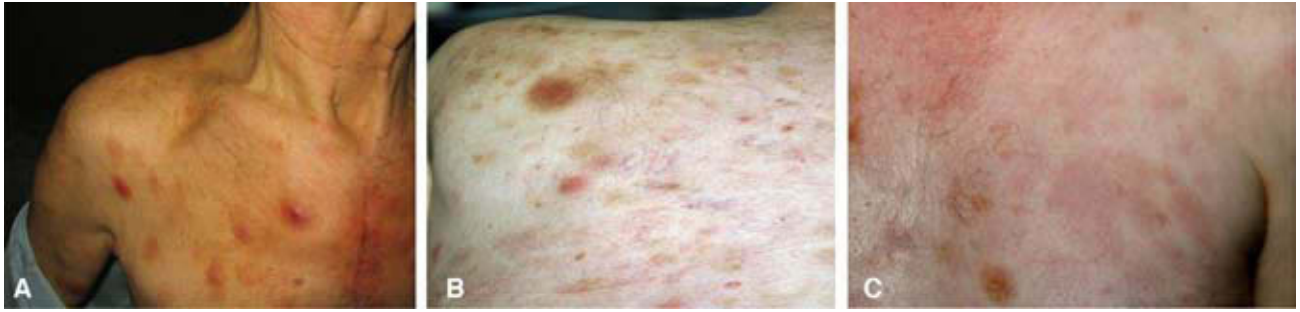Case 3 corresponds to a 52-year-old man who presented with brownish and erythematous macules and plaques on the trunk and extremities (Figure 1C). Biopsy revealed a dense infiltrate of monomorphic medium-sized blast cells with abundant mitoses throughout the dermis (especially in the deep dermis), and the presence of a Grenz zone. There was also evidence of bone marrow infiltration. Immunohistochemistry results are summarized in the Table. The patient achieved complete remission in response to treatment with daunorubicin and cytarabine. He subsequently received an allogeneic bone marrow transplant from a human leukocyte antigen-identical sibling, and, at the time of writing, has been in clinical remission for 12 months.

Plasmacytoid dendritic cell tumor, which occurs most frequently in older men, is estimated to account for 0.7% of all cutaneous lymphomas. It probably originates in nonantigen-presenting, interferon-producing type 2 dendritic cells, which differentiate into plasmacytoid precursor cells.<sup>2</sup> Plasmacytoid dendritic cell tumor is thought to be a form of aleukemic leukemia cutis, similar to myelogenous leukemia.<sup>3</sup>

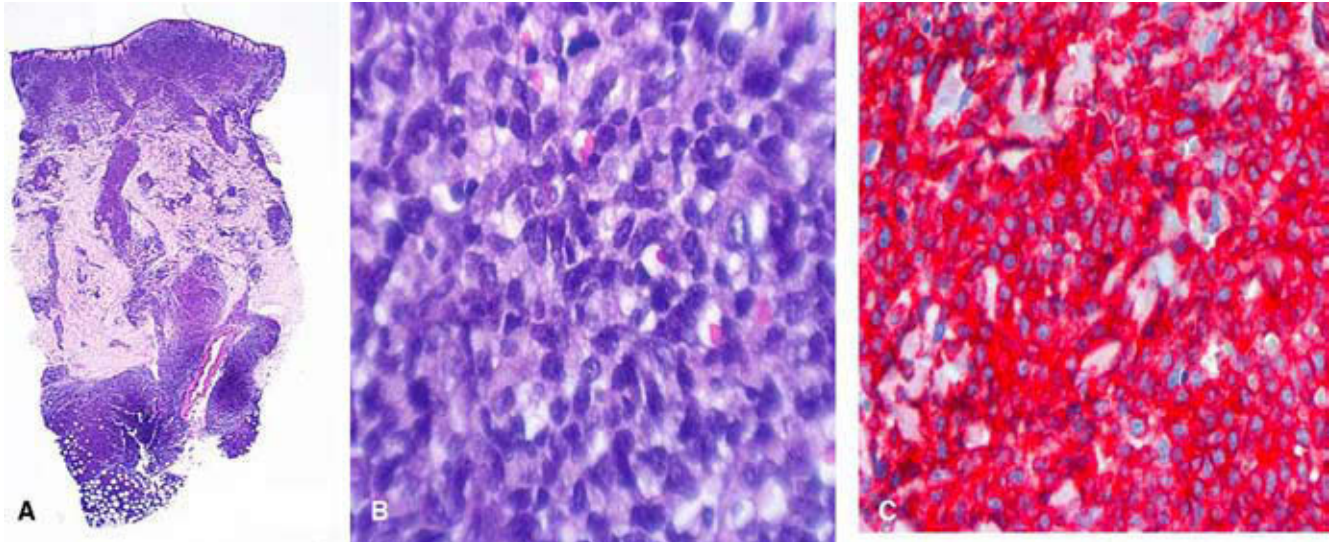
Early symptoms appear in the skin in 50% of patients. Other organs are involved in the other 50% of patients (lymph nodes, 50%; spleen, 20%; mucosa, 10%; and bone marrow, 5%-25%). The early development of B symptoms and of leukemia is rare; cytopenia, however, may develop.<sup>2</sup> The most frequently described skin symptom is the appearance of disseminated, violet-colored plaques and tumors—as was the case with our patients—although presentation as a solitary tumor is also possible.<sup>4</sup> Cota et al<sup>5</sup> distinguish between 3 types of skin signs: tumors and generalized plaques, a solitary tumor, and disseminated macules.

Despite a good initial response to treatment in 80% of patients, the disease usually progresses rapidly to fulminant leukemia, which is myelomonocytic in 10% to 20% of cases.

Histology typically shows a dense infiltrate throughout the dermis that extends into the hypodermis. In up to 20% of cases, there is only a discreet perivascular or interstitial infiltrate. The presence of a Grenz zone is characteristic. The cells may be atypical medium-sized mononuclear cells with dispersed chromatin, or there may



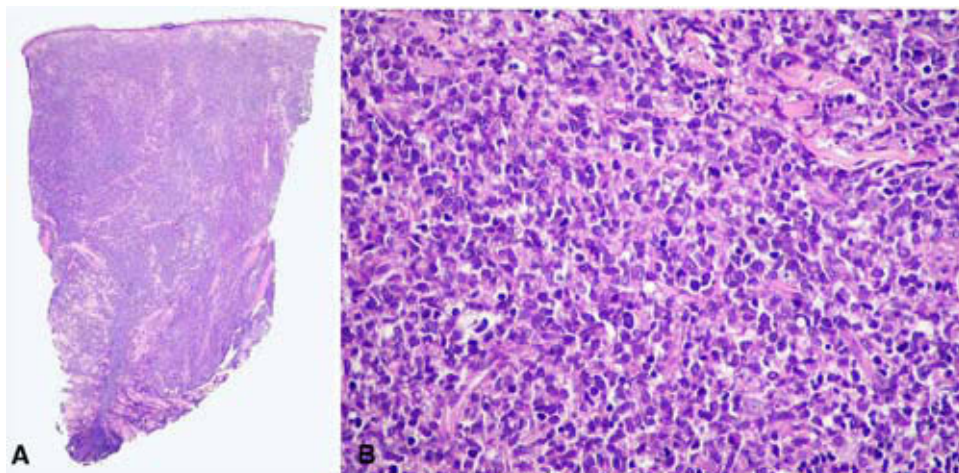
**Figure 1** A, B, and C, nodules and asymptomatic erythematous-violaceous plaques on the trunk and extremities.



**Figure 2** A and B, infiltrate of cells with a myelodysplastic appearance and prominent nucleoli (hematoxylin-eosin, original magnification  $\times 2$ ). C, diffuse positivity for CD123 (hematoxylin-eosin, original magnification  $\times 10$ ).

be a pleomorphic infiltrate with elongated hyperchromatic cells, some of which may be centrocyte-like in appearance.<sup>5</sup> Mitoses are frequent, but necrosis, vascular invasion, and epidermotropism are rare. All 3 of our cases presented with a diffuse dermal infiltrate, which was pleomorphic in 2 of the patients, but monomorphic in the third patient.

The key to diagnosis is immunohistochemistry.<sup>3</sup> CD4 and CD56 are typically positive, though CD123 and the recently discovered BDCA-2/CD303 and BDCA-4 are more specific markers.<sup>6</sup> B-cell, T-cell, and granulocyte lineage markers are, by definition, negative. Deletion of 5q is present in 70% of cases.<sup>7</sup>



**Figure 3** A and B, dense pleomorphic dermal infiltrate (hematoxylin-eosin, original magnification  $\times 2$  and  $\times 4$ ).

**Table 1** Immunohistochemical phenotypic profile of the patients.

Positive markers	Negative markers
CD4	CD3
CD56	CD5
CD123	CD7
CD43	CD15
TdT	CD20
TCL-1 (Case 3)	Lysozyme
CD43	Myeloperoxidase
CD45RA	

Abbreviations: TdT, terminal deoxynucleotidyl transferase; semicolon TCL-1, type 1 T-cell lymphoma.

With regard to treatment, different chemotherapy options—from CHOP to leukemia regimens—have been tested, but bone marrow transplantation is considered to be the best treatment. In a study of 57 patients, Dale et al<sup>8</sup> observed better survival in patients who had received transplants compared to other therapies (31.3 months vs 12.8 months). Preventive intrathecal chemotherapy has also been recommended.<sup>9</sup> Advanced age and the combination of negative TdT and positive BDCA-2 are negative prognostic factors.<sup>10</sup>

Of our 3 cases, only the patient who received a bone marrow transplant achieved remission lasting longer than 6 months. Thus, even though ours is a very small series, it supports the evidence for bone marrow transplantation as the best therapeutic option. Although TdT was positive in all our patients, this marker had no apparent bearing on survival. As has been reported in the literature, bone marrow involvement at the time of diagnosing the patients did not influence prognosis.<sup>2</sup>

Our 3 cases reflect the typical presentation of plasmacytoid dendritic cell tumor, and suggest the importance of early treatment in order to improve what is normally a poor prognosis.

## References

1. Lim MS, Leval L, Quintanilla-Martínez L. Commentary on the 2008 WHO classification of mature T- and NK-cell neoplasms. *J Hematopathol*. 2009;2:65-73.

2. Jegalian AG, Facchetti F, Jaffe ES. Plasmacytoid dendritic cells: physiologic roles and pathologic states. *Adv Anat Pathol*. 2009;16:392-404.
3. Cerroni L, Wiesner T. Cutaneous lymphomas: from morphology to chip technology. *Actas Dermosifiliogr*. 2009;100:3-17.
4. López V, Martí N, Ferrández A, Martín JM, Jordá E. An atypical presentation of a blastic plasmacytoid dendritic cell tumors. *J Cutan Pathol*. 2010;37:e50-2.
5. Cota C, Vale E, Viana I, Requena L, Ferrara G, Anemona L, et al. Cutaneous manifestations of blastic plasmacytoid dendritic cell neoplasm—morphologic and phenotypic variability in a series of 33 patients. *Am J Surg Pathol*. 2010;34:75-87.
6. Marafioti T, Paterson JC, Ballabio E, Reichard KK, Tedoldi S, Hollowood K, et al. Novel markers of normal and neoplastic human plasmacytoid dendritic cell. *Blood*. 2008;111:3778-92.
7. Kaune KM, Baumgart M, Bertsch HP, Mitteldorf C, Müller-Hermelink HK, Haase D, et al. Solitary cutaneous nodule of blastic plasmacytoid dendritic cell neoplasm progressing to overt leukemia cutis after chemotherapy: immunohistology and FISH analysis confirmed the diagnosis. *Am J Dermatopathol*. 2009;31:695-701.
8. Dalle S, Beylot-Barry M, Bagot M, Lipsker D, Machel L, Joly P. Blastic plasmacytoid dendritic cell neoplasm: is transplantation the treatment of choice? *Br J Dermatol*. 2010;162:74-99.
9. Kedward AL, McGalíe C, Venkatraman L, Hamilton J, El-Agnaf M, McKenna K. Plasmacytoid dendritic cell neoplasm treated successfully with rituximab. *J Eur Acad Dermatol Venereol*. 2010;24:742-3.
10. Jaye DL, Geigerman CM, Herling M, Eastburn K, Waller EK, Jones D. Expression of the plasmacytoid dendritic cell marker BDCA-2 supports a spectrum of maturation among CD4+ CD56+ hematodermic neoplasms. *Mod Pathol*. 2006;19:1555-62.

M. Pérez-Crespo,<sup>a,\*</sup> M. Moragón,<sup>a</sup> J. Onrubia,<sup>b</sup> A. Sevilla,<sup>a</sup> R. Alfonso,<sup>a</sup> J. Miralles,<sup>a</sup> L. Requena<sup>c</sup>

<sup>a</sup>Servicio Dermatología, Hospital Universitario de San Juan, Alicante, Spain

<sup>b</sup>Servicio de Anatomía Patológica, Hospital Universitario de San Juan, Alicante, Spain

<sup>c</sup>Servicio de Dermatología, Fundación Jiménez Díaz, Madrid, Spain

\*Corresponding author.

E-mail address: mariaperezcespo@hotmail.com (M. Pérez-Crespo).

## Generalized Multinucleated Cell Angiohistiocytoma

### Angiohistiocitoma de células multinucleadas generalizado

To the Editor:

Multinucleate cell angiohistiocytoma (MCA) is a benign fibrohistiocytic and vascular proliferation. This rare disorder

was first described by Smith and Wilson Jones<sup>1</sup> in 1985, and since then about 80 cases have been reported in the literature. The disorder occurs most frequently in women. Lesions are in the form of clusters of erythematous, violaceous, or brownish-colored papules located in a single anatomical area, usually the lower extremities,<sup>2</sup> or the dorsal aspect of the hands, wrists, or fingers; however, it has also been described on the trunk, forehead, cheeks, oral mucosa, lips, and orbit. Generalized cases are exceptional.<sup>3-5</sup> Although lesions are usually asymptomatic, some are pruritic.