

ACTAS Derma-Sifiliográficas

Full English text available at
www.elsevier.es/ad



PRACTICAL DERMATOLOGY

Surgical Planes of the Head and Neck

E. Samaniego,* C. Prada, M.Á. Rodríguez-Prieto

Servicio de Dermatología, Complejo Asistencial de León, León, Spain

Manuscript received June 24, 2010; accepted for publication July 13, 2010

KEYWORDS

Surgical plane;
Head and neck;
Superficial
musculoaponeurotic
system

PALABRAS CLAVE

Plano quirúrgico;
Cabeza y cuello;
Sistema
musculoaponeurótico
superficial (SMAS)

Abstract The surgical plane is a plane of dissection that can be used to excise a tumor while preserving most of the neurovascular structures. The majority of skin tumors are situated on the head and neck, and dermatologic surgeons should therefore have detailed knowledge of the surgical anatomy of this region. Fear of damaging important structures may result in insufficient efficacy of the surgical treatment, with consequent risk of persistence or recurrence of the tumor. Knowledge of the superficial musculoaponeurotic system and its relationship to key neurovascular structures enables the operation to be planned and will help us to locate the appropriate plane and minimize postoperative complications. The objective of this article is to review the key anatomical features defining suitable planes of dissection in the head and neck, the use of which will ensure survival of flaps and grafts.

© 2010 Elsevier España, S.L. and AEDV. All rights reserved.

Planos quirúrgicos en cabeza y cuello

Resumen El plano quirúrgico es el plano de disección por el que podemos realizar la exéresis del tumor respetando la mayoría de las estructuras anatómicas neurovasculares. La mayoría de los tumores cutáneos se localizan en la cabeza y el cuello. Por tanto, es importante para el cirujano dermatológico tener un profundo conocimiento de la anatomía quirúrgica de esta área. El temor a dañar estructuras importantes puede llevarnos a no ser suficientemente eficaces en el tratamiento quirúrgico, con el consiguiente riesgo de persistencia o recidiva tumoral. El conocimiento del sistema musculoaponeurótico superficial y sus relaciones con los puntos clave neurovasculares nos permitirá planificar la ejecución de la intervención, guiarnos en la localización del plano adecuado y minimizar las complicaciones posquirúrgicas. El objetivo de este artículo es revisar las características anatómicas claves para el conocimiento de los planos de disección adecuados en la cabeza y el cuello, y con ello, asegurar la supervivencia de los colgajos e injertos.

© 2010 Elsevier España, S.L. y AEDV. Todos los derechos reservados.

Introduction

During our surgical training in dermatology, and even afterwards, we may not infrequently be apprehensive about

*Corresponding author.

E-mail address: eliasamaniego@yahoo.es (E. Samaniego).

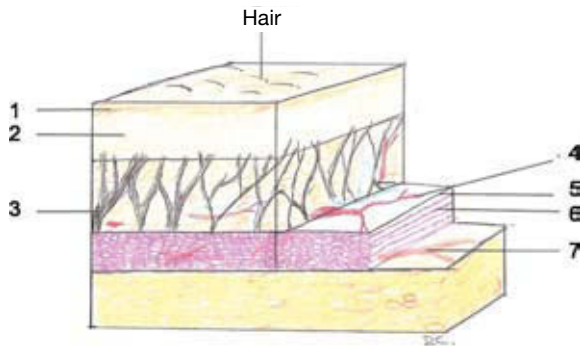


Figure 1 Structure of the superficial musculoaponeurotic system. 1 indicates epidermis; 2, dermis; 3, fibrous septa; 4, vascular plexus; 5, fascia; 6, muscle; 7, motor nerve.

the resection of tumors on the head and neck, a region that, in addition, is the site of the majority of skin tumors. Fear of damaging important neurovascular structures can lead to ineffective surgical treatment, with the consequent risk of tumor persistence or recurrence, or unnecessary stages if Mohs micrographic surgery is being used. This feeling of insecurity is often due to a lack of knowledge of the anatomical position of the different structures or doubts regarding the correct plane of dissection to be used in each area.

The surgical plane is the plane of dissection along which we can perform tumor excision while respecting the majority of anatomical structures (blood vessels, nerves, etc). This plane varies according to the anatomical region

and to the type and characteristics of the tumor to be excised (benign or malignant, superficial or infiltrating).

Knowledge of the appropriate plane in each region will enable us to ensure survival of flaps and grafts and will avoid cosmetic and functional sequelae.

The aim of this article is to review the key anatomical characteristics that determine the most appropriate depth of dissection in each area of the head and neck.

To achieve this, we shall review the following concepts: the superficial musculoaponeurotic system (SMAS), surgical planes depending on the anatomical region (in the head and neck), planes at critical sites, and useful techniques to locate the appropriate plane.

The Superficial Musculoaponeurotic System

Definition

The superficial musculoaponeurotic system (SMAS) was described by Mitz and Peyroné¹ in 1976. It is a layer of fibrous and muscular tissue that connects and sheaths the muscles of facial expression. It provides a conceptual framework that helps us to understand the fascial layers and determine the sites of important neurovascular structures.²⁻⁴

Structure, Characteristics, and Functions of the Superficial Musculoaponeurotic System²⁻⁴

The SMAS divides the subcutaneous fat into 2 layers. It also sends out fibrous septa that run perpendicularly through

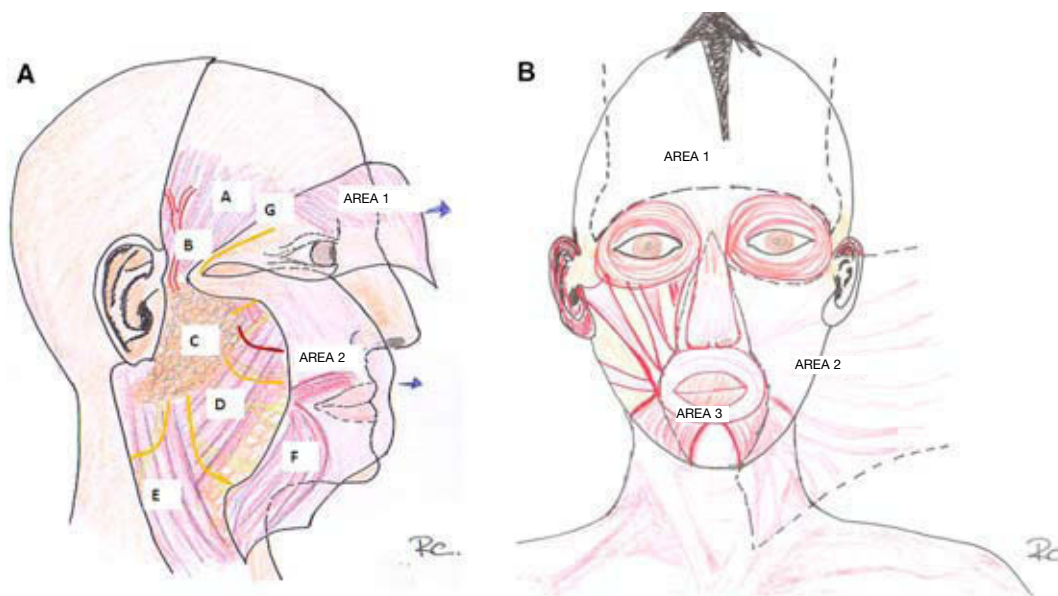


Figure 2 Regions of the superficial musculoaponeurotic system. A, Lateral view. B, Frontal view. In Figure 2A the SMAS has been lifted to reveal the deep plane. It can be seen to be discontinuous at the level of the zygomatic arch. In Area 1, the SMAS surrounds the frontalis muscle (seen through the lifted flap of the SMAS). In the temporal region, the temporal branch of the facial nerve runs within the SMAS and is particularly vulnerable at the level of the zygomatic arch, where it runs below the subcutaneous fat. In Area 2, the branches of the facial nerve (in yellow) and the parotid duct (in red) run deep to the SMAS and superficial to the masseter muscle and to the fat pads of the cheek. A indicates temporal fascia (deep fascia); B, superficial temporal artery; C, parotid gland; D, masseter muscle and buccal fat pad; E, sternocleidomastoid muscle; F, Platysma; G, temporal branch of the facial nerve.

the fat to insert into the overlying dermis (Figure 1), acting as a network that transmits contractions of the facial muscles to the skin.

To the dermatologic surgeon, the SMAS serves as a guide to perform dissection and mobilization of the tissues along appropriate planes, protecting vital structures, such as the nerves and arteries that run below it. Beneath this plane is the deep fascia, which, depending on the anatomical area, covers bone (periosteum), cartilage (perichondrium), and the muscles of mastication and organs (temporal fascia and parotid-masseteric fascia). These 2 planes (the SMAS and the deep fascia) are fused in some areas, such as in the parotid fascia and at the anterior border of the masseter.

Certain rejuvenating techniques are based on the redistribution and remodeling or fixation of the SMAS of the head and the neck.⁴

Regions of the Superficial Musculoaponeurotic System^{2,3}

The SMAS can be divided into different areas that are separated by natural landmarks and can contract independently. The consistency and thickness varies between the different areas and even within a single area. The SMAS is thicker in the upper and lateral areas of the face and thinner the lower and central areas (Figure 2, A and B).

1. First area. The boundaries are the zygomatic arch and the supraorbital ridge, terminating at the external occipital protuberance; the SMAS divides to surround the frontalis muscle. The deep layer is continuous with the galea aponeurotica of the scalp and with the superficial temporal fascia in the temporal region; these terms are therefore synonymous. The galea aponeurotica or SMAS divides again to enclose the occipitalis muscle, hence SMAS, galea aponeurotica, and superficial temporal fascia form a single structure. These fascias are structurally continuous and functionally identical. There is a discontinuity of the SMAS at the level of the zygomatic arch due to the union of the several fascial layers on the arch.
2. Second area. The SMAS extends onto the neck as the platysma and continues to the nasofacial groove and fold and to the auricular cartilage. In the preauricular part of the cheek, below the zygomatic arch, the SMAS becomes a thick, fibrous layer lying beneath the subcutaneous fat. As has been said above, the SMAS is closely adherent to the parotid fascia in the lateral part of the cheek. As it extends towards the nasofacial groove and the inferior orbital margin it becomes thinner, particularly in the middle area of the face. At the lateral border of the inferior orbital margin, the zygomatic cutaneous ligament inserts into the SMAS, dermis, inferior border of the orbicularis oculi muscle, and periorbital fat. The nasolabial fold is a true border and area of transition. Here, the middle dermis becomes thicker and there is almost no subcutaneous fat; the dermis is thus apposed to the orbicularis muscle.
3. Third area. This includes the nasofacial groove, the nose, the nasolabial fold, the perioral area, and the

upper and lower lips. There is a superficial fascia in this area, but it is much thinner and difficult to identify. Furthermore, there is little or no subcutaneous fat.

Relationships of the Superficial Musculoaponeurotic System to the Neurovascular Structures²

In the upper areas of the face, the supraorbital and supratrochlear vessels and sensory nerves penetrate the superficial surface of the SMAS or run along its surface over the superficial aspect of the frontalis muscle. In this area there is therefore a safe, avascular plane between the SMAS and the periosteum.

In the temporal region, the temporal branch of the facial nerve crosses the superficial surface of the zygomatic arch and then continues within the SMAS, superficial to the deep temporal fascia, alongside the anterior branch of the superficial temporal artery until it enters the frontalis muscle.

Below the zygomatic arch, the SMAS covers the parotid gland and becomes continuous with the platysma. In this plane the parotid duct and the buccal branch of the facial nerve run within the parotid gland.

In the lower area of the face, the motor nerves run deep to the SMAS and superficial to the masseter and to the buccal fat pad (the upper half of the buccal fat pad is situated beneath the deep layer of the temporal fascia). The motor nerves then enter the muscles of facial expression through their deep surface, except in the case of the levator angularis oris, buccinator, and mentalis muscles, which are innervated through their superficial surface. The same occurs with the vessels and sensory nerves, which run deep to the SMAS and remain at this level, except for their terminal branches. The plane of dissection in this region is therefore superficial to the SMAS.

Ligamentous Bands That Support the Facial Structures^{2,3}

There are strong retaining ligaments in the face known as osseocutaneous and fasciocutaneous ligaments. They connect the bone to the skin or run between the soft tissues. They become lax with age.

The fasciocutaneous ligaments arise in the dermis and insert onto the underlying SMAS. They are numerous and strong, particularly in the area of the forehead and around the eyes, nose, lips, and chin. They are weaker in the lateral areas of the cheeks and in the neck, and lax in the medial areas of the cheeks and in the temporal region.

The osseocutaneous ligaments connect the bone to the skin. They run between the periosteum and the overlying skin. They are the strongest of the ligamentous attachments.

The zygomatic cutaneous ligament (McGregor patch) arises from the superior surface of the zygomatic bone and inserts into the dermis, the inferior border of the orbicularis oculi muscle, and the periorbital fat.

The mandibular or mandibulocutaneous ligament runs from the jaw to the platysma and to the depressor anguli oris muscle.

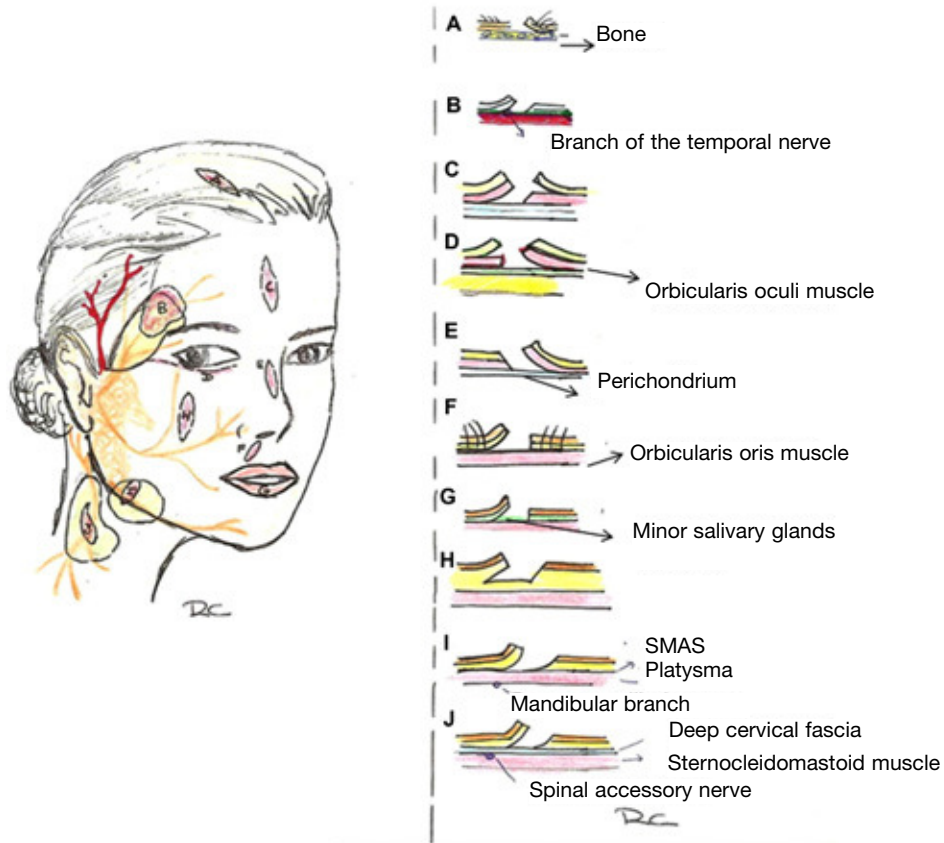


Figure 3 Planes by anatomical regions. A indicates scalp (subgaleal plane/sub-SMAS plane); B, temporal region (supra-SMAS plane); C, forehead (sub-SMAS plane or subcutaneous plane); D, periorbital region (preseptal or preorbital plane); E, temporal region (supra-SMAS/subcutaneous plane); F, cutaneous lip (supraorbicularis plane); G, mucosal lip (subglandular plane); M, cheek (subcutaneous plane); L, mandibular region (supra-SMAS/subcutaneous plane); J, neck (supra-SMAS/subcutaneous plane).

Planes by Regions³

Apart from avoiding damage to the major nerves and arteries, localization of the appropriate plane facilitates maximum tissue mobilization and survival and reduces bleeding in any procedure. We now describe the characteristics of the different planes of the head and neck (Figure 3).

Scalp (Figure 3A)

The appropriate plane is the subgaleal plane. Dissection along this avascular plane will avoid excessive bleeding and damage to the terminal hair follicles. Furthermore, the fascia is very strong and will prevent damage to neurovascular structures, which, as has been explained, run superficial to this plane. As the fascia is relatively inelastic, considerable tissue mobilization is usually required for relatively small defects.

Forehead (Figure 3C)

As we have said, the SMAS in this area surrounds the frontalis muscle and is continuous with the galea aponeurotica of the scalp. Depending on the size of the defect and the degree of infiltration if the lesion is a tumor, we should choose one of the following:

1. For large defects, we should choose the subSMAS or subgaleal plane, as in the scalp. This offers us an avascular plane, as the arteries and sensory nerves run superficial to the frontalis muscle.
2. For smaller or more superficial defects, we can use the subcutaneous plane, superficial to the frontalis muscle.

Periorbital Region (Figure 3D)

As in the perioral region, there is little subcutaneous fat and the orbicularis muscle of the eye is strongly adherent to the

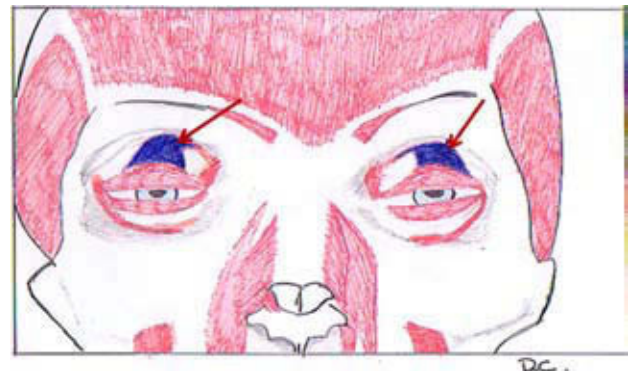


Figure 4 Diagram showing the levator palpebrae superioris muscle (in blue), indicated by the red arrows.

overlying dermis. Postoperative edema and hematomas are common in this area, as is damage to the lymph vessels. We can use the supraorbicularis or infraorbicularis planes and the pretarsal or preseptal planes.

A key point to bear in mind in this area is the levator palpebrae superioris muscle, the main muscle responsible for elevation of the upper eyelid. The aponeurosis of the levator muscle is situated in the upper eyelid immediately below the planes described, deep to the preaponeurotic fat and to the orbicularis muscle. The orbital septum and the aponeurosis of the levator palpebrae superioris muscle fuse beneath the superior border of the tarsus. Damage can be avoided by working in the plane described above (Figure 4).

Nose (Figure 3E)

In the nose, the ideal plane is deep to nasal muscle, superficial to the perichondrium and periosteum; this is an avascular plane that facilitates tissue mobilization, minimizes bleeding, and avoids damage to the sebaceous glands.

For small or superficial defects we can use the subcutaneous plane.

Ear

As in the nasal region, the appropriate plane in the ear is the supraperichondrial plane; this again is an avascular plane, which will help to minimize bleeding.

Cutaneous Lip (Figure 3F)

There is little subcutaneous fat in the perioral region, and the orbicularis oris muscle is strongly adherent to the dermis and to the mucosa. The appropriate plane in this area is the subdermal plane, superficial to the orbicularis oris muscle.

Mucosal Lip (Figure 3G)

The superior and inferior labial arteries run in the mucosal side of the lip, in the deep part of the orbicularis oris

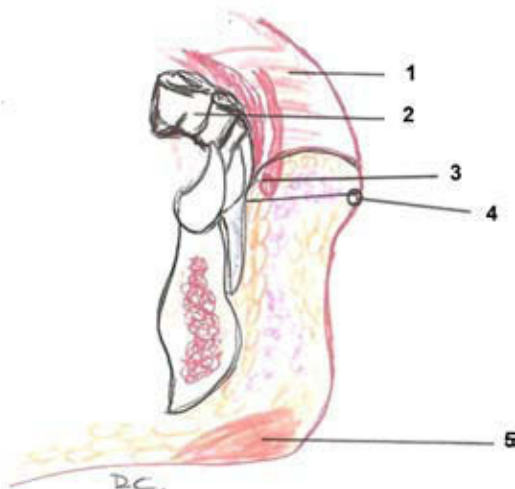


Figure 5 Diagram of the mucosal lip: 1 indicates, lip; 2, molar; 3, labial artery; 4, cutaneous border of the vermilion; 5, mentalis muscle.

muscle. The appropriate plane for vermillionectomy, for example, is therefore the subglandular plane, between the minor salivary glands and the orbicularis oris muscle. (Figure 5).

Cheek (Figure 3H)

In the middle area of the cheek, the parotid duct, the buccal fat pad, and the facial artery, vein, and nerve are in the same plane, superficial to the masseter muscle and protected by the SMAS. The angular artery is tortuous in the nasolabial fold and in the alar sulcus, but it runs deep to the muscles of facial expression. The appropriate plane in this area is the middle layer of the subcutaneous fat, as there is abundant subcutaneous tissue in this area, while the SMAS is thinner.

In the area of the mandible, we should dissect on the surface of the SMAS/platysma in order to avoid damaging the mandibular nerve, as will be explained below in the discussion of critical areas.

Neck (Figure 3J)

The SMAS in the neck is formed by the platysma and its superficial fascia. To avoid damaging nerves (cervical plexus, spinal accessory nerve), the plane of dissection should be superficial to the platysma or in the subcutaneous tissue, depending on the area of the neck involved, as will be discussed below.

Planes in Critical Areas

Critical areas are those in which there is a greater risk of damaging motor and sensory nerves due to their superficial situation. Damage to any of these structures can have serious functional, cosmetic, or sensory consequences.⁵

Damage to motor nerves produces paralysis or paresis of the muscles, producing a loss of function and facial asymmetry. The motor nerves of the head and neck at greatest risk of injury are the facial nerve (VII)—the temporal, marginal mandibular, zygomatic, and buccal branches—and the spinal accessory nerve (XI).³

Damage to superficial sensory nerves can cause anesthesia, paresthesia, or dysesthesia. The sensation of numbness may be transient, persisting for 1 to 2 years, unless the main nerve trunks are damaged. The sensory branches at greatest risk of injury during surgery are the branches of the trigeminal nerve (V)—supraorbital and supratrochlear (branches of the ophthalmic nerve, V1), infraorbital (a branch of the maxillary nerve, V2), and mental (a branch of the mandibular nerve, V3)—and the greater auricular nerve of the cervical plexus.³

What Are the Critical Areas?

Seckel⁶ described 7 critical facial areas that we will now discuss.

1. Temporal branch of the facial nerve (Figure 3B and Figure 6A).

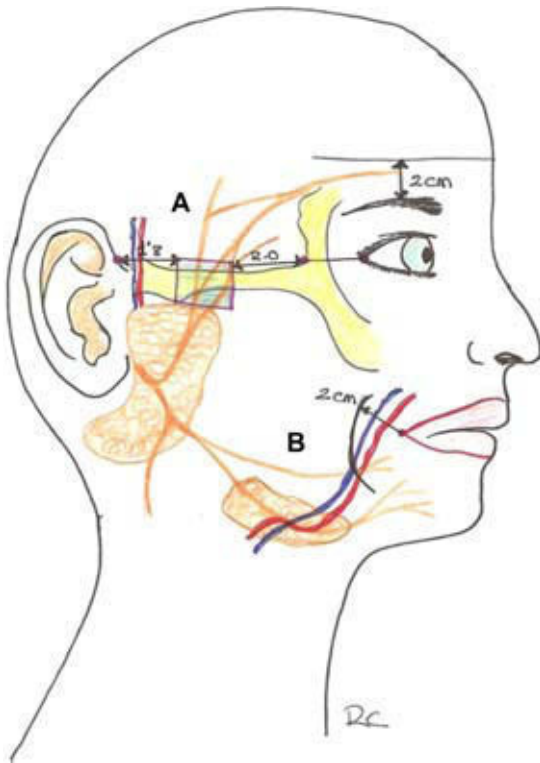


Figure 6 A, Critical point and site of the temporal branch of the facial nerve. B, Critical point and site of the marginal mandibular branch of the facial nerve.

There are 3 to 5 branches of the temporal subdivision of the facial nerve. These nerves exit the parotid gland, cross the zygomatic arch, and run within the SMAS in the temporal region, superficial to both layers of the deep temporal fascia. They penetrate the deep surface of the lateral part of the frontalis muscle and are protected by this muscle. The most posterior branch of the temporal subdivision of the facial nerve is always found anterior to the superficial temporal vessels. A point on the anterior hairline, at the level of the lateral canthus, indicates the site of union of the posterior and middle branches. The anterior branch is found about 2 cm posterior to the anterior limit of the zygomatic arch. The nerve may also be described as running below a line drawn 2 cm above the eyebrow. The nerve is particularly vulnerable as it crosses the zygomatic arch, where it is situated within the SMAS, immediately beneath the subcutaneous fat and lying directly on the bony prominence of the arch.^{2,5}

Damage to this nerve causes paralysis of the frontalis muscle, though usually with preservation of function of the orbicularis oculi muscle due to the double innervation of this muscle via the zygomatic branches. This is seen clinically as proptosis, palpebral asymmetry, and frontal asymmetry with facial movements.⁵⁻⁷

To avoid damaging the temporal branch of the nerve, dissection should be performed in the immediate subcutaneous plane and, in the area of the temporal fascia, in a plane deep to the SMAS. Over the zygomatic arch, as we have said, the nerve runs within the SMAS,

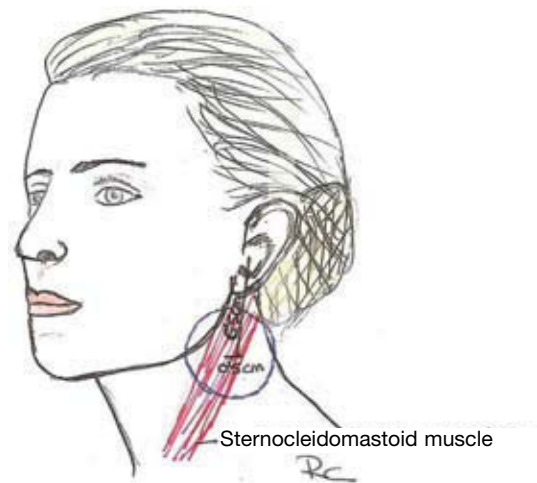

Figure 7 Site of the Erb point in the neck.

immediately below the subcutaneous fat and directly over the bony prominence of the arch. A safe plane to choose here so as not to damage the nerve as we approach the area of the zygomatic arch from above, is the temporal fat pad, situated between the 2 layers of the deep temporal fascia. These 2 layers fuse at the level of the zygomatic arch, onto which they insert.²

2. The marginal mandibular branch of the facial nerve (Figure 3I and Figure 6B).

The marginal mandibular branch emerges at the anterior border of the parotid gland and crosses the inferior border of the mandible lateral to the facial vessels to innervate the muscles of the chin and lower lip. It runs deep to the platysma muscle, which gives it protection. As the nerve approaches a point situated approximately 2 cm lateral to the angle of the mouth, it acquires a more superficial position. In this area, dissection should be performed in the subcutaneous tissue plane. Particular care is necessary in elderly and thin individuals with little subcutaneous tissue or flaccidity of the tissue structures, as the anatomical site may vary.^{2,3,5}

A lesion to this nerve causes marked deformity, particularly when the patient smiles, as it paralyzes the depressor anguli oris muscle. Patients are unable to show their lower teeth on the affected side.⁵⁻⁷

3. Zygomatic and buccal branches of the facial nerve.

The triangle formed by the malar tuberosity, the posterior border of the angle of the mandible, and the commissure of the lips defines the most vulnerable area for the zygomatic and buccal branches of the facial nerve, which run in a superficial plane, lying on the buccal fat pad. These nerves innervate the zygomaticus major and minor muscles and the levator labii superioris alaeque nasi muscle.

The nerves are situated within the deep part of the SMAS and the parotid fascia and are well protected. Injury is therefore uncommon if dissection is performed in the subcutaneous plane, superficial to the fascia.^{2,3,5}

A complete lesion causes marked deformity due to a drop of the commissure of the lips, particularly on smiling. Fortunately there are numerous connections between the buccal and zygomatic branches.^{5,7}

4. Greater auricular and spinal accessory nerves (Figure 7).

The lateral part of the neck may be thought of as a trapezoid. The sternocleidomastoid muscle divides this trapezoid into an anterior and a posterior triangle. The greater auricular and spinal accessory nerves run in the posterior triangle. The area of danger is the so-called Erb point, which is the point at which the greater auricular nerve emerges from behind the sternocleidomastoid muscle and becomes more superficial; it is therefore no longer protected by the platysma-SMAS and is susceptible to injury. A line should be drawn between the mastoid process and the angle of the jaw and, from the midpoint of this line, a perpendicular line 6 cm in length is drawn downwards to locate the Erb point. The area of risk is 2 cm above and below this point.^{2,3,5-7} The appropriate plane to avoid damage is superficial to the platysma in the anterior part of the neck and in the subcutaneous fat in the posterior part.³

Damage to the greater auricular nerve can cause anesthesia, or dysesthesia and pain in the case of a neuroma, over the inferior two thirds of the auricle of the ear and adjacent skin of the cheek and neck.⁵⁻⁷

5. Supraorbital and supratrochlear nerves (Figure 8A).

The supraorbital foramen may be located by palpation of the supraorbital ridge. It is usually found directly

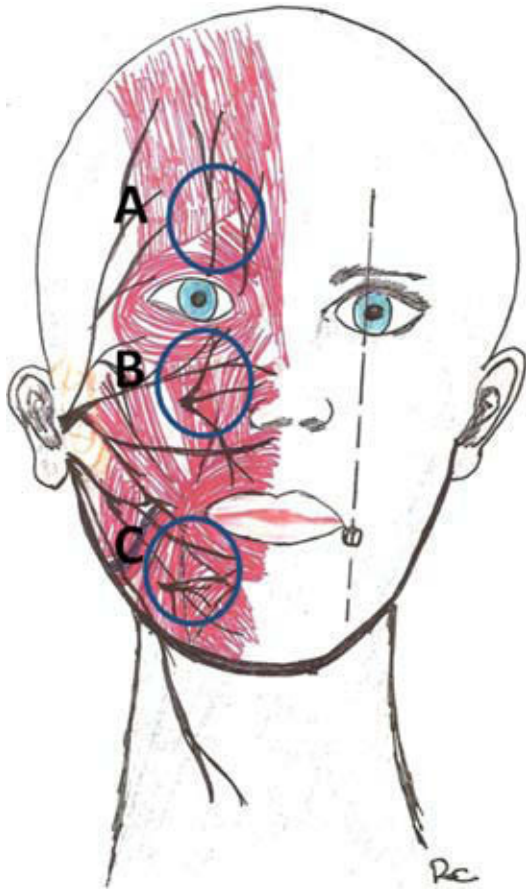


Figure 8 Critical points of the sensory nerve branches. A indicates supraorbital and supratrochlear nerves (branches of the ophthalmic nerve, V1); B, infraorbital nerve (a branch of the maxillary nerve, V2); C, mental nerve (a branch of the mandibular nerve, V3).

above the central point of the pupil. Once located, a circle with a radius of approximately 1.5 cm is drawn. After emerging from the foramen, the supraorbital nerve runs deep to the corrugator supercilii muscle, whereas the supratrochlear nerve pierces the muscle. The peripheral branches run superficial to the SMAS, and the appropriate plane is therefore deep to the SMAS.

Injury to these nerves causes anesthesia or pain and paresthesiae in the area of the forehead, the scalp, the upper eyelid, and the dorsum of the nose on the side of the lesion.⁵⁻⁷

6. Infraorbital nerve (Figure 8B).

The infraorbital foramen can be located by palpation. Once located, a circle of 1.5 cm in diameter is drawn to locate the nerve. As occurs with the supratrochlear and supraorbital nerves, its branches penetrate the SMAS and run superficial to this plane.

Injury causes anesthesia of the lateral aspect of the nose, the cheek, the upper lip, and the lower eyelid. These alterations of sensitivity can make it difficult for the patient to eat.⁵⁻⁷

7. Mental nerve (Figure 8C).

The mental foramen is situated below the second premolar. After exiting the foramen, the mental nerve runs superficial to the SMAS. To locate the nerve, a circle of 1.5 cm in diameter should be drawn around the mental foramen.

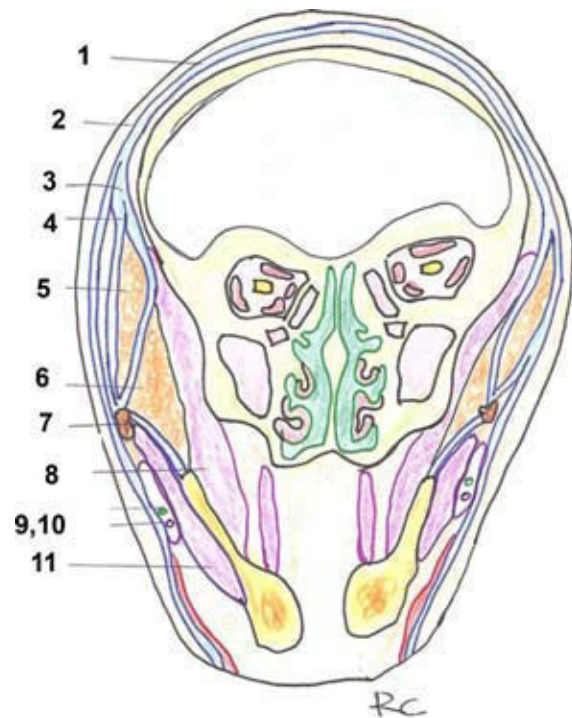


Figure 9 Diagram of the planes of the head in a coronal section. 1 indicates galea aponeurotica/SMAS; 2, temporal fascia/SMAS; 3, deep temporal fascia; 4, line of fusion of the fascias; 5, temporal fat pad; 6, buccal fat pad; 7, zygomatic arch; 8, temporalis muscle; 9, parotid duct; 10, buccal branch of the facial nerve; 11, masseter.

Injury to this nerve produces anesthesia of the ipsilateral half of the mucosa and skin of the lower lip and skin of the chin and can have serious sequelae, as it will make it difficult to hold food in the mouth and patients tend to bite the lower lip unintentionally.⁵⁻⁷

Techniques to Locate the Appropriate Surgical Plane³

1. Inject anesthesia or saline solution beneath the area of incision to distend the tissues and separate the underlying tissue planes.
2. Pull the sides of the incision apart. This opens a clear plane and separates the borders of the incision to allow better vision.
3. Use 2 skin hooks separated by 1 to 2 cm. This will lift a rectangular flap that improves vision.
4. Perform blunt dissection with scissors, without cutting, perpendicular to the tissue planes to separate them.
5. Pull the skin hooks upwards and outwards to facilitate separation of the planes.
6. Use the middle finger to determine the thickness and depth of the flap. If this is large, view and periodically palpate with the index and thumb to check it is uniform.
7. Ensure adequate lighting.

Conclusions

The majority of skin tumors occur on skin exposed to sunlight, particularly on the head and neck. It is important for the dermatologic surgeon to know the surgical anatomy of this region. Knowledge of the relationships between the SMAS and the key neurovascular points will enable better planning and performance of a procedure.

In summary, we should keep the following concepts in mind, as a simplification of the descriptions in this paper (Figure 9):

1. While there is fat above and below the plane of dissection, no vital structure will be at risk.
2. It is essential to know the relationships between the SMAS and the key neurovascular points: *a)* In the upper area of the face, the ideal plane is beneath the SMAS-galea aponeurotica. The vessels and sensory nerves

penetrate the SMAS and run within it or along its surface (supraorbital, supratrochlear) on the superficial surface of the frontalis muscle. *b)* In the temporal region, at the level of the zygomatic arch, the safest tissue plane to avoid damaging the temporal branch of the facial nerve is in the temporal fat pad. *c)* In the lower area of the face, the tissue plane to be used is superficial to the SMAS. The branches of the facial nerve at this level are deep to the SMAS and innervate the facial muscles through the deep surface of the muscles, except in the case of the levator angularis oris, buccinator, and mentalis muscles. Apart from their terminal branches, the vessels and sensory nerves also run deep to the SMAS.

Conflict of Interest

The authors declare that they have no conflict of interest.

Acknowledgments

The authors are indebted to Raquel Castrillo Pérez for all the drawings that illustrate and help to understand the descriptions in the text.

References

1. Mitz V, Peyronie M. The superficial musculoaponeurotic system (SMAS) in the parotid and cheek area. *Plast Reconstr Surg.* 1976;58:80-8.
2. Larrabee WF, Makielski KH, Henderson JL. *Anatomía quirúrgica de la cara.* 2nd ed. Venezuela: Amolca; 2006.
3. Nguyen TH. *Anatomía quirúrgica.* In: Vicente Torres Lozada-Nieto ed *Dermatología Práctica Ibero-Latinoamericana.* 1st ed. México: 2005:1560-74.
4. Ghassemi A, Prescher A, Riediger D, Axer H. Anatomy of the SMAS revisited. *Aesthetic Plast Surg.* 2003;27:258-64.
5. Elejabeitia J, Samper A. Puntos críticos en cirugía oncológica cutánea facial. *Piel.* 2001;16:307-14.
6. Seckel BR. *Zonas faciales peligrosas.* 1st ed. Venezuela: Amolca; 2000.
7. Jiménez Puya R, Vázquez Bajo C, Gómez García F, Moreno-Giménez JC. Complicaciones en cirugía dermatológica. *Actas Dermosifiliogr.* 2009;100:661-8.