

E. Gómez-Moyano,<sup>a,\*</sup> A. Crespo-Erchiga,<sup>a</sup> A. Vera Casaño,<sup>a</sup>  
A. Sanz Trelles<sup>b</sup>

<sup>a</sup>Servicios de Dermatología, Complejo Hospitalario Carlos Haya, Málaga, Spain

<sup>b</sup>Anatomía Patológica, Complejo Hospitalario Carlos Haya, Málaga, Spain

\*Corresponding author.

E-mail address: eligm80@hotmail.com

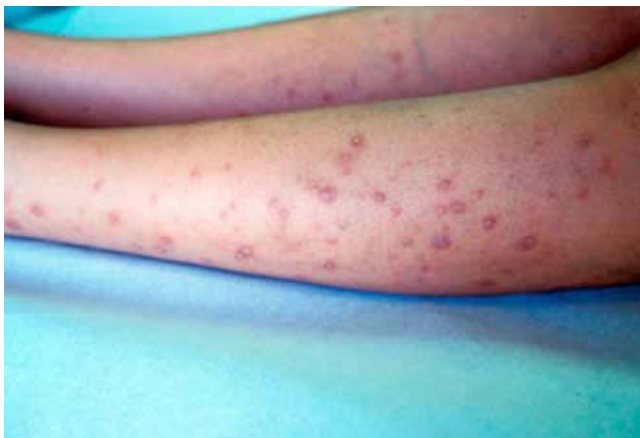(E. Gómez-Moyano).

## Vitamin A Deficiency and Bowel-Associated Dermatitis-Arthritis Syndrome Secondary to Biliopancreatic Diversion for Obesity

### Deficiencia de vitamina A y síndrome de dermatosis-artritis asociado a intestino secundario a derivación biliopancreática por obesidad

To the Editor:

Morbid obesity is a public health problem in the developed world and is considered the second most important preventable cause of death after smoking. Biliopancreatic diversion (BPD), consisting of a distal gastrectomy with Roux-en-Y reconstruction, is a surgical technique used to treat obesity.<sup>1,2</sup> The reduction in fat and carbohydrate absorption associated with this procedure can achieve a maintained loss of 75% of the excess weight.<sup>2</sup> We describe the case of a patient with BPD who presented 2 different types of skin lesions. The patient consulted 2 years after surgery with phrynoderma and night blindness due to vitamin A deficiency and later, 8 years after surgery, she presented skin lesions consistent with intestinal bypass arthritis-dermatitis syndrome.



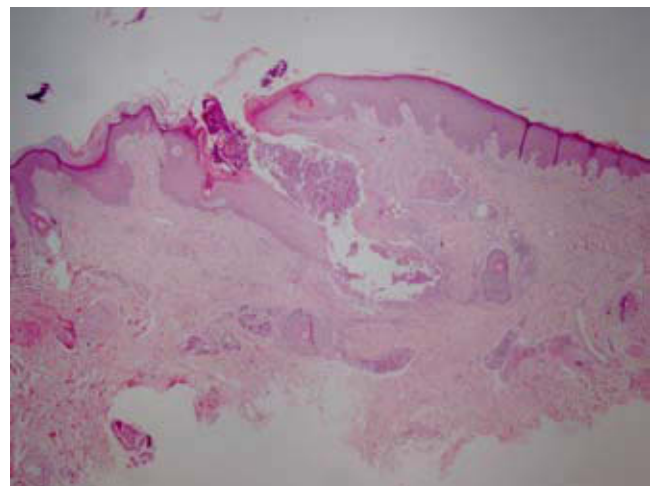
**Figure 1** Erythematous follicular papules with central hyperkeratosis on the legs.

## Case Report

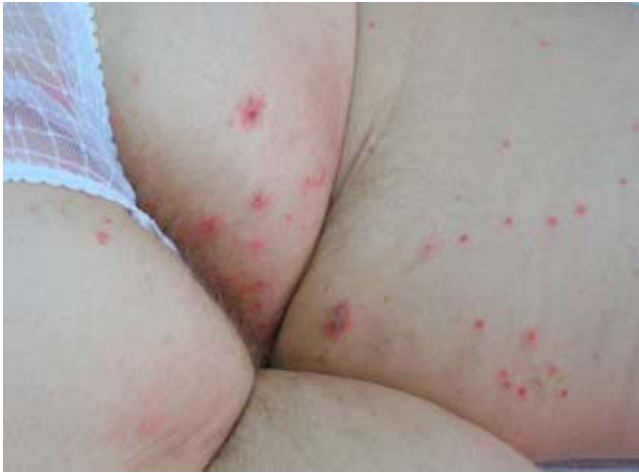The patient was a 40-year-old woman with a history of morbid obesity treated by BPD in May 2000. She had taken vitamin supplements sporadically in the years following the surgery. In September 2002, the patient who was at full-term pregnancy, consulted for a 1-month history of night blindness and skin lesions. Examination revealed erythematous follicular papules, many of which showed central hyperkeratosis; the lesions were distributed all over the body but were found in a higher concentration on the upper back and along the extensor surfaces of the arms and legs (Figure 1).

Histology showed dilation of the follicular infundibula and a central keratotic plug with cell remnants, rupture of the follicular epithelium, and associated perifollicular inflammation (Figure 2). Blood tests revealed moderate anemia, hypoproteinemia, and deficiencies of iron, folic acid, zinc, and vitamins A, B6, B12, and D. Vitamin A levels were almost undetectable at less than 0.02 mg/L (normal values, 0.3-1 mg/L). The patient had a healthy baby girl by normal delivery, although the child had undetectable levels of vitamin A.

Based on a diagnosis of phrynoderma due to vitamin A deficiency associated with anemia and other vitamin deficiencies, treatment was started with supplements of



**Figure 2** Dilation of the follicular infundibulum and central keratotic plug (Hematoxylin-eosin, original magnification  $\times 10$ ).



**Figure 3** Erythematous papules, some with an excoriated, scaly, or crusty surface, on the buttocks and thighs.

vitamins A, B<sub>6</sub>, B<sub>12</sub>, and D, folic acid, and ferrous sulfate. The patient recovered night vision and the skin lesions healed. The baby was also treated with vitamin A and her subsequent development was normal.

Six years later, in April 2008, the patient returned with a 1-week history of erythematous-violaceous papular lesions, some with an excoriated, scaly, and crusty surface, in a symmetrical distribution on the lower abdomen, buttocks, groin, and lower limbs (Figure 3). The skin disorder was accompanied by fatigue, anorexia, and low-grade fever. Vitamin A levels were found to be borderline normal. Skin biopsy revealed a perivascular inflammatory infiltrate in the dermis. The infiltrate was composed predominantly of lymphocytes and neutrophils, some of which showed nuclear fragmentation, with no necrosis of the vessel walls. Mild intestinal bypass arthritis-dermatitis syndrome was diagnosed. The lesions healed following treatment with topical corticosteroids and further surgery to lengthen the Roux loop.

Fat-soluble vitamin deficiency is a relatively common problem in patients with BPD, with an incidence of between 6% and 69%.<sup>3,4</sup> Our case illustrates how irregularity in the administration of vitamin supplements after BPD can have serious consequences, particularly when pregnancy occurs. This patient had almost undetectable levels of vitamin A and presented phrynoderma and night blindness, characteristic of this deficiency. The skin lesions healed and night vision returned following the oral administration of vitamin A and other vitamins and treatment for anemia.

Intestinal bypass arthritis-dermatitis syndrome is classed as a neutrophilic dermatosis<sup>5</sup> and has been described in association with jejunoileal bypass for morbid obesity, surgical procedures that leave a blind loop in the intestine, and in inflammatory bowel disease.<sup>6</sup> Clinical manifestations include outbreaks of skin lesions predominantly on the trunk and extremities. These begin as erythematous macules that

progress to papules, papulopustules, or papulovesicles that persist for 2 to 8 days and recur every 4 to 6 weeks.<sup>6,8</sup> The lesions are generally accompanied by influenza-like symptoms and joint pains.<sup>6,7</sup>

The first publication of intestinal bypass arthritis-dermatitis syndrome in a patient with a history of BPD surgery for morbid obesity was by Cantatore et al<sup>9</sup> in 1991. Later, in 2004, Slater et al<sup>10</sup> described a similar case in a woman aged 47 who presented joint pain and a skin rash 4 months after BPD surgery. The case of our patient is notable for the late development of intestinal bypass arthritis-dermatitis syndrome, as the skin lesions occurred 8 years after surgery.

In conclusion, we present a new case of complications after BPD surgery for morbid obesity, presenting with 2 types of skin lesions produced by different mechanisms. The first condition, coinciding with pregnancy, was phrynoderma linked to vitamin A deficiency due to poor fat absorption. The second was intestinal bypass arthritis-dermatitis syndrome, which is classically attributed to the formation of circulating immune complexes produced by the blind loop of the bypass. Although both conditions have already been described as complications of BPD in an isolated manner, the case we present is of interest as it shows both complications in the same patient over a broad interval of time.

## References

- Scopinaro N, Gianetta E, Adami GF, Friedman D, Traverso E, Marinari GM, et al. Biliopancreatic diversion for obesity at eighteen years. *Surgery*. 1996;119:261-8.
- Scopinaro N, Adami GF, Marinari GM, Gianetta E, Traverso E, Friedman D, et al. Biliopancreatic diversion. *World J Surg*. 1998;22:936-46.
- Brolin RE, Leung M. Survey of vitamin and mineral supplementation after gastric bypass and biliopancreatic diversion for morbid obesity. *Obes Surg*. 1999;9:150-4.
- Slater GH, Ren CJ, Siegel N, Williams T, Barr D, Wolfe B, et al. Serum fat-soluble vitamin deficiency and abnormal calcium metabolism after malabsorptive bariatric surgery. *J Gastrointest Surg*. 2004;8:48-55.
- Callen JP. Neutrophilic dermatoses. *Dermatol Clin*. 2002;20:409-19.
- Rodríguez-Díaz E, Morán Estefanía M, Armijo Moreno M. Dermatitis neutrofílicas (y II). *Actas Dermosifiliogr*. 1995;86:135-43.
- Ely PH. The bowel bypass syndrome: a response to bacterial peptidoglycans. *J Am Acad Dermatol*. 1980;2:473-87.
- Hidalgo Y, Vázquez F, López-Escobar M, Manjón JA, Sánchez JL, Soler T, et al. Síndrome del bypass intestinal sin bypass intestinal en la enfermedad inflamatoria intestinal. *Actas Dermosifiliogr*. 2004;95:374-7.
- Cantatore FP, Carrozzo M, Loperfido MC. Post biliopancreatic bypass arthritis. Dermatitis syndrome. *Clin Rheumatol*. 1991;10:449-51.
- Slater GH, Kerlin P, Georgiou PR, Fielding GA. Bowel-associated dermatosis-arthritis syndrome after biliopancreatic diversion. *Obes Surg*. 2004;14:133-5.

S. Gómez-Díez<sup>a,\*</sup>, A. Mas Vidal<sup>a</sup>, T. Soler<sup>b</sup>,  
F. Vázquez-López<sup>a</sup>, N. Pérez Oliva<sup>a</sup>

<sup>a</sup>*Servicio de Dermatología,  
Hospital Universitario Central de Asturias, Oviedo, Spain*  
<sup>b</sup>*Servicio de Anatomía Patológica, Hospital Universitario  
Central de Asturias, Oviedo, Spain*

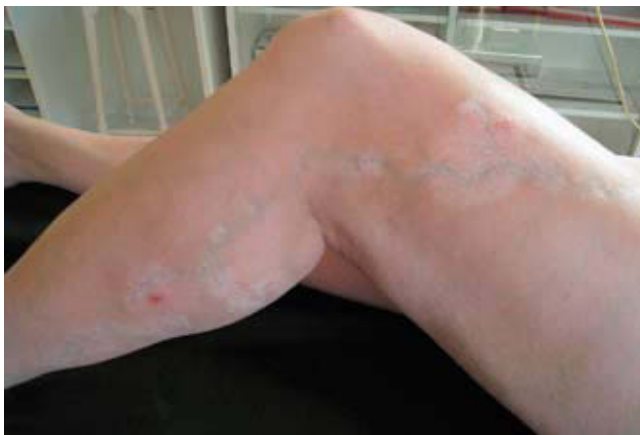\*Corresponding author.  
E-mail address: sangodi@telefonica.net  
(S. Gómez-Díez).

## Linear Vitiligo Going on a Varix Way: Possible Association with Koebner Phenomenon

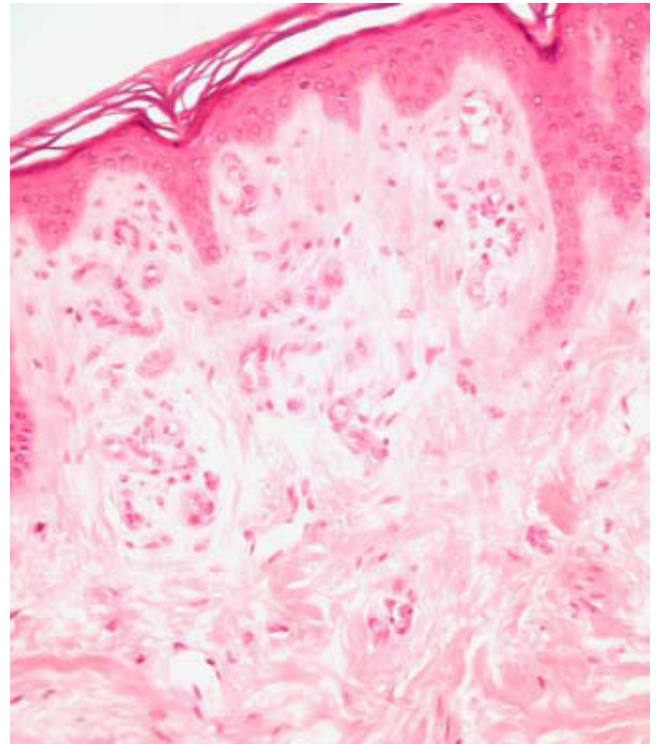
### Vitiligo lineal sobre el trayecto de una variz: posible fenómeno de Koebner

*To the Editor:*

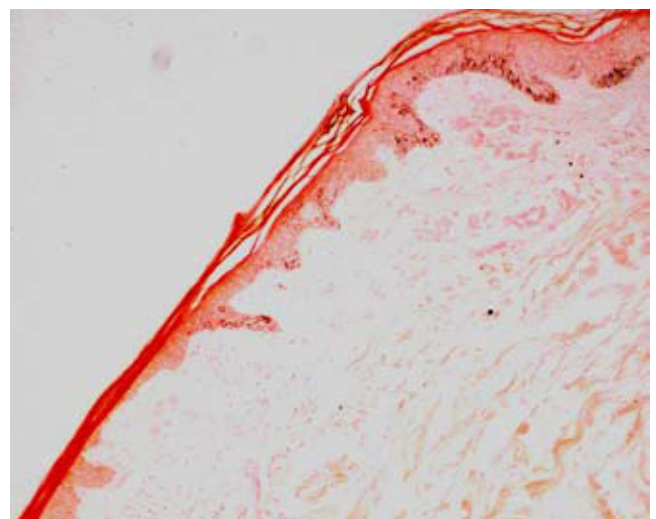
We present the case of a woman of 40 years of age with a history of obesity, systemic hypertension, and migraine, and who was on treatment with clorthalidone, propranolol, and rizatriptan. She was seen for a clearly delimited hypopigmented macule on the lateral aspect of the left thigh and lower leg, following the path of a varicose vein (Figure 1). The lesion appeared on an area of previously healthy skin. There were no other lesions characteristic of vitiligo, although the patient reported a family history of vitiligo in her maternal grandmother. Additional tests, including complete blood count, routine biochemistry, and autoimmune screening (antinuclear and antithyroid antibodies) were normal or negative. Histology of the lesion showed a normal epidermis, with the presence of vascular ectasia in the superficial dermis and no melanophages or signs of inflammation (Figure 2). Masson-Fontana staining revealed an absence of melanocytes in the basal layer (Figure 3). Clinical and histology findings were consistent with a diagnosis of vitiligo. The patient was followed up for 10 months with no treatment and perifollicular re-pigmentation was observed, supporting the previous diagnosis.



**Figure 1** Linear hypopigmentation on the path of a varicose vein and perifollicular repigmentation.



**Figure 2** Hypopigmented macule: vascular ectasia in the superficial dermis with no inflammatory infiltrate or melanophages. Hematoxylin-eosin, original magnification  $\times 200$ .



**Figure 3** Histological section through the area of transition between skin with normal pigmentation and the hypopigmented macule, showing a total absence of melanocytes in the hypopigmented area. Masson-Fontana, original magnification  $\times 40$ .