

ACTAS

Derma-Sifiliográficas

Full English text available at
www.elsevier.es/ad



ORIGINAL ARTICLE

Plaque-Phase Mycosis Fungoides Treated with Photodynamic Therapy: Results from 12 Patients

M. Fernández-Guarino,* A. Harto, B. Pérez-García, C. Montull, E. De Las Heras, and P. Jaén

Servicio de Dermatología, Hospital Universitario Ramón y Cajal, Universidad de Alcalá, Madrid, Spain

Manuscript received February 7, 2010; accepted for publication June 10, 2010

KEYWORDS

Mycosis fungoides;
Photodynamic therapy;
Methyl aminolevulinate

Abstract

Background: Recent years have seen an increase in the off-label use of photodynamic therapy for the treatment of a variety of skin diseases. Plaque-phase mycosis fungoides is among the most promising possibilities for the use of this treatment.

Objectives: To evaluate the treatment of plaque-phase mycosis fungoides with photodynamic therapy and compare the results obtained using fluorescence photography.

Material and methods: We performed a prospective, descriptive, observational study. Twelve patients with 24 lesions were treated with topical methyl aminolevulinate (MAL) under an occlusive dressing for 3 hours, followed by 8 minutes of red light (630 nm, 37 J/cm²; Aktilite).

Results: Six patients had a complete response, 5 a partial response, and 1 did not respond to treatment. A mean of 5.7 sessions was applied and no side effects were reported. Treatment tolerance was excellent.

Conclusions: Photodynamic therapy with MAL appears to be a good treatment option for patients with plaque-phase mycosis fungoides with a small number of lesions.

© 2010 Elsevier España, S.L. and AEDV. All rights reserved.

PALABRAS CLAVE

Micosis fungoide;
Terapia fotodinámica;
Metilaminolevulinico

Micosis fungoide en fase de placas tratada con terapia fotodinámica: resultados en 12 pacientes

Resumen

Introducción: La terapia fotodinámica (TFD) está siendo desarrollada en los últimos años en dermatosis diferentes de las aprobadas para su uso. Entre todas ellas, la micosis fungoide (MF) en estadio de placas es una de las más prometedoras.

Objetivos: Evaluar los resultados en el tratamiento de la MF en placas con TFD y correlacionarlos con la fotografía de fluorescencia.

*Corresponding author.

E-mail address: montsefdez@msn.com (M. Fernández-Guarino).

Material y métodos: Llevamos a cabo un estudio prospectivo, descriptivo y observacional. Se seleccionaron un total de 12 pacientes con 24 lesiones que fueron tratados con metilaminolevulinato (MAL) tópico ocluido tres horas y luz roja (630 nm, 37 J/cm², 8 min, Aktelite®).

Resultados: Un total de 6 pacientes obtuvo respuesta completa, 5 pacientes alcanzaron respuesta parcial y uno no respondió al tratamiento. La media de sesiones aplicadas fue de 5,7 y no se recopilaron efectos secundarios. La tolerancia fue excelente.

Conclusiones: La TFD con MAL parece una buena alternativa terapéutica para los pacientes con MF en placas con escaso número de lesiones.

© 2010 Elsevier España, S.L. y AEDV. Todos los derechos reservados.

Introduction

Photodynamic therapy has been under development in recent years and off-label applications have been growing in number. Currently approved indications are basal cell carcinoma, actinic keratosis, and Bowen's disease, but the effect of this treatment modality has also been explored in a variety of other inflammatory skin diseases, infections, and tumors, usually in single cases or small case series. Mycosis fungoides, in its patch phase or plaque phase, is one of the diseases in which experience has begun to accumulate.

In its early stages this disease progresses slowly, local treatment is prescribed, and the patient's condition is watched. Treatment options include topical corticosteroids, nitrogen mustard, carmustine, topical bexarotene, local radiotherapy, and psoralen plus UV-A irradiation if plaques are dispersed. When lesions are localized, few in number, and unresponsive to conventional topical treatments, photodynamic therapy can be considered.

Objective

To evaluate the treatment of plaque-phase mycosis fungoides with photodynamic therapy in terms of the number of sessions applied, time of remission, treatment tolerance, and outcome.

Material and Methods

This prospective, descriptive, open-label observational study enrolled patients with 1 or more plaques caused by mycosis fungoides. Patients met the following inclusion criteria:

- Both a clinical and histologic diagnosis of mycosis fungoides
- No demonstrated noncutaneous involvement
- Lack of response to at least 1 conventional treatment applied for an appropriate period
- Ability to follow the photodynamic therapy instructions
- Signed, informed consent to treatment

The exclusion criteria were as follows:

- Criteria stipulated by the US Food and Drug Administration¹
- A patient's low level of intelligence and poor understanding of the treatment

The lesions were occluded with methyl aminolevulinato (MAL) (Metvix, Galderma, Sweden) for 3 hours and red light (Aktelite, 630 nm, 37 J/cm²) was applied for 8 minutes. Monthly sessions were given until the treated lesions responded or lack of response was confirmed by the sixth session. Evaluation of response included clinical inspection and palpation to assess the degree of dermal infiltration as well as digital photographs to assess erythema and color changes. Complete response was defined as the disappearance of infiltrates from the lesion and the resolution of erythema; partial response was indicated by a reduction in these variables and absence of response by their persistence. Fluorescence photographs were taken before and after each session with an Olympus C5060 camera attached to a light that delivered ultraviolet flashes (400 nm) (ClearStone VD-DA digital system). Fluorescence was classified as positive if the lesion was red under Wood's light or negative if not. Positive lesions were subdivided according to whether or not the response precisely corresponded to the occluded plaque. These positive lesions were further classified according to positive or negative correlation between fluorescence and clinical course (whether or not changes in clinical manifestations were consistent with changes in fluorescence). Treatment tolerance was rated by the patient as good, fair, or poor. Once a complete response was achieved, quarterly check-ups were scheduled to monitor the lesions for continued absence of infiltration (in the case of complete response) or degree of persistent infiltration (in the case of partial response). Recurrence was recorded if infiltrates reappeared while the treated lesions were being followed. Adverse events related to treatment were recorded.

Results

Results are summarized in Table 1. Of 12 patients, 3 were men and 9 were women; a mean of 68 months (range, 12-360

Table 1 Summary of Patient Characteristics and Results

Patient No.	Age/ Sex	Time Since Onset, mo	No. of Treated Lesions	Prior Treatments	No. of Monthly Sessions	Results
1	45/M	120	1	Topical corticosteroids, PUVA	5	CR, fifth session No recurrence in 36 mo
2	30/F	12	1	Topical corticosteroids, topical immunomodulators	6	No response after 6 sessions Eczema, fourth session
3	43/F	24	3	Topical corticosteroids, PUVA	6	PR No recurrence in 22 mo
4	38/M	30	2	Topical corticosteroids	6	PR No recurrence in 15 mo
5	44/F	50	2	Topical corticosteroids, topical retinoid	6	PR No recurrence in 18 mo
6	53/M	360	2	Topical corticosteroids, PUVA	5	CR No recurrence in 14 mo
7	56/F	53	4	Topical corticosteroids, topical immunomodulators	5	CR No recurrence in 13 mo
8	40/F	30	2	Topical corticosteroids, PUVA bath	6	PR No recurrence in 12 mo
9	38/F	18	3	Topical corticosteroids	6	CR No recurrence in 10 mo
10	63/F	60	2	Topical corticosteroids, PUVA bath	6	PR No recurrence in 20 mo
11	59/F	24	1	Topical corticosteroids	6	CR No recurrence in 6 mo
12	62/F	36	1	Topical corticosteroids	5	CR No recurrence in 6 mo

Abbreviations: CR, complete response; F, female; M, male; PR, partial response; PUVA, psoralen plus UV-A irradiation.

months) had passed since the onset of disease. A total of 24 lesions were treated. All patients had been previously treated with topical corticosteroids and a few had received psoralen (by mouth or bath) plus UV-A treatment or had used a topical retinoid or immunomodulatory agent. Most patients received 6 sessions, although 4 achieved a complete response and stopped after 5 sessions. Six of the 12 patients (50%) achieved a complete response, 5 (42%) a partial response, and 1 (8%) no response. In the 11 patients who achieved a complete or partial response, the mean duration of remission was 15.6 months (range, 36-6 months). All treated plaques showed positive fluorescence that precisely followed the borders of the covered plaques, and fluorescence diminished in intensity as infiltrates decreased; it was therefore considered that fluorescence and clinical assessments were positively correlated. Half the patients rated their tolerance of treatment as good, 4 (33%) rated it as fair, and 2 (16%) as poor.

Discussion

Since the 1994 publication by Svanberg and coworkers,² in which they reported good results with photodynamic

therapy in 2 patients with patch-phase mycosis fungoides, a total of 12 reports have appeared³⁻¹⁴ (Table 2). Most have involved small patient series, for a total of 33 patients and 51 treated lesions. Table 3 summarizes all treated lesions according to clinical type and whether complete response was obtained or not. The complete response rate in the total of 46 lesions was 80%; surprisingly the rate was higher for tumors (100%) than for patches or plaques (approximately 72% and 78%, respectively). Aminolevulinic acid (ALA) was the photosensitizing agent used in all cases except the 2006 study of Zane and coworkers,¹³ in which MAL was used. Red light (usually noncoherent) was used to achieve sufficient penetration of the skin. The groups of Svanberg and coworkers and, in 2008, Díez-Recio and coworkers¹⁴ both reported good results using lasers; the latter group used a pulsed-dye laser (585 nm). All studies used several irradiation sessions, though intervals varied considerably, with treatment occurring monthly, weekly, or even several times a week. Follow-up schedules for the monitoring of post-treatment recurrences were also variable (with intervals ranging from 4 to 33 months).

The theoretical grounding for photodynamic therapy in mycosis fungoides is well known. As early as 1994, Boehncke and coworkers¹⁵ demonstrated the selective absorption of

Table 2 Studies on Patch- or Plaque-Phase Mycosis Fungoides Treated With Photodynamic Therapy

Author and Year	No. of Lesions per Patient	Occlusion, h	Light Source	Photosensitizing Agent	Fluence level, J/cm ²	Type of Lesion	Response	Recurrence
Svanberg 1994	4/2	4-6	Laser 630 nm	ALA	6	Patch	CR, 2/4	Nonspecific
Wolf 1994	2/2	4-6	Visible light	ALA	40	Plaque	CR, 2/2	None in 3-6 mo
Amman 1995	1/1	4-6	Visible light	ALA	40	Plaque	CR, 1	Nonspecific
Edstrom 1998	5/1	5	630 nm	ALA	Nonspecific	Nonspecific	CR, 4/6	Nonspecific
Wang 1999	3/1	4-6	635 nm	ALA	60	Periocular	CR	None in 33 mo
Orenstein 2000	6/2	16	580-720 nm	ALA	170-130	Patch, 1; tumor, 2	CR	None in 24 months
Markham 2001	1/1	4	580-740	ALA	20	Tumor	CR	None in 1 year
Edstrom 2001	12/10	5-18	600-730	ALA	80-180	Patch, 10; tumor, 2	1/10 plaques, no response; 2/2 tumors, no response; others, PR or CR	In lesions with CR, 4-19 mo
Leman 2002	2/1	6-24	630	ALA	100	Patch	CR	None in 12 mo
Coors 2004	7/5	6	60-160	ALA	72-144	Patch, 5; tumor 2	CR	None in 12-18 mo
Zane 2006	5/5	3	635	MAL	37.5	Patch	CR, 4; PR, 1	In CR, none in 12-34 mo
Díez-Recio 2007	2/2	4	Pulsed dye laser, 585 nm	ALA	8	Plaque	CR	None in 24 mo

Abbreviations: ALA, aminolevulinic acid; CR, complete response; MAL, methyl aminolevulinic acid; PR, partial response.

Table 3 Summary of the Complete Response Rate and Lesion Types in Published Articles

	Patch	Plaque	Tumor	Not Specified	Total
No. of lesions treated	27	7	4	8	46
Response	21/27 (78%)	5/7 (72%)	4/4 (100%)	7/8 (88%)	37/46 (80%)

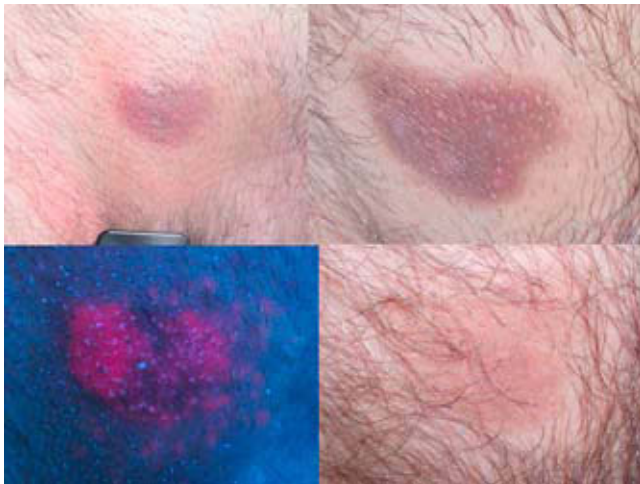


Figure Lesion treated with photodynamic therapy. The lesion (top left) and the corresponding fluorescence image (lower left) are shown. Top right, the lesion after 3 photodynamic therapy sessions; bottom right, 3 months after the fifth session there are no signs of infiltrates.

photosensitizers during photodynamic therapy for mycosis fungoides, with resultant reduction of proliferation of transformed T-cells. Later studies showed that in cutaneous lymphoma, malignant blood cells positive for CD71 (the transferrin receptor) had greater capacity to generate PpIX after ALA incubation compared to normal blood lymphocytes.¹⁶ These findings may be attributable to the fundamental role of iron in the synthesis of endogenous porphyrins. In 1998, Edstrom and coworkers⁵ reported that treating mycosis fungoides plaques with photodynamic therapy (Figure) resulted in significant reduction of the lymphocytic infiltrate (particularly of lymphocytes that are positive for CD4 and negative or only weakly positive for CD7). They also used TUNEL staining to demonstrate that the decreased infiltrate was not a result of apoptosis of atypical lymphocytes but rather of a reduction in proliferating cells. Some years later, the same authors showed that applying photodynamic therapy to mycosis fungoides lesions led to a decrease in CD71 lymphocytes in plaques and that this was accompanied by reduced proliferation.⁹

Our study sought to look more deeply into the results of photodynamic therapy in plaque-phase mycosis fungoides and lesion fluorescence. Until now, both the use of this treatment in this clinical setting and the reliance on lesion fluorescence for assessment have been in developmental

stages. Given that the clinical and histologic diagnosis of mycosis fungoides can present difficulties, patients without a confirmed diagnosis were excluded from our study to avoid including confounding variables. For the same reason we included only patients with exclusively cutaneous involvement, given that other candidates might be taking systemic treatments that would interfere with the results of photodynamic therapy. The selected patients had a history of nonresponse to at least 1 conventional treatment, given that photodynamic therapy in this setting is still under study and is not considered a first-line option.

A protocol for using photodynamic therapy in mycosis fungoides has not been established. The irradiation parameters and MAL occlusion times we used were those applied for approved indications, such as basal cell carcinoma and actinic keratosis. We adopted those parameters in an attempt to assure consistency within the sample and not introduce confounders. Also necessary are long wavelengths, around 600 nm, to assure adequate penetration at the spectrum absorbed by porphyrins. The optimal time intervals between sessions are also undetermined and studies vary greatly in this respect. With the intention of facilitating treatment adherence, we gave 1 session per month so that patients would not have to come to the hospital often.

In our patient series, the complete response rate for plaques was 50%, a sensitivity that is markedly lower than results of around 72% published in the international literature (Table 3). However, if we compare these results to those for conventional topical treatments of stage IA mycosis fungoides, photodynamic therapy emerges as a promising modality (Table 4).¹⁷ The complete response rate is superior to that of topical corticosteroids, and photodynamic therapy does not have the drawbacks of causing atrophy or only providing a short duration of effect. Photodynamic therapy is more costly, however, in terms of time and expense. Carmustine and metoclopramide achieve higher complete response rates but lead to more side effects and are less available for general clinical use. The response rates for photodynamic therapy are also superior to those of topical bexarotene.

Photodynamic therapy does not appear to be an optimal choice in comparison with psoralen plus UV-A or UV-B irradiation, however. Nonetheless, although the complete response rates of the latter therapies are superior, photodynamic therapy has the merits of being simpler and causing fewer side effects: it is not carcinogenic and requires fewer sessions. Furthermore, because red light is used, penetration is greater. This therapeutic option is best reserved for treating patients with plaque-phase mycosis fungoides who have few lesions (maximum of 4), however, because beyond that point the technique is impractical

Table 4 Complete Response Rates and Side Effects Associated With Treatments Used for Stage IA Mycosis Fungoides¹⁷

Treatment	Study Design	Complete Response, %	Adverse Events
Topical corticosteroids	Retrospective Nonrandomized trial	25-63	Skin atrophy Short duration of the therapeutic effect
Metoclopramide	Retrospective Nonrandomized trial	26-76	Contact dermatitis Secondary skin tumors
Carmustine	Retrospective Nonrandomized trial	86	Myelosuppression Telangiectasia
Bexarotene	Prospective Nonrandomized trial	21	Contact dermatitis
UV-B phototherapy	Retrospective Nonrandomized trial	75-83	Erythema, pruritus
Psoralen plus UV-A	Retrospective and prospective Nonrandomized trial	79-88	Nausea, phototoxicity, skin tumors
Electron beam radiation therapy	Meta-analysis	96	Pigmentation, itching, alopecia, telangiectasia, xerosis, anhidrosis, skin tumors

and not cost-effective. Patients with more lesions are candidates for the aforementioned phototherapies. It is theoretically possible to combine the 2 treatments, to take advantage of the patient's trip to the hospital and the fact that ultraviolet light is in the spectrum absorbed by porphyrins; no studies have been done on this combination, however. Photodynamic therapy might also be combined with systemic treatments, but these combinations have also not been studied.

Repeated sessions of photodynamic therapy are required in mycosis fungoides, as has been clear from the earliest studies by Wolf and coworkers³ in 1994 and by Amman and Hunziker⁴ a year later. No standard protocol has been set, however. In our study we used the same photosensitizing agent (MAL) and the same number of sessions (a mean of 6/lesion) as in the study by Zane and coworkers¹²; those authors scheduled weekly sessions, however, meaning that the treatment period was considerably shorter for their patients than for ours. Considering that tolerance was good and side effects absent in both studies, weekly sessions do seem to be more appropriate and beneficial, especially on comparison with other therapies.

Patients with mycosis fungoides being treated with photodynamic therapy must be followed closely, as is the case with any other treatment modality. In studies in which lesions have been biopsied after treatment, histologic cure has sometimes been observed^{4,7,8,13}; however, other authors have only observed clearing^{5,12} and still others have detected the persistence of atypical lymphocytes.⁹ We did not perform biopsies, given that the results would not have changed our approach to management: regular check-ups would have been scheduled even if a histologic cure had been demonstrated.

Lesion fluorescence after application of the photosensitizer proved its usefulness in the diagnosis of mycosis fungoides and in monitoring therapeutic response. Our findings confirm those of previous studies reporting

that fluorescence clearly marks plaques and is more diffuse around patches.^{2,7,9}

Patients tolerated the sessions well without analgesics or cooling. Only 1 patient (16%) reported poor tolerance of the sessions. Interestingly, tolerance was particularly poor in all previously reported studies with the exception of the one which employed MAL.¹³ Treatment with ALA and noncoherent light requires that the light dose be delivered in fractions, the occlusion time be shortened, and the fluence level be reduced⁷; that the lesion be anesthetized¹⁰; or that liquid nitrogen be applied around the lesion (10 cm) during treatment.¹¹ Poor session tolerance, however, has not been reported when ALA has been used with a laser light source.^{2,13}

No outstanding adverse events were noted, although 1 patient did have a generalized eczematous reaction after the fourth session. The reaction did not reappear after later sessions, however. Interestingly, this patient was the one whose lesions did not respond to treatment. Most patients' lesions cleared, leaving slight postinflammatory hyperpigmentation. Thus, the cosmetic outcome was good, although persistent hyperpigmentation, erosions, and even ulceration have all been described after photodynamic therapy.⁹⁻¹³

We can conclude that photodynamic therapy with MAL for plaque-phase mycosis fungoides is effective and well tolerated. This modality is emerging as an approach to consider for the treatment of stage IA mycosis fungoides that does not respond to conventional treatment. These preliminary results are promising, but larger studies are needed in order to establish an evidence base for the role that photodynamic therapy may be able to play.

Conflict of Interest

The authors declare that they have no conflicts of interest.

References

1. Welch EM, Kelly K. Otras indicaciones dermatológicas del ALA-PDT. In: Goldman M.P., editors. *Terapia fotodinámica*. Primera ed. Madrid: Editorial Elsevier; 2006. p. 89-101.
2. Svanberg K, Andersson T, Killander D, Wang I, Stenram U, Aderson-Engels S, et al. Photodynamic therapy of non-melanoma malignant tumours of the skin using topical delta-aminolaevulinic acid sensitization and laser irradiation. *Br J Dermatol*. 1994;130:743-51.
3. Wolf P, Fink-Puches R, Cerroni L, Kerl H. Photodynamic therapy for mycosis fungoides after photosensitization with 5-aminolaevulinic acid. *J Am Acad Dermatol*. 1994;31:678-80.
4. Ammann R, Hunziker Th. Photodynamic therapy for mycosis fungoides after topical photosensitization with 5-aminolaevulinic acid. *J Am Acad Dermatol*. 1995;33:541.
5. Edstrom DW, Ros AW, Parvit A. Topical 5-aminolaevulinic acid based photodynamic therapy for mycosis fungoides, a study of cell proliferation and apoptosis before and after therapy. *J Dermatol Sci*. 1998;16:229.
6. Wang I, Bauer B, Anderson-Engels S. Photodynamic therapy utilizing delta aminolevulinic acid in non-melanoma skin malignancies of the eyelid and periocular skin. *Acta Ophthalmol Scand*. 1999;77:182-8.
7. Orestein A, Haik J, Tamir J, Winkler E, Trau H, Malik Z, et al. Photodynamic therapy of cutaneous lymphoma using 5-aminolevulinic acid topical application. *Dermatol Surg*. 2000;26:765-9.
8. Markham T, Sheehan K, Collins P. Topical 5-aminolevulinic acid photodynamic therapy for tumour-stage mycosis fungoides. *Br J Dermatol*. 2001;144:1262.
9. Edstrom DW, Portwit A, Ros AM. Photodynamic therapy with topical 5-aminolevulinic acid for mycosis fungoides: clinical and histological response. *Acta Derm Venereol*. 2001;81:184-8.
10. Paech V, Lorenzen T, Stoehr J, Lange K, Merz H, Meigel WN, et al. Remission of a cutaneous mycosis fungoides after topical 5-ALA sensitization and photodynamic therapy in a patient with advanced HIV-infection. *Eur J Med Res*. 2002;7:477-9.
11. Leman JA, Dick DC, Morton CA. Topical 5-ALA therapy for the treatment of cutaneous T-cell lymphoma. *Clin Exp Dermatol*. 2002;27:516-8.
12. Coors EA, von den Driesch P. Topical photodynamic therapy for patients with therapy-resistant lesions of cutaneous T-cell lymphoma. *J Am Acad Dermatol*. 2004;50:363-7.
13. Zane C, Venturini M, Sala R, Calzavara-Pinton P. Photodynamic therapy with methylaminolevulinic acid as a valuable treatment option for unilesional cutaneous T-cell lymphoma. *Photodermatol Photoimmunol Photomed*. 2006;22:254-8.
14. Díez-Recio E, Zambrano B, Alonso ML, De Eusebio E, Martín M, Cuevas J, et al. Topical 5-aminolaevulinic acid photodynamic therapy for the treatment of unilesional mycosis fungoides: a report of two cases and review of the literature. *Int J Dermatol*. 2008;47:410-3.
15. Boehnke W, Koning R, Ruck A, Kaufmann R, Sterry W. In vitro and in vivo effects of photodynamic therapy in cutaneous T cell lymphoma. *Acta Derm Venereol*. 1994;74:201-5.
16. Rittenhouse-Diakun K, Van Leengoed H, Morgan J, Hryhorenko E, Paszkiewicz G, Whitaker JE, et al. The role of transferrin receptor (CD71) in photodynamic therapy of activated and malignant lymphocytes using the hem precursor delta-aminolaevulinic acid (ALA). *Photochem Photobiol*. 1995;61:523-8.
17. Whittaker SJ, Foss FM. Efficacy and tolerability of currently available therapies for the mycosis fungoides and Sezary syndrome variants of cutaneous T-cell lymphoma. *Cancer Treat Rev*. 2007;33:146-60.