

# ACTAS Derma-Sifiliográficas

Full English text available at  
[www.elsevier.es/ad](http://www.elsevier.es/ad)



## ORIGINAL ARTICLE

# Photodynamic Therapy for Acne: Use of the Pulsed Dye Laser and Methylaminolevulinate

I. García-Morales,\* A. Harto, M. Fernández-Guarino, and P. Jaén

Unidad de Dermatología del Hospital Universitario Ramón y Cajal, Madrid, Spain

Manuscript received November 19, 2009; accepted for publication March 11, 2010

### KEYWORDS

Acne;  
Photodynamic therapy;  
Pulsed dye laser

### PALABRAS CLAVE

Acné;  
Terapia fotodinámica;  
Láser de colorante  
pulsado

### Abstract

Recent decades have seen the inclusion of acne vulgaris as a potential new indication for photodynamic therapy. Photodynamic therapy and light sources can be considered to be additional tools for primary or adjunctive therapy in patients with recurrent acne or those in whom it is not possible to use other treatments. We investigated the use of pulsed dye laser plus methylaminolevulinate for photodynamic therapy and have performed a comparative study of the use of this laser alone and as an element in photodynamic therapy.

© 2009 Elsevier España, S.L. and AEDV. All rights reserved.

### Estudio del empleo de láser de colorante pulsado y metilaminolevulinato en la terapia fotodinámica del acné

### Resumen

La terapia fotodinámica (TFD) ha emergido en las últimas décadas en el estudio de potenciales nuevas indicaciones entre las que se encuentra el acné vulgar. La TFD y otras fuentes de luz pueden ser consideradas una herramienta adicional en el empleo, como tratamiento único o adyuvante, en pacientes con cuadros recidivantes o en los que no es posible la utilización de otras opciones terapéuticas. Planteamos la utilización de láser de colorante pulsado y metilaminolevulinato para la TFD. Realizamos un estudio comparativo entre el empleo aislado del láser de colorante pulsado frente a la terapia fotodinámica.

© 2009 Elsevier España, S.L. y AEDV. Todos los derechos reservados.

## Introduction

Recent decades have seen considerable progress in the development of light sources, lasers and photodynamic therapy (PDT) for use in the treatment of acne. Studies of different light sources have attempted to identify the

\*Corresponding author.

E-mail address: [irenegmorales@gmail.com](mailto:irenegmorales@gmail.com) (I. García-Morales).

most appropriate wavelength to target the pathogenic mechanisms of acne.

Endogenous PDT using different light sources has been shown in clinical trials to be effective for the treatment of mild-to-moderate inflammatory acne by acting on porphyrins produced by the bacteria (*Propionibacterium acnes*) themselves. In order to increase the photodynamic reaction and potentially treat moderate-to-severe inflammatory acne, researchers began to use an exogenous form of PDT involving the topical application of a photosensitizing agent on the area to be treated, before irradiation.<sup>1</sup> In an in vitro study of tissue from albino mice, Divaris et al<sup>2</sup> showed that ALA was metabolized to protoporphyrin IX (PpIX) in the pilosebaceous units via the heme synthesis pathway. Those authors observed a more intense accumulation of porphyrins in the pilosebaceous units in comparison with the epidermis and hair follicles. The greater quantity of porphyrins accumulated in the sebaceous glands is observed under a Wood lamp, which produces reddish orange coral-like fluorescence in the sebaceous follicles, especially in those affected by acne. This type of fluorescence has been used as a simple, noninvasive technique for monitoring the destruction of *P. acnes* and the efficacy of systemic antibiotics. Cornelius and Ludwig discovered that the intensity of the fluorescence, mainly produced by coproporphyrin III, was proportional to the number of bacteria. Hongcharu et al,<sup>3</sup> using ultraviolet photography, observed more intense fluorescence in areas affected by acne than in the surrounding tissue. It has therefore been determined that the intensity of red fluorescence is linked to the amount of porphyrins, which, in turn, correlates with the level of colonization of the pilosebaceous follicles by *P. acnes*.<sup>3,4</sup> The study by Wiegell and Wulf<sup>5</sup> of PDT using methyl aminolevulinate (MAL) used photography before and after incubation of MAL to show fluorescence in the areas with inflammatory lesions and lack of fluorescence in the noninflammatory lesions. Those authors found a statistically significant correlation between the inflammatory lesions and the high level of fluorescence of PpIX. This finding supports the theory that the absence of a photodynamic effect observed in the areas with noninflammatory lesions may be associated with a lower accumulation of PpIX.

Arkanes et al showed that the porphyrins produced by *P. acnes* were able to induce singlet oxygen on the skin surface when subjected to ultraviolet light. Emission depended on the concentration of coproporphyrin (CP), which is the porphyrin predominantly produced by the bacteria; this suggests that CP generates singlet oxygen that is efficient enough for photoradiation in a wide range of concentrations. Furthermore, this study found that production of singlet oxygen was more effective using CP than using protoporphyrin, hematoporphyrin, riboflavin, eosin, or 8-ethoxypsoralen.

Photodynamic destruction of *P. acnes* occurs when a source of visible light is applied that can activate the porphyrins produced by the bacteria. A photodynamic reaction then takes place, with the subsequent production of singlet oxygen and free radicals, which cause cell damage by destroying the lipids of the cell membrane.<sup>7</sup> A recent study by Yung et al<sup>8</sup> showed the microbiologic

effect of PDT after a single session, and compared the use of 2 esterified derivatives of aminolevulinic acid (ALA), specifically MAL and hexyl aminolevulinate hydrochloride (HAH), and subsequent application of a red-light source (Aktiles). In that study, the authors found a statistically significant reduction in the density of *Propionibacterium* species with both treatments; both treatments are well tolerated, with few adverse effects, although erythema is more common with MAL than with HAH. Treatment with MAL also showed a higher percentage of vesiculation and dryness, which was not observed with HAH. The effect of PDT is probably bactericidal and transitory, as the reduction in the bacterial count is temporary, with subsequent recolonization from the deeper parts of the adnexal structures. The drop in bacterial density correlates with the reduction in fluorescence. The findings of this study suggest that, given the transitory photoinactivation of *Propionibacterium* species, the improvement of the acne following PDT is due to other mechanisms and not just the photodynamic effect on the bacteria. Extensive epidermal degeneration following treatment has been observed in the follicular epithelium in the subpapillary dermis, with subsequent epidermal exfoliation, which leads to reduced obstruction of the follicles. Furthermore, PDT reduces inflammatory lesions by means of a nonspecific anti-inflammatory effect, and has been shown, in vitro, to have immunomodulating effects. Thus, biopsies of inflammatory acne lesions performed before PDT reveal increased expression of E-selectin, with overregulation of levels of the intercellular adhesion molecule ICAM-1 and of the proinflammatory cytokine interleukin-1. After PDT, there is a 40% reduction in ICAM-1 and expression of major histocompatibility complex II in the dendritic cells, which may explain the anti-inflammatory effects.<sup>8</sup>

The exact mechanism of action of PDT in acne is unknown but several actions have been suggested<sup>9</sup>:

- Direct photodynamic damage to the sebaceous gland, thereby causing reduced production of sebum
- Photodynamic destruction of *P. acnes*
- Increased keratinocyte replacement, with reduced hyperkeratinization and follicular obstruction

Although improvement of acne has mainly been observed with relatively long incubation times for ALA (more than 3 hours), the risk of edema, crust formation, and pigmentation abnormalities is higher. In practice, the use of short incubation times (1 hour) and multiple treatment sessions make it possible to optimize clinical efficacy and patient cooperation.<sup>10</sup> Several studies have been carried out using different regimens and light sources and have shown that PDT in acne is a safe and effective mode of treatment. Three possible treatment protocols have been published<sup>10,11</sup>:

- Incubation of 5-ALA for 1 hour followed by blue light at a wavelength of 410 nm (5-10 J/cm<sup>2</sup>), at weekly intervals
- Incubation of 5-ALA for 1 hour followed by pulsed dye laser at 595 nm (10-mm spot; 7-7.5 J/cm<sup>2</sup>), at monthly intervals

- Incubation of 5-ALA for 1 hour followed by application of intense pulsed light with a 550-nm filter (24-32 J/cm<sup>2</sup>; double pulse, 2.4 ms/4 ms; delay, 10-20 ms), at intervals of between 2 and 4 weeks

In 2006, the members of the Consensus Conference on PDT established the following points<sup>12</sup>:

- The best results are obtained when PDT is used in cases of inflammatory cystic acne.
- Less promising results are obtained when PDT is used to treat comedonal acne, although better results are achieved in these cases when a long-pulse pulsed dye laser is used.
- After a few sessions, acute acneiform eruptions may appear, which then disappear. The eruptions may even occur after a single session.
- The light source that appears to produce the best results for PDT in acne is the pulsed dye laser.
- In general, between 1 and 3 sessions are recommended, at intervals of between 2 and 3 weeks. Nevertheless, a member of the consensus group, Dr. Nestor, established that a single treatment with ALA and pulsed dye laser can maintain the improvement in acne for more than 2 years. These data, however, have not yet been published.

Based on the preliminary studies in the literature on the use of light sources and lasers to treat acne and on prior experience of the use of pulsed dye laser in different inflammatory diseases in the phototherapy and laser unit of the dermatology department of Ramon y Cajal University Hospital, Madrid, Spain, we designed this study of the efficacy and tolerance of long-pulse pulsed dye laser as the sole treatment for acne, compared to the use of PDT with MAL (Metvix) associated with pulsed dye laser as a light source.

To date, only 3 studies have been carried out on the use of MAL for PDT in acne; those studies obtained promising results in terms of the reduction of lesions—principally inflammatory lesions.<sup>5,13,14</sup> Wiegell and Wulf also carried out a study to compare the use of ALA and MAL. No significant differences were found between the 2 sensitizing agents in PDT in acne, although adverse effects were more intense and longer lasting with ALA. Prior to our study, there was only 1 study of MAL combined with pulsed dye laser, although that study was carried out on a small group of patients.<sup>13</sup> In that study, the authors achieved a reduction in the (principally) inflammatory lesions, with higher cure rates than with application of the laser alone.<sup>13</sup>

## Materials and Methods

### Patients

We performed a prospective study of 50 patients suffering from acne with different degrees of severity; the patients were referred to the dermatology department of Ramon y Cajal University Hospital, Madrid, Spain, over a period of 20 months between 2006 and 2007. The mean age of

the patients was 22.16 years (range, 14-43 years), with a predominance of female patients (62%). The acne lesions were mostly mild or moderate (approximately 32% classified in each category). Lesions were moderate to severe in 20% of cases and nodular-cystic in 16% of cases.

### Study Design

We designed a clinical survey to collect all data on patient history, including diseases that worsened when subjected to light, hormonal abnormalities, medication, date of onset and duration of acne, and prior medication to treat acne. The study procedure and the possible risks and benefits of the technique were explained to the patients, who then provided informed consent. Prior to application of the treatment, the target area was cleaned using a 70% solution of isopropanol. Metvix cream was then applied to half of the treatment area. The area was then covered with a transparent dressing to facilitate penetration of the cream and that dressing was covered with an opaque dressing to prevent light from reaching the skin. A photosensitization incubation period of 60 minutes was established. Photographs were taken under normal light before application of the photosensitizing agent and under UV light after 1 hour of incubation. Follow-up photographs were also taken every month and at the end of the study. The photographs were taken using the Clear-Stone system attached to an Olympus digital camera, which used 3 synchronized flashes of ultraviolet light. We used a source of coherent light, which we applied to both treatment areas. For this purpose, we used a long-pulse pulsed dye laser (595-nm V Beam laser, Candela Corporation, Wayland, MA, USA). The following parameters were used in both treatment areas: fluence, 2 J/cm<sup>2</sup>; 6-ms pulse; 30/20 Dynamic Cooling Device (DCD). The laser was applied by making a sweep of the entire treatment area, including areas of both healthy skin and skin with acne lesions. Patients were informed of the need to protect the treated area from sunlight and halogen lamps for 30 hours following the treatment sessions; for this purpose, we applied a sunblock with a solar protection factor of 50+, which the patients had to renew every hour. A survey was carried out to evaluate the subjective level of pain experienced by the patient, on a scale of 1 to 6 (1, no pain; 2, mild pain; 3, moderate pain; 4, severe pain; 5, very severe pain; 6 did not know or did not answer). The study protocol consisted of performing between 4 and 6 sessions at 4-week intervals. To evaluate the results, we calculated the total number of inflammatory and noninflammatory lesions before and after the treatment sessions; we also evaluated subjective levels of patient satisfaction and adverse effects.

### Statistical Analysis

We performed a cross-sectional, comparative, controlled prospective study of the efficacy and tolerability of long-pulse pulsed dye laser compared to PDT using Metvix and long-pulse pulsed dye laser in the treatment of acne. Statistical data were processed using the SPSS software package, version 13.0 for Windows. Results with *P* < .05 were considered to be statistically significant in all comparisons

in the analysis. We performed a Shapiro-Wilk test and found that the variables did not follow a normal distribution; we therefore used the Wilcoxon matched pairs signed-rank test for nonparametric samples when comparing the results obtained before and after treatment with the long-pulse pulsed dye laser and before and after PDT.

## Results

Fifty patients were enrolled, with a mean age of 22.16 years (range, 14-43 years), with a predominance of female patients (62%) over male patients (38%). The most frequent ages at onset of the acne lesions were 14 years in 54% of patients and 16 years in 38% of patients; lesions appeared before the age of 14 years in 2 patients and after the age of 14 years in 21 patients. All patients had undergone prior treatment. A majority of patients had used topical treatments (34% of patients). Patients had taken oral antibiotics in 22% of cases and oral isotretinoin in 22% of cases. Among the other patients, 10% were taking oral contraceptives and 12% combined oral antibiotics with topical treatments. In terms of patient history, none of the patients were taking photosensitizing drugs or presented photosensitivity, diseases aggravated by light, hypersensitivity to the active ingredient of the drug or its excipients, suspected malignant pigmented lesions in the treatment area, or a history of prior scarring. Ninety-two percent of patients reported no relevant medical history, whereas 8% reported only the following: 2 cases of Gilbert syndrome, 1 case of autoimmune polyglandular syndrome, and 1 case of epilepsy controlled with treatment.

The predominant site of the lesions was the face (82%); of the remaining patients (18%) had lesions on the back.

Most patients who received treatment with pulsed dye laser reported no pain (42%) and 30% and 24% of patients reported mild and moderate pain, respectively. Only 2

patients reported severe pain. The percentage of patients receiving PDT who reported no pain was similar to that of patients receiving pulsed dye laser treatment, as were the percentages of patients who reported mild or moderate pain.

The percentage of cases of erythema was slightly higher in patients who received PDT than in patients who were only treated with pulsed dye laser. Only 1 case of severe erythema was reported following PDT and no cases were reported following application of the pulsed dye laser.

The subjective level of satisfaction was evaluated globally both for the use of laser treatment alone and for PDT. Fifty-two percent of patients reported satisfaction with the results, whereas 22% reported no change in their acne lesions.

Patients underwent 4 treatment sessions in 44% of cases and 6 sessions in 56% of cases. The decision to administer either 4 or 6 sessions was taken based on the course of the disease and the results obtained with each treatment.

In terms of adverse effects, in all the patients (those who received laser treatment alone and those who were treated with PDT), only 2 cases of residual hyperpigmentation were observed and these cases resolved after between 2 and 3 weeks.

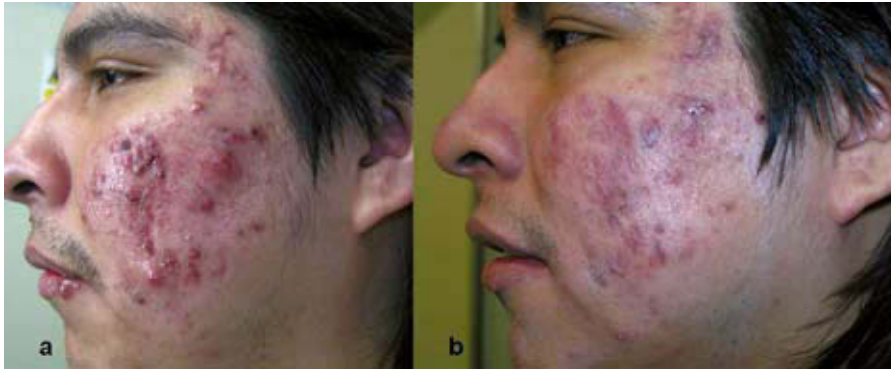The following results were obtained in the comparative study of the application of pulsed dye laser and PDT, using the Wilcoxon matched pairs signed-rank test:

1. Study of total lesions (inflammatory and noninflammatory) (Table 1, Figures 1 and 2):
  - The number of lesions was reduced by 21.94% in the half of the treatment area where only laser treatment was applied; this result was statistically significant ( $P < .001$ ) (Figure 3).
  - In the area treated using PDT, patients presented a statistically significant ( $P < .001$ ) reduction in the lesions of 44.39% (Figure 4).

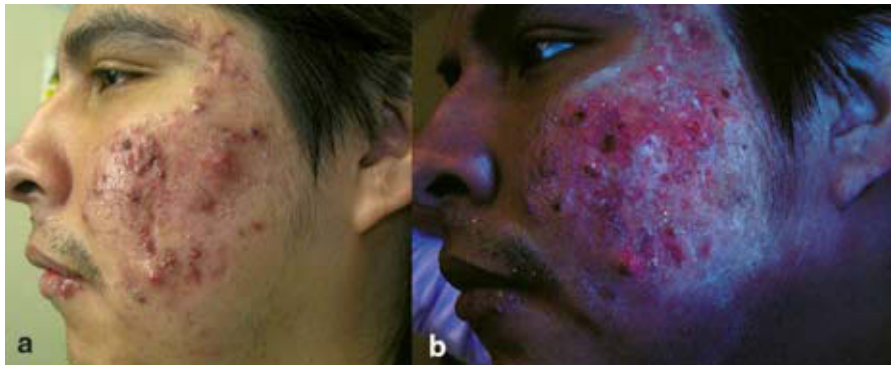**Table 1** Study of Total Number of Lesions Before and After Laser Treatment and Photodynamic Therapy

	No. of Lesions Before Laser Treatment	No. of Lesions Before PDT	No. of Lesions After Laser Treatment	No. of Lesions After PDT
N				
Valid	50	50	50	50
Lost	0	0	0	0
Mean	20.06	23.12	15.10	13.38
Median	15.50	19.00	10.50	10.50
SD	11.771	13.133	11.329	11.283
Minimum	5	7	0	0
Maximum	50	60	50	50
Percentiles				
25	11.00	12.75	7.00	5.00
50	15.50	19.00	10.50	10.50
75	26.25	30.00	20.25	20.00

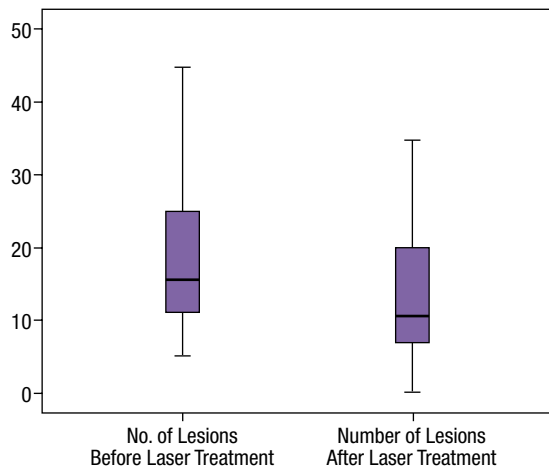
Abbreviation: PDT, photodynamic therapy.



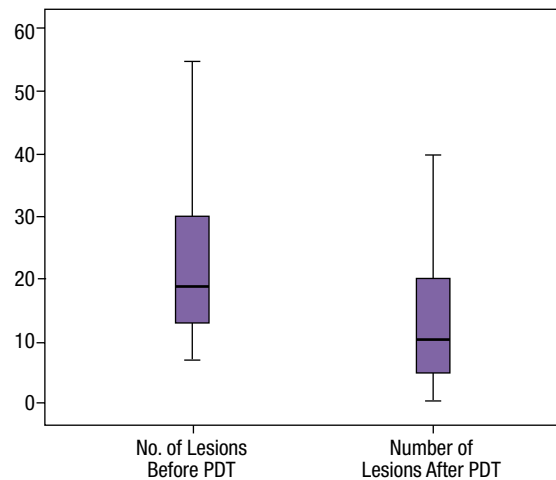
**Figure 1** a) Before photodynamic therapy (PDT). b) After 4 sessions of PDT.



**Figure 2** a) Photography under normal light. b) Photography under ultraviolet light.

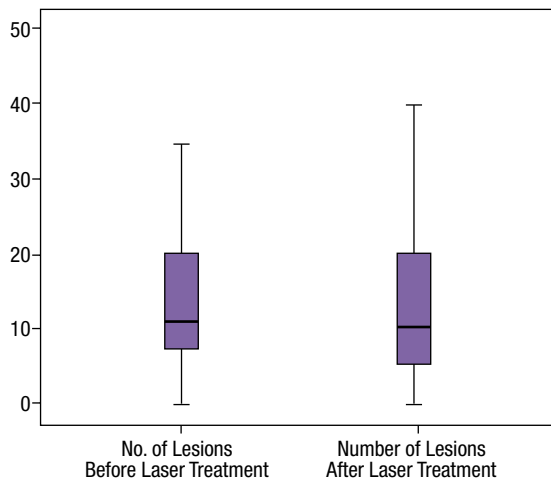


**Figure 3** Graphic representation of the total number of lesions before and after application of laser treatment.



**Figure 4** Graphic representation of the total number of lesions before and after application of photodynamic therapy.

- When we compared the percentages of reductions in the number of lesions in the area treated with laser and the area treated with PDT, we found a greater reduction after treatment with PDT than with laser alone ( $P=.002$ ) (Figure 5).
2. Study of the inflammatory lesions (Table 2) (Figures 6 and 7):
- Application of laser treatment alone produced a reduction of 17.05% ( $P<.01$ ) in inflammatory lesions (Figure 8).



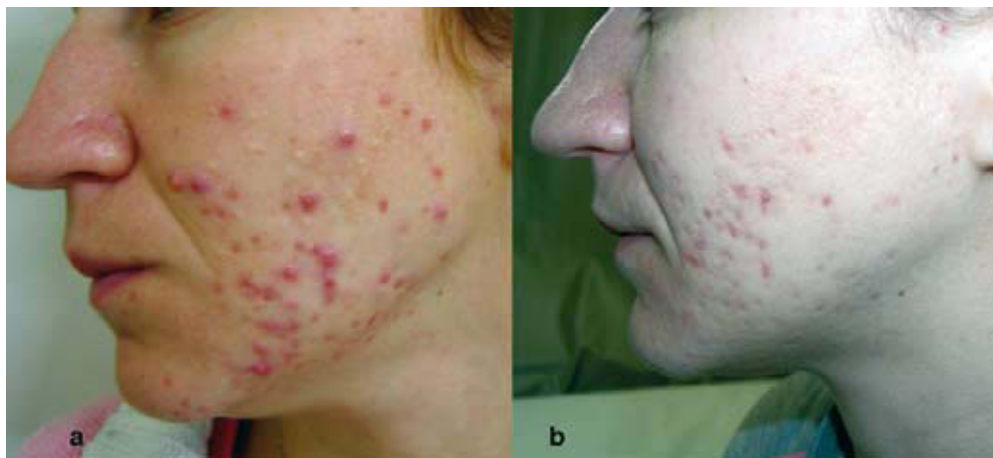**Figure 5** Graphic representation of levels of reduction of the total number of lesions after laser treatment and after photodynamic therapy (PDT).

- The study of the areas treated with PDT showed a reduction of 48.97% ( $P<.001$ ) (Figure 9).
  - Comparison of the reduction in the number of lesions after PDT and laser showed better results with PDT, although the differences were not statistically significant ( $P=.133$ ). In 17 patients, the acne increased in the area treated with PDT compared to the area treated with laser and no differences were found between the 2 therapies in 10 cases (Figure 10).
3. Study of the noninflammatory lesions (Table 3):
- Application of laser treatment alone produced a reduction of 29.25% ( $P<.001$ ) in noninflammatory lesions (Figure 11).
  - Application of PDT produced a reduction of 33.42% ( $P<.001$ ) in noninflammatory lesions (Figure 12).
  - Comparison of PDT with laser treatment alone shows a greater reduction in noninflammatory lesions in the area treated with PDT, although the difference was not statistically significant ( $P=.229$ ) (Figure 13).

**Table 2** Study of the Inflammatory Lesions With Laser Treatment and Photodynamic Therapy

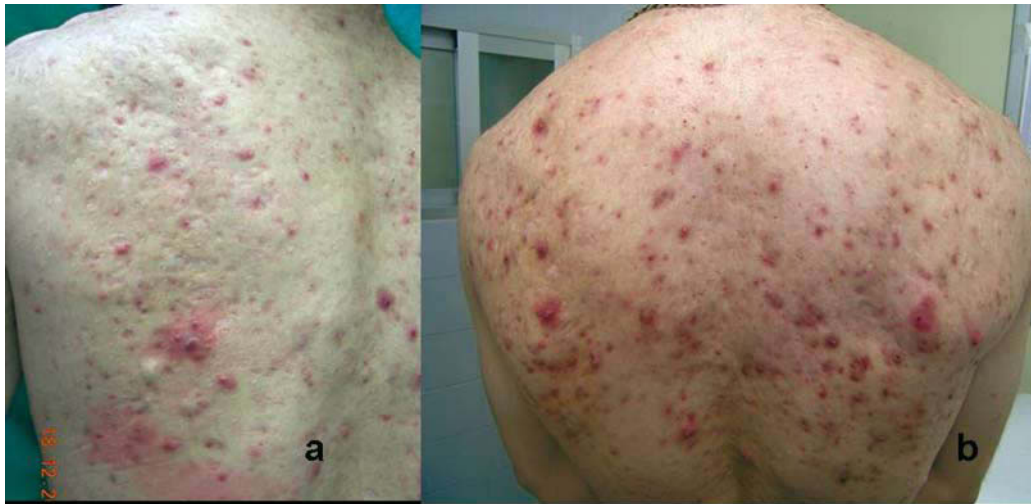	No. of Inflammatory Lesions Before Laser Treatment	No. of Inflammatory Lesions Before PDT	No. of Inflammatory Lesions After Laser Treatment	No. of Inflammatory Lesions After PDT
N				
Valid	50	50	50	50
Lost	0	0	0	0
Mean	10.32	13.30	7.96	7.00
Median	7.50	10.00	5.00	5.00
SD	7.266	8.286	7.148	6.893
Minimum	3	4	0	0
Maximum	30	40	30	30
Percentiles				
25	5.00	8.00	3.00	3.00
50	7.50	10.00	5.00	5.00
75	15.00	20.00	10.00	8.50

Abbreviation: PDT, photodynamic therapy.

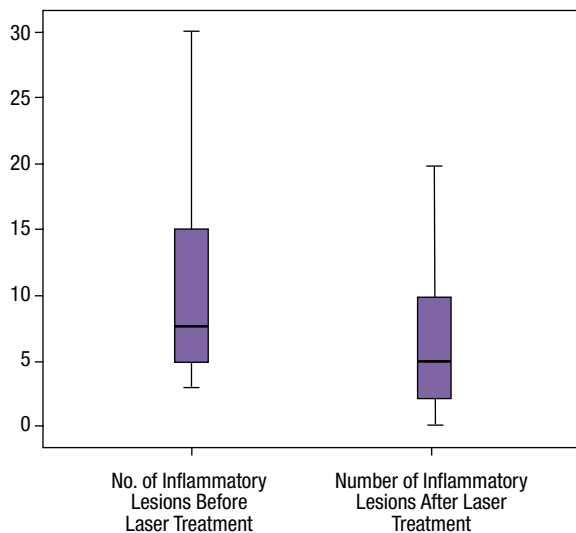


**Figure 6** Improvement after 6 sessions of photodynamic therapy.

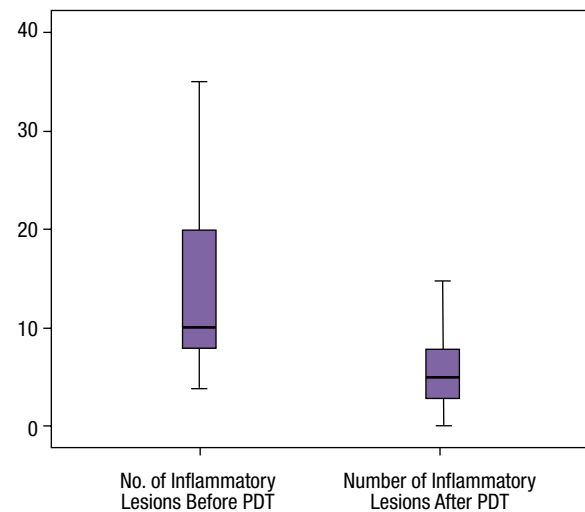




**Figure 7** Lack of clinical response with deterioration after 6 sessions of photodynamic therapy.



**Figure 8** Graphic representation of levels of reduction of inflammatory lesions after treatment with laser alone.



**Figure 9** Graphic representation of levels of reduction of inflammatory lesions after photodynamic therapy (PDT).

## Discussion

Research has been carried out since the 1990s on the use of light sources and lasers in the treatment of acne, based on 3 possible mechanisms of action: a) photoactivation of the endogenous porphyrins that *P. acnes* produces under normal conditions; b) photothermolysis of the sebaceous gland by acting on water as a target; and c) reduction of inflammation due to the phenomenon of selective photothermolysis acting on hemoglobin and, additionally, by promoting anti-inflammatory immune responses.

In the effort to increase photoinactivation of *P. acnes* and boost the mechanism of action on the sebaceous gland,

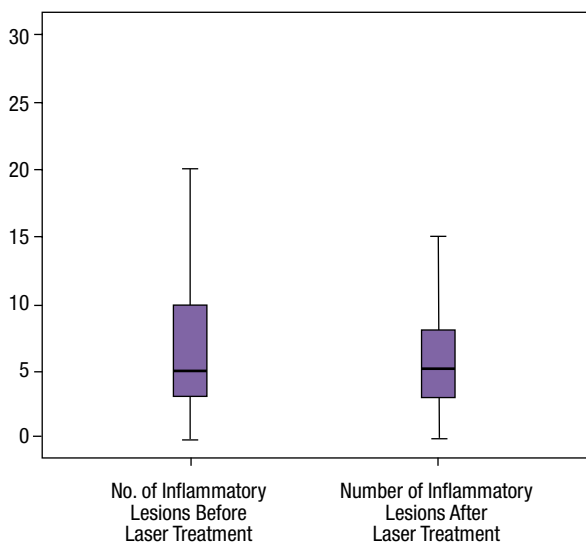
PDT has arisen as one of the most recent advances to revolutionize the treatment of acne. PDT involves the use of exogenous photosensitizing agents that lead to increased production of free radicals and singlet oxygen, which induce cell death in a more active and intense manner than with endogenous porphyrins.<sup>15</sup>

Most of the studies carried out to date on the use of PDT in acne have used ALA as a photosensitizing agent and noncoherent light sources to activate the agent. Our study is novel because it evaluates the efficacy and tolerability of PDT using MAL as a sensitizing agent and long-pulse pulsed dye laser as a light source in the treatment of acne. We also compared the results with the use of a pulsed dye laser alone.

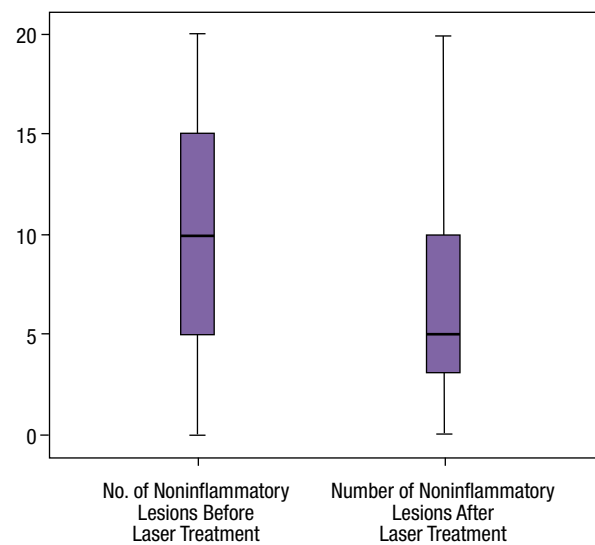
To date, only 1 study has reported the efficacy of pulsed dye laser and PDT using MAL and pulsed dye laser in a group of 15 patients over a short follow-up period.<sup>13</sup>

The factors that justify the use of the combination of MAL and long-pulse pulsed dye laser are the following:

- MAL is a highly lipophilic ester of ALA, which therefore penetrates more rapidly and deeply than ALA. Hence, MAL more readily reaches the glandular region, where the *P. acnes* bacteria are concentrated.<sup>16</sup>
- MAL is more selective for diseased skin than ALA, which tends to accumulate in both healthy and diseased skin. Accumulation of ALA in healthy skin also causes a photodynamic reaction in these areas, which explains the fact that PDT may be more painful with ALA than with MAL.<sup>16</sup>
- ALA induces homogeneous deposition of PpIX, whereas deposition is in the form of spots with MAL. This means that treatment using MAL can be more effective in areas where it is intended to act, as the photodynamic reaction takes place at the site of the lesion without affecting the surrounding healthy skin.<sup>16</sup>
- Adverse effects, such as erythema and edema, tend to be more severe and longer lasting with ALA than with MAL, due to the homogeneous deposition of PpIX caused by ALA.<sup>17</sup>
- The use of laser as a light source makes it possible to focus the energy on the areas that really require the action, with minimal dispersal of the energy, unlike noncoherent light.<sup>18</sup> This makes it possible to irradiate small areas of skin with high levels of energy and this is associated with the ability to cause fewer adverse



**Figure 10** Graphic representation of the differences in levels of reduction of inflammatory lesions between laser and photodynamic therapy (PDT).



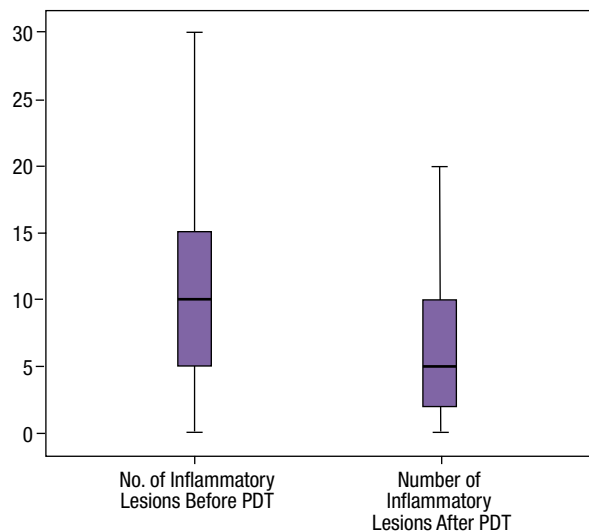
**Figure 11** Graphic representation of the levels of reduction of noninflammatory lesions after laser treatment.

**Table 3** Study of the Noninflammatory Lesions With Laser Treatment and Photodynamic Therapy

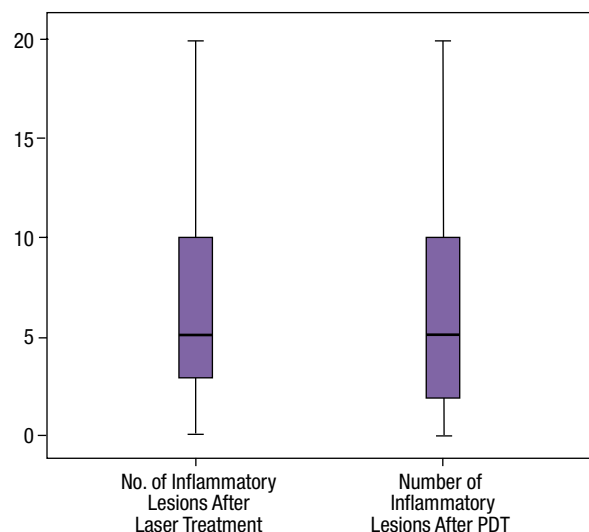
	No. of Noninflammatory Lesions Before Laser Treatment	No. of Noninflammatory Lesions Before PDT	No. of Noninflammatory Lesions After Laser Treatment	No. of Noninflammatory Lesions After PDT
N				
Valid	50	50	50	50
Lost	0	0	0	0
Mean	9.54	9.60	6.90	6.36
Median	10.00	10.00	5.00	5.00
SD	5.797	6.376	5.515	5.267
Minimum	0	0	0	0
Maximum	20	30	20	20
Percentiles				
25	5.00	5.00	3.00	1.75
50	10.00	10.00	5.00	5.00
75	15.00	15.00	10.00	10.00

Abbreviation: PDT, photodynamic therapy.





**Figure 12** Graphic representation of the levels of reduction of noninflammatory lesions after photodynamic therapy (PDT).



**Figure 13** Graphic representation of the differences in levels of reduction of noninflammatory lesions after laser treatment and photodynamic therapy (PDT).

effects. Other authors, however, recommend the use of noncoherent light sources, as they are better for treating superficial lesions that cover large areas.

- The pulsed dye laser has a wavelength (595 nm) situated in the Q band of the absorption spectrum of porphyrins.<sup>19</sup> This corresponds to a weak porphyrin excitation spectrum located between 450 nm and 700 nm; there are 4 peaks within this range, although they are weaker than those in the Soret band of the absorption spectrum for porphyrins, between 500 nm and 635 nm.

- Long-pulse pulsed dye laser has a greater penetrating ability and can therefore act on the porphyrins located in the deeper regions of the pilosebaceous follicles.<sup>19</sup>
- The pulsed dye laser has the advantage of being able to produce a variable-width pulse in the nonpurpuric range; it also has a patented DCD to minimize discomfort, a spot of up to 10 mm, and a faster treatment rate, with a firing speed of 1 Hz.<sup>18</sup>
- The use of pulsed dye laser makes it possible to act on the inflammatory component of acne, as its chromophore is hemoglobin. Furthermore, it appears to induce liberation of anti-inflammatory molecules, partly because the emission of low-energy laser light has a stimulating effect on the cells, specifically T cells.<sup>5</sup> It is thought that this laser eliminates the bacteria not only directly but also by stimulating the immune system.
- The low fluence of the pulsed dye laser induces production of procollagen due to heating of the perivascular dermis, which may be helpful in improving acne scars.<sup>4,20</sup>
- Pulsed dye laser appears to reduce comedogenesis and maturation of the follicular wall.<sup>21</sup>
- The photodynamic reaction induced by the combination of MAL and pulsed dye laser appears to cause a reduction in the size of the sebaceous glands and suppression of the gland function.
- The use of long-pulse pulsed dye laser has been associated with few side effects and we believe that these effects are not increased by the use of MAL.<sup>21</sup>

Despite the fact that many studies have been published over the last decade showing the marked efficacy of PDT in the treatment of acne, randomized, placebo-controlled double-blind trials are still required before photodynamic treatment of acne can be submitted for approval by the United States Food and Drug Administration and the European Medicines Agency as an alternative to isotretinoin.

Our study includes certain limitations. In particular, the conclusions are based on clinical data that (as in other studies) are difficult to correlate with changes in the excretion of sebum, damage to the sebaceous glands, levels of *P. acnes*, and PpIX fluorescence.

In histologic terms, only a slight abnormality of the sebaceous glands has been shown to date; although this abnormality is thought to be transitory, it may be sufficient to reduce the production of sebum, thereby causing improvement of the acne in the long term. However, the abnormal sebocytes have been observed to return to their pretreatment histologic pattern over time.<sup>3</sup>

While the specific quantitative measurement of *P. acnes* in the skin is more precise than indirect measurement using fluorescence, bacteria levels on the skin surface are different than those in the pilosebaceous ducts and do not, therefore, truly reflect the level of photoinactivation of the bacteria that takes place.<sup>8</sup> Moreover, as suggested in previous studies, the photodynamic reaction causes damage to the bacteria rather than their destruction; thus, when the bacteria are cultured in an ideal environment, they grow adequately. Hence recolonization of the skin by *P. acnes* may be observed several weeks after stopping treatment. This should not be interpreted as a failure of

PDT because, as Hongcharu et al<sup>3</sup> note, as well as the direct damage to the gland and the photodynamic inactivation of the bacteria, there appears to be an alternative mechanism of action that consists of reduced obstruction of the follicles due to increased keratinocyte replacement and reduced hyperkeratosis.

Although previous studies have assessed the results of PDT in acne based on sebum secretion analyzed using Sebustape, we consider that the values obtained using this measurement are highly variable and tend to underestimate excretion.<sup>2</sup> In our study, we deemed it unnecessary to evaluate this data, as we believe that it does not truly show the action of the treatment on the function of the gland.

We carried out a trial in the laser unit of our dermatology department, prior to this study, on the utility of pulsed dye laser in acne and determined its efficacy in reducing active acne lesions.<sup>21</sup> In the present study, we performed PDT in patients with acne, with the novel use of MAL as a photosensitizing agent, in an attempt to increase penetration and reach the sebaceous glands. To date, only 4 studies have been published that use MAL in PDT for acne; most studies use ALA.<sup>5,13,14,16,22</sup> We decided to use a pulsed dye laser as a light source instead of a source of noncoherent light, which has been used in most studies in the literature. The only previous study to perform PDT in acne using the combination of MAL and pulsed dye laser is the study recently published by Haedersdal et al.<sup>13</sup> Our study is the broadest study to date, in terms of number of patients and follow-up period, on the use of PDT with MAL and pulsed dye laser.

In terms of methodology, we established a protocol with an incubation period of 1 hour for MAL, followed by the application of long-pulse pulsed dye laser, using a fluence of 9 J/cm<sup>2</sup>, a 6-ms pulse and a 7-mm spot.

Based on our experience, we considered that multiple sessions were necessary, rather than single sessions, not only to achieve results that were maintained over time but also to achieve the results themselves, particularly when treating patients with moderate-to-severe acne. We therefore concur with the conclusions previously established by Hongcharu and Itoh. In a study of 13 patients who underwent a single treatment, Itoh et al<sup>23</sup> showed clinical improvement, but this improvement did not last more than between 3 and 6 months; the authors concluded that a single session of PDT produced reversible damage to the sebaceous glands and reported the need for multiple sessions in PDT to treat sebaceous nevus. Moreover, as confirmed in a study by Pollock et al,<sup>9</sup> rather than destroying *P. acnes*, PDT damages the bacteria so that several weeks after the end of treatment, the area is recolonized. We therefore agree with Hongcharu et al<sup>3</sup> that the use of multiple sessions is associated with lower levels of sebum secretion, reduced follicular obstruction, and damage to and reduced size of the sebaceous glands, and that this produces better clinical results that are maintained over time than when single sessions are used. We established an interval of 4 weeks between sessions, which provides sufficient time to determine the recovery of the treatment area from the previous session and allows patients to fit in visits to the hospital to receive treatment around their personal and professional lives. Many studies

use shorter intervals of between 1 and 2 weeks, while the energies used are lower and recurrence rates higher.<sup>1,5,9,14</sup>

Most studies use noncoherent light sources, generally red and/or blue light, or intense pulsed light.<sup>12,18,24</sup> Our reason for using pulsed dye laser was not only to focus the energy on the diseased areas but also to reduce inflammation and improve scarring.<sup>4,5,20</sup> As reported by Alexiades-Armenakas,<sup>25</sup> the fluence required for the pulsed dye laser to be effective is between 7 and 7.5 J/cm<sup>2</sup>. We used a higher fluence in order to ensure efficacy (9 J/cm<sup>2</sup>); this also provided good tolerability with few side effects, as it was associated with a pulse width of 6 ms in order to prevent potential abnormal pigmentation or purpura, and is also less painful for the patient. Only 1 previous trial has been published that uses pulsed dye laser with MAL for PDT in acne<sup>13</sup>; in our study, we used a higher fluence and a shorter pulse. We also needed to use a greater number of sessions to achieve similar results in terms of efficacy in the reduction of inflammatory lesions.

The use of MAL as a photosensitizing agent may, due to its lipophilic nature, provide advantages over ALA, as it presents better penetration properties and greater tissue selectivity. It appears that this selectivity, which means that MAL is deposited in spots and not homogeneously, as occurs with ALA, results in less severe pain during treatment and fewer adverse effects.<sup>14</sup> Fritsch et al<sup>17</sup> compared the intensity of fluorescence and production in situ of porphyrins with ALA and MAL in 80 patients, 40 of whom had normal skin and the rest actinic keratosis. Those authors found that fluorescence in normal skin was lesser with MAL and that porphyrin production in the areas with actinic keratosis was twice as high with ALA as with MAL. They therefore concluded that ALA appears to be a more efficient producer of porphyrins, leading to a greater photodynamic reaction than with MAL. Nevertheless, they concur with Christiansen et al<sup>26</sup> in that production of PpIX due to ALA is excessive for cosmetic indications. With regard to the incubation time for MAL, we concur with other authors regarding the possibility of using short periods, although we determined that it was necessary to maintain the photosensitizing agent in contact with the treatment area for at least 1 hour. When we used an incubation time of 45 minutes, we did not obtain the red-orange coral-like fluorescence typical of the accumulation of PpIX or achieve a therapeutic effect. The skin of the treated area did not show either the erythema or edema typically observed when a photodynamic reaction takes place. Although few controlled trials have been carried out that evaluate the use of short incubation times for the photosensitizing agent (between 15 and 20 minutes), we established that this period should be at least 1 hour.<sup>22,27,28</sup> Haedersdal et al<sup>29</sup> performed an evidence-based review of the use of laser, light sources and PDT in the treatment of acne, and found that, in studies on PDT, efficacy and level of pain following treatment were similar using ALA and MAL, whereas erythema, pustular eruptions, and exfoliation were more intense when ALA was used than when MAL was used. Those authors also found that, in most studies, efficacy was greater and was maintained for longer when 4 treatments were used, compared to a single treatment session.

In terms of clinical efficacy, we obtained a statistically significant reduction in the total number of lesions and in the number of inflammatory and noninflammatory lesions, both with laser treatment alone and with PDT. With the application of laser alone, the percentages of reduction of the total number of lesions, inflammatory lesions and noninflammatory lesions were 21.94%, 17.05%, and 29.25%, respectively. However, when both therapies were compared, PDT was only superior to laser with statistical significance ( $P=.002$ ) with respect to the total number of acne lesions; a reduction of 44.39% was achieved with PDT, whereas application of laser alone achieved a reduction of 21.94%. In the study of inflammatory lesions alone, PDT achieved better results (reduction of 48.97%) than laser (reduction of 17.05%), although the difference was not statistically significant ( $P=.133$ ). Similarly, the reduction in noninflammatory lesions was greater with PDT (33.42%) than with laser (29.25%), but without statistical significance ( $P=.229$ ). However, as in previous studies in the literature, we consider that it is difficult to count noninflammatory lesions due to the course of these lesions, which may increase in number before starting treatment, without being associated with the start of treatment.<sup>16</sup> It should also be taken into account that the number of noninflammatory lesions is often small. Our results agree with those obtained in 4 trials in which MAL was used in PDT in acne and reductions were achieved principally in the inflammatory lesions.<sup>5,13,14,16</sup> However, the differences between the application of laser alone and PDT are small, as in the other studies, and the differences observed were only statistically significant when the total number of lesions was taken into account. Greater improvement was achieved in inflammatory lesions than in noninflammatory lesions both with laser and with PDT, as has been observed in previous studies. In our case, however, the difference in the results between laser and PDT was not statistically significant.

As in the studies by Fritsch et al<sup>30</sup> and by Wiegell and Wulf,<sup>5</sup> we observed greater fluorescence in the areas of skin affected by inflammatory acne than in the perilesional skin, indicating the greater selectivity of MAL for diseased skin, as it accumulates selectively in the inflamed sebaceous glands, where it also causes a greater accumulation of PpIX. As with Haedersdal et al,<sup>13</sup> we observed fluorescence in the side pretreated with MAL, compared to the contralateral side. In our study, we found that, as in other trials reported in the literature, the lack of fluorescence was maintained for longer when multiple sessions were used than when a single treatment was administered. However, although the exact mechanism of PDT in acne has not been demonstrated, it is probable that PDT, as confirmed by Hongcharu et al,<sup>3</sup> acts not only by means of direct photodynamic destruction of *P. acnes* and direct damage to the sebaceous gland but also by reducing follicular obstruction by causing increased keratinocyte replacement and reduced hyperkeratosis. In terms of evaluation of the colonies of *P. acnes*, although the specific quantitative measurement of bacteria on the skin is, of itself, more precise than indirect measurement using fluorescence, no studies have been published to date that quantify the number of bacteria. The only

exception is the study by Pollock et al,<sup>9</sup> who measured levels of *P. acnes* on the skin surface, although these levels did not correlate exactly with those in the pilosebaceous ducts. Hence, the reduction in fluorescence continues to be the indirect measurement that reflects the reduction in the bacterial count. This fluorescence was found to reappear several weeks after the end of PDT, which may confirm the possibility of recolonization. The data reported in the literature and the results of our study indicate that the lack of fluorescence is maintained for longer when multiple sessions are used, compared to a single treatment session.

No patients abandoned the study due to a lack of tolerance of the treatment. The evaluation of adverse effects allows us to establish that PDT is a safe treatment. In terms of pain, patients reported a tingling and burning sensation, which they defined on a scale of 1 to 6 (1, no pain; 2, mild pain; 3, moderate pain; 4, severe pain; 5, very severe pain; 6 did not know or did not answer). Almost half of the patients reported no pain during treatment with either laser or PDT. The remaining 54% of patients, who did report feeling pain, reported mild to moderate pain (levels 2-3). The pain that manifests during PDT is known to be restricted to the illuminated area and may be a reflection of nerve stimulation and/or tissue damage caused by oxygen free radicals and probably made worse by hyperthermia. It appears that MAL may cause less stimulation of the nerve fibers and, as a result, induce less pain.<sup>31</sup> In fact, previous studies have shown that PDT in healthy skin is more painful with ALA than with MAL; this is because the accumulation of PpIX is greater after incubation of ALA than with MAL. Wiegell and Wulf<sup>16</sup> showed differences in levels of pain with ALA and with MAL when treating normal skin. However, this difference is not observed when treating diseased skin; this is because, although MAL induces accumulation in spots rather than homogeneously, the activation of large quantities of PpIX in a spot may be as painful as the activation of a treatment area with a more homogeneous distribution of PpIX, as occurs with ALA. This explains the fact that, in patients with acne treated with MAL, as in our study, pain is mild or nonexistent because the areas treated in these patients include large areas of healthy skin in comparison with the overall extent of the lesions. On the other hand, we can postulate that the use of ALA in PDT to treat acne would induce more severe pain because a greater area of healthy skin would be treated compared to lesional skin, so that the homogeneous accumulation of PpIX in the perilesional skin would cause more pain during the application of light, whereas with MAL, the accumulation of PpIX only occurs in spots in the lesions. In a recent study, Wiegell et al<sup>32</sup> observed pain during PDT with MAL for the treatment of actinic keratosis and of acne; the authors showed that the pain was greater in association with higher peaks of fluorescence due to PpIX and also with higher ranges of fluence. Two previous studies reported less pain in PDT with MAL compared to PDT with ALA in the treatment of actinic keratosis of the scalp, although shorter incubation times were used with MAL than with ALA.<sup>33,34</sup> Recently, Wiegell and Wulf,<sup>16</sup> in a study of PDT in acne, and Kuijpers et al,<sup>35</sup> in the

treatment of nodular basal cell carcinoma, found that the application of both prodrugs, with an incubation period of 3 hours, produced no significant differences between the 2 agents in terms of levels of pain, although, in the case of acne, treatment with ALA was significantly more painful in the 24 hours following treatment. The level of pain also appears to be linked to the intensity of the light used, so that a fractioned dose of light increases tolerance and, at the same time, appears to improve the cure rate; the same is true for lower fluences.<sup>32,36</sup>

No cases of crusts, desquamation, purpura, or scarring were reported. Only 2 cases of hypopigmentation occurred and these resolved in 3 weeks. Most patients experienced erythema with slight edema immediately after the treatment session; patients reported that these symptoms disappeared during the day and did not affect their daily lives. Specifically, erythema and edema were more severe in the first 10 minutes after the start of PDT and diminished 1 hour after the end of treatment, as described by Hongcharu et al.<sup>3</sup> The pain, burning and itching were also more intense in the first 10 minutes and subsequently reached a plateau. The burning sensation was more intense in subsequent treatments.

The erythema and edema corresponded to the photodynamic effect, indicating therapeutic effectiveness. Patients who did not develop erythema and edema showed a lack of clinical response when they presented for the following treatment session. As in the study by Haedersdal et al,<sup>13</sup> the erythema and edema presented more frequently and more markedly on the PDT side than on the side treated only with laser.

In this study, we show the efficacy of PDT in the treatment of principally inflammatory acne. However, we consider that limitations may arise from the development of the technique and we concur with other studies regarding the need to optimize treatment regimens in order to obtain results that are maintained over time, with few adverse effects. We believe that the use of PDT and other types of phototherapy should not be considered a substitute for treatment with antibiotics or retinoids.

## Conclusions

The conclusions of this study, in which we describe our experience of the use of laser and PDT in the treatment of acne, are the following:

1. PDT, using MAL and long-pulse pulsed dye laser, is an effective treatment for predominantly inflammatory acne.
2. PDT may be considered a harmless technique for the treatment of acne, due to the near total lack of adverse effects.
3. PDT, using MAL and long-pulse pulsed dye laser, achieves better results than pulsed dye laser in the treatment of acne, principally in inflammatory lesions.

Since this study was carried out, new data has been published in the literature on the use of PDT in acne vulgaris.<sup>37-43</sup>

## Conflict of Interest

The authors declare no conflicts of interest.

## References

1. Gold MH, Bradshaw VL, Boring MM. The use of a novel intense pulsed light and heat source and ALA-PDT in the treatment of moderate to severe inflammatory acné vulgaris. *J Drugs Dermatol.* 2004;3:S15-9.
2. Divaris DX, Kennedy JC, Pottier RH. Phototoxic damage to sebaceous glands and hair follicles of mice after systemic administration of 5-aminolevulinic acid correlates with localized protoporphyrin IX fluorescence. *Am J Pathol.* 1990;136:891-7.
3. Hongcharu W, Taylor CR, Chang Y. Topical ALA-photodynamic therapy for the treatment of acné vulgaris. *J Invest Dermatol.* 2000;115:183-92.
4. Charakida A, Seaton ED, Charakida M. Phototherapy in the treatment of acné vulgaris: what is its role? *Am J Clin Dermatol.* 2004;5:211-6.
5. Wiegell SR, Wulf HC. Photodynamic therapy of acné vulgaris using methyl aminolaevulinat: a blinded, randomized, controlled trial. *Br J Dermatol.* 2006;154:969-76.
6. Futsaether CM, Kjeldstad B, Johnsson A. Intracellular pH changes induced in *Propionibacterium acnes* by UVA radiation and blue light. *J Photochem Photobiol B.* 1995;31:125-31.
7. Bhardwaj SS, Rohrer TE, Arndt K. Lasers and light therapy for acné vulgaris. *Semin Cutan Med Surg.* 2005;24:107-12.
8. Yung A, Stables GI, Fernandez C. Microbiological effect of photodynamic therapy (PDT) in healthy volunteers: a comparative study using methyl aminolaevulinat and hexyl aminolaevulinat cream. *Clin Exp Dermatol.* 2007;32:716-21.
9. Pollock B, Turner D, Stringer MR. Topical aminolaevulinic acid-photodynamic therapy for the treatment of acné vulgaris: a study of clinical efficacy and mechanism of action. *Br J Dermatol.* 2004;151:616-22.
10. Alster TS, Surin-Lord SS. Photodynamic therapy: practical cosmetic applications. *J Drugs Dermatol.* 2006;5:764-8.
11. Ross EV. Optical treatments for acné *Dermatol Ther.* 2005; 18:253-66.
12. Nestor MS, Gold MH, Kauvar AN. The use of photodynamic therapy in dermatology: results of a consensus conference. *J Drugs Dermatol.* 2006;5:140-54.
13. Haedersdal M, Togsverd-Bo K, Wiegell SR. Long-pulsed dye laser versus long-pulsed dye laser-assisted photodynamic therapy for acné vulgaris: A randomized controlled trial. *J Am Acad Dermatol.* 2008;58:387-94.
14. Horfelt C, Funk J, Frohm-Nilsson M. Topical methyl aminolaevulinat photodynamic therapy for treatment of facial acné vulgaris: results of a randomized, controlled study. *Br J Dermatol.* 2006;155:608-13.
15. Fernández-Guarino M, García-Morales I, Harto A. Photodynamic therapy: new indications. *Actas Dermosifiliogr.* 2007;98: 377-95.
16. Wiegell SR, Wulf HC. Photodynamic therapy of acné vulgaris using 5-aminolevulinic acid versus methyl aminolevulinat. *J Am Acad Dermatol.* 2006;54:647-51.
17. Fritsch C, Homey B, Stahl W. Preferential relative porphyrin enrichment in solar keratoses upon topical application of delta-aminolevulinic acid methylester. *Photochem Photobiol.* 1998;68:218-21.
18. Mariwalla K, Rohrer TE. Use of lasers and light-based therapies for treatment of acné vulgaris. *Lasers Surg Med.* 2005;37: 333-42.

19. Seaton ED, Charakida A, Mouser PE. Pulsed-dye laser treatment for inflammatory acne vulgaris: randomised controlled trial. *Lancet*. 2003;362:1347-52.
20. Ortiz A, Van VM, Lask GP, Yamauchi PS. A review of lasers and light sources in the treatment of acne vulgaris. *J Cosmet Laser Ther*. 2005;7:69-75.
21. Harto A, Garcia-Morales I, Belmar P, Jaen P. Pulsed dye laser treatment of acne. Study of clinical efficacy and mechanism of action. *Actas Dermosifiliogr*. 2007;98:415-9.
22. Yeung CK, Shek SY, Bjerring P. A comparative study of intense pulsed light alone and its combination with photodynamic therapy for the treatment of facial acne in Asian skin. *Lasers Surg Med*. 2007;39:1-6.
23. Itoh Y, Ninomiya Y, Tajima S, Ishibashi A. Photodynamic therapy for acne vulgaris with topical 5-aminolevulinic acid. *Arch Dermatol*. 2000;136:1093-5.
24. Uebelhoefer NS, Dover JS. Photodynamic therapy for cosmetic applications. *Dermatol Ther*. 2005;18:242-52.
25. Alexiades-Armenakas M. Laser-mediated photodynamic therapy. *Clin Dermatol*. 2006;24:16-25.
26. Christiansen K, Bjerring P, Troilius A. 5-ALA for photodynamic photorejuvenation--optimization of treatment regime based on normal-skin fluorescence measurements. *Lasers Surg Med*. 2007;39:302-10.
27. Rojanamatin J, Choawawanich P. Treatment of inflammatory facial acne vulgaris with intense pulsed light and short contact of topical 5-aminolevulinic acid: a pilot study. *Dermatol Surg*. 2006;32:991-6.
28. Taub AF. Photodynamic therapy for the treatment of acne: a pilot study. *J Drugs Dermatol*. 2004;3:S10-4.
29. Haedersdal M, Togsverd-Bo K, Wulf HC. Evidence-based review of lasers, light sources and photodynamic therapy in the treatment of acne vulgaris. *J Eur Acad Dermatol Venereol*. 2008;22:267-78.
30. Fritsch C, Verwohlt B, Bolsen K. Influence of topical photodynamic therapy with 5-aminolevulinic acid on porphyrin metabolism. *Arch Dermatol Res*. 1996;288:517-21.
31. Rud E, Gederaas O, Hogset A, Berg K. 5-aminolevulinic acid, but not 5-aminolevulinic acid esters, is transported into adenocarcinoma cells by system BETA transporters. *Photochem Photobiol*. 2000;71:640-7.
32. Wiegell SR, Skiveren J, Philipsen PA, Wulf HC. Pain during photodynamic therapy is associated with protoporphyrin IX fluorescence and fluence rate. *Br J Dermatol*. 2008;158:727-33.
33. Moloney FJ, Collins P. Randomized, double-blind, prospective study to compare topical 5-aminolevulinic acid methylester with topical 5-aminolevulinic acid photodynamic therapy for extensive scalp actinic keratosis. *Br J Dermatol*. 2007;157:87-91.
34. Kasche A, Luderschmidt S, Ring J, Hein R. Photodynamic therapy induces less pain in patients treated with methyl aminolevulinate compared to aminolevulinic acid. *J Drugs Dermatol*. 2006;5:353-6.
35. Kuijpers DJ, Thissen MR, Thissen CA, Neumann MH. Similar effectiveness of methyl aminolevulinate and 5-aminolevulinate in topical photodynamic therapy for nodular basal cell carcinoma. *J Drugs Dermatol*. 2006;5:642-5.
36. Ericson MB, Sandberg C, Stenquist B. Photodynamic therapy of actinic keratosis at varying fluence rates: assessment of photobleaching, pain and primary clinical outcome. *Br J Dermatol*. 2004;151:1204-12.
37. Riddle CC, Terrell SN, Menser MB. A review of photodynamic therapy (PDT) for the treatment of acne vulgaris. *J Drugs Dermatol*. 2009;8:1010-9.
38. Fadel M, Salah M, Samy N, Mona S. Liposomal methylene blue hydrogel for selective photodynamic therapy of acne vulgaris. *J Drugs Dermatol*. 2009;8:983-90.
39. De Leeuw J, van der Beek N, Bjerring P. Photodynamic therapy of acne vulgaris using 5-aminolevulinic acid 0.5% liposomal spray and intense pulsed light in combination with topical keratolytic agents. *J Eur Acad Dermatol Venereol*. 2010;24(4):460-9.
40. Oh SH, Ryu DJ, Han EC, Lee KH, Lee JH. A Comparative Study of Topical 5-Aminolevulinic Acid Incubation Times in Photodynamic Therapy with Intense Pulsed Light for the Treatment of Inflammatory Acne. *Dermatol Surg*. 2009;35(12):1918-26.
41. Fabbrocini G, Cacciapuoti S, De Vita V, Fardella N, Pastore F, Monfrecola G. The Effect of Aminolevulinic Acid Photodynamic Therapy on Microcomedones and Macrocomedones. *Dermatology*. 2009;219(4):322-8.
42. Hörfelt C, Stenquist B, Halldin CB, Ericson MB, Wennberg AM. Single low-dose red light is as efficacious as methylaminolevulinate--photodynamic therapy for treatment of acne: clinical assessment and fluorescence monitoring. *Acta Derm Venereol*. 2009;89:372-8.
43. Passeron T, Khemis A, Ortonne JP. Pulsed dye laser-mediated photodynamic therapy for acne inversa is not successful: A pilot study on four cases. *J Dermatolog Treat*. 2009;1:1-2.