

ACTAS Dermo-Sifiliográficas

Full English text available at
www.elsevier.es/ad



CASE FOR DIAGNOSIS

Episodes of Flushing and Blistering

Episodios de flushing y ampollas

Medical History

The patient was a 21-month-old boy who was seen in our outpatient clinic on referral from the emergency department of our hospital. He was diagnosed with atopic dermatitis and was on treatment with levocetirizine. His family stated that during the previous year he had had recurrent episodes of facial flushing with the appearance over the following hours of bullous lesions that covered the whole body; the frequency of the episodes varied between 2 to 3 a day to 2 to 3 a month. They also reported 3 episodes of somnolence and laxity immediately after the episode of flushing, but no other systemic symptoms.

Physical Examination

Multiple vesicular-bullous lesions containing a clear fluid were observed on the trunk, face, and scalp. The rest of the skin was slightly thickened and presented intense dermographism. There were no palpable lymph nodes or organomegaly (Figures 1 and 2).

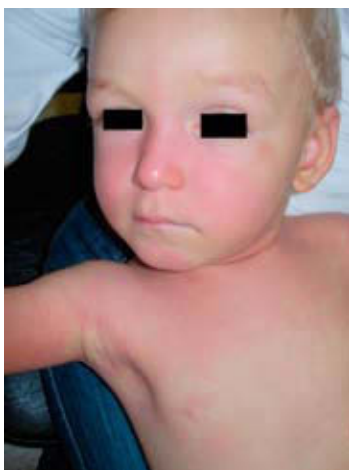

Figure 1

Histopathology

Biopsy, performed under local anesthesia with bupivacaine, showed skin with an intense, diffuse monomorphic infiltrate in the dermis. The inflammatory cells had a granular cytoplasm and stained strongly positive with Giemsa stain (Figure 3).

Additional Tests

The other tests, including biochemistry, complete blood count, quantification of immunoglobulin E, and protein electrophoresis, were rigorously normal.

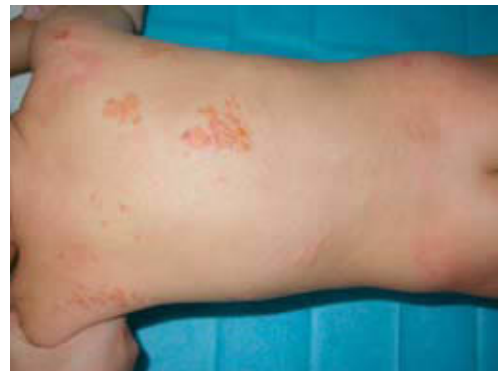

Figure 2

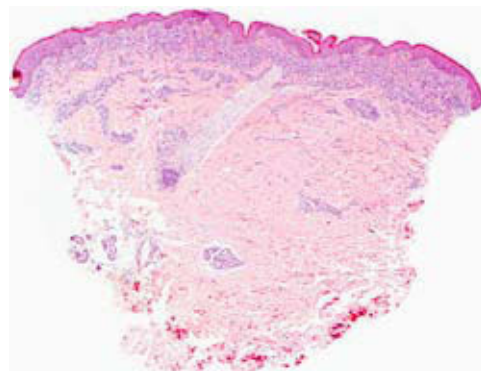


Figure 3 Hematoxylin-eosin, original magnification $\times 100$.

What Is Your Diagnosis?

Diagnosis

After excluding systemic disease and taking into account the clinical and histological data, our patient was diagnosed with diffuse cutaneous mastocytosis. A test that must be performed in these patients prior to treatment is the serum trypsin concentration. In our patient the result was 18.2 µg/L, which was high for his age (in adults it is considered abnormal above 20 µg/L). C-kit mutation was negative in the skin biopsy.

Clinical Course and Treatment

We prescribed cetirizine, ranitidine, dexchlorpheniramine, and oral and topical disodium chromoglycate, achieving a rapid and marked improvement of symptoms that was maintained at follow-up 18 months later. The patient experienced a temporary deterioration after 1 year of treatment, but that resolved after adjusting the dose of the medication to the child's weight. Follow-up includes annual repetition of trypsin measurement, which, in our patient, fell to 15 µg/L.

Comment

Pediatric mastocytosis usually only affects the skin and tends to be transitory. In adults it is considered that the majority of cases are provoked by point mutations of codon 816 in genes that code for c-kit; this is less common in children.¹ Diffuse cutaneous mastocytosis is a rare form of mastocytosis, characterized by diffuse involvement of the skin, with mast cell infiltration throughout the dermis. Patients are often asymptomatic at birth, but soon afterwards develop mild thickening of the skin with a texture similar to that of orange peel. Pruritus and blister formation are common and are associated with episodes of flushing (the symptoms usually resolve by 3 years of age).² This very intense mast cell infiltration produces more marked systemic symptoms (due to mast cell degranulation and mediator release).³

Clinical methods are available to evaluate the severity of the mastocytosis; the most widely used is the scoring mastocytosis (SCORMA) index, which is based on a qualitative

and quantitative analysis of various features of the disease.⁴ In the literature we found numerous references to a higher rate of transformation of diffuse cutaneous mastocytosis into a systemic disorder. The reality is that, after an in-depth review of the literature, we found only 1 case of diffuse cutaneous mastocytosis that progressed to a systemic disease, but there was no information about the clinical course.

The presentation in our patient clearly illustrates the most frequent symptoms, histology, and clinical course of diffuse cutaneous mastocytosis. We would like to draw attention to the nature of this disease. It is considered the most severe form of mastocytosis in children as it is associated with acute episodes of sometimes life-threatening mediator release, which must be considered a true medical emergency, requiring early diagnosis and intensive treatment from the outset.⁵

References

1. Anguloa J, Ruiz de la Parte A, González-Guerra E, Vargas-Machuca I, Fariña MC, Martín L, et al. Mastocytosis del adulto. Descripción de 9 casos clinicopatológicos. *Actas Dermosifiliogr*. 2005;96:231-6.
2. Wolf K, Komar M, Petzelbauer P. Clinical and histopathological aspects of cutaneous mastocytosis. *Leuk Res*. 2001;25:519-28.
3. Briley LD, Phillips CM. Cutaneous mastocytosis: A review focusing on the pediatric population. *Clin Pediatr (Phila)*. 2008;47:757-61.
4. Heide R, Middelkamp Hup MA, Mulder PG, Oranje AP, Mastocytosis Study Group Rotterdam. Clinical scoring of cutaneous mastocytosis. *Acta Derm Venereol*. 2001;81:273-6.
5. Golitz LE, Weston WL, Lane AT. Bullous mastocytosis: Diffuse cutaneous mastocytosis with extensive blisters mimicking scalded skin syndrome or erythema multiforme. *Pediatr Dermatol*. 1984; 1:288-94.

L. Fuertes,* C. Zarco, and F. Vanaclocha

Servicio de Dermatología, Hospital 12 de Octubre, Madrid, Spain

*Corresponding author.

E-mail address: cottonmouth_g@hotmail.com (L. Fuertes).