

## Systemic Cryptococcosis Presenting as Extensive Cellulitis in a Patient With Rheumatoid Arthritis

### Celulitis diseminada como presentación inicial de criptococosis sistémica en un paciente con artritis reumatoide

to the Editor:

Cryptococcosis is an infection caused by the encapsulated yeast *Cryptococcus neoformans*; the typical route of entry is by inhalation, although it tends to spread via the blood, and mainly affects the central nervous system, bone, and skin. The manifestations in the skin can develop due to dissemination (secondary form) or, rarely, by direct inoculation of contaminated material (primary form).<sup>1</sup> Clinically, the lesions can be highly varied, presenting as papules, pustules, infiltrating nodules that ulcerate, lesions that resemble molluscum contagiosum or, rarely, as cellulitis.<sup>2</sup>

We describe the case of an 80-year-old patient with a 20-year history of rheumatoid arthritis, and who had received treatment for several years with methotrexate 7.5 mg/wk and methylprednisolone 12 mg/d. One month before admission, the dose of methylprednisolone had been increased to 20 mg/d due to worsening of joint pain. Other important aspects of the patient's history included bilateral knee prostheses, chronic kidney failure, and anemia of multifactorial origin. The patient was admitted for pain and edema in the left leg that had started 10 days earlier and empirical antibiotic treatment was started with amoxicillin-clavulanic acid. During his admission, the patient developed fever and the condition of his leg began to deteriorate. Examination showed edematous, erythematous-violaceous plaques and tense blisters that rapidly became more extensive, affecting both legs, the back, and right arm (Figures 1 and 2), while sparing the perineum. Deep vein thrombosis was ruled out by echo-Doppler. In view of the persistence of the fever, antibiotic cover was increased by the administration of piperacillin, tazobactam, and teicoplanin. Skin biopsy was also performed, with pathological findings of moderate edema of the dermis with slightly dilated vessels and the presence

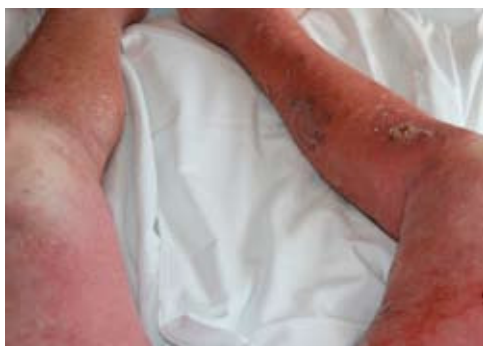

Figure 1 Erythematous plaques affecting both legs.

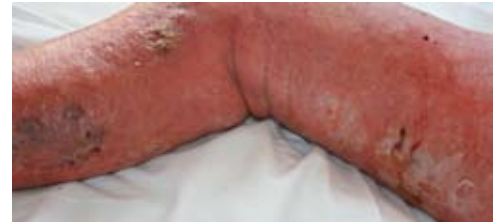

Figure 2 Edematous erythematous plaque with blisters, erosions, and ecchymoses on the right leg.

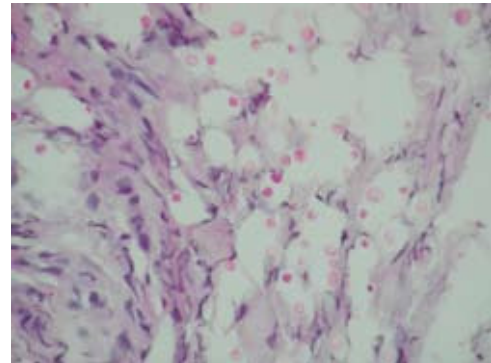


Figure 3 Rounded structures in the dermis which were positive on silver-methenamine staining (Silver-methenamine,  $\times 40$ ).

of polymorphonuclear leukocytes. Some rounded structures were also observed in the dermis that were positive on periodic acid-Schiff and silver-methenamine staining (Figure 3). We also performed culture of an aspirate from a blister, and skin, blood and cerebrospinal fluid cultures, isolating colonies of *Cryptococcus neoformans*. The microorganism was first isolated from the skin aspirate, and treatment was immediately started with liposomal amphotericin, but despite this the patient deteriorated, with progression of the skin lesions, anasarca, multiorgan failure, and finally death.

*Cryptococcus neoformans* is an opportunistic encapsulated yeast. The most common form of exposure to this fungus is by inhalation from soil particles contaminated by pigeon droppings, or from decaying fruit, vegetables, or wood.<sup>3</sup> Cryptococcal skin infection usually occurs by hematogenous spread; approximately 15% of the patients with systemic dissemination present secondary skin disease.<sup>2,4</sup>

Patients with AIDS, lymphoma, or sarcoidosis, or on treatment with immunosuppressive drugs are more susceptible to infection by *Cryptococcus neoformans*, although cases have also been reported in immunocompetent patients, particularly with primary cutaneous cryptococcosis, which has a better prognosis.<sup>5,6</sup>

From a clinical point of view, the skin disease can give rise to ulcers, plaques, pustules, subcutaneous nodules, ecchymoses, granulomas, abscesses, cellulitis and, more rarely, necrotizing vasculitis.<sup>7</sup>

In the literature there are only 3 reports of similar cases of patients with rheumatoid arthritis in whom the initial manifestation of disseminated cryptococcosis was

cellulitis; 2 were on treatment with corticosteroids<sup>2,5</sup> and 1 with infliximab.<sup>8</sup>

The treatment of choice is intravenous amphotericin-B, with or without oral flucytosine, although fluconazole and itraconazole are also currently used as alternatives to amphotericin-B as they are equally effective but have fewer adverse effects.<sup>9</sup>

In conclusion, cellulitis caused by *Cryptococcus neoformans* is an infrequent presentation of cryptococcosis in immunosuppressed patients and is clinically indistinguishable from bacterial cellulitis. Cellulitis can be the primary manifestation of cryptococcal infection or even the first manifestation of disseminated cryptococcosis, as in our patient; we must therefore rule out hematogenous dissemination and begin immediate antifungal treatment. Cellulitis in an immunosuppressed patient with disseminated disease or involvement of several anatomic sites should suggest a possible opportunistic microorganism as the etiologic agent. Disseminated cryptococcosis is usually fatal if appropriate treatment is not administered. Thus, mycological culture and skin biopsy revealing the characteristic microorganisms will help to guide us toward the correct pharmacological treatment, leading to improvements in the patient's prognosis.

## References

1. Bauzá A, Redondo P, Rubio M. Primary cutaneous cryptococcal cellulitis secondary to insect bite in an immunosuppressed patient after liver transplantation. *Clin Exp Dermatol*. 2005;30:241-3.
  2. Lu HC, Yang YY, Huang YL, Chen TL, Chuang CL, Lee FY, et al. Disseminated cryptococcosis initially presenting as cellulitis in a rheumatoid arthritis patient. *J Chin Med Assoc*. 2007;70:249-52.
  3. Posada C, de la Torre C, González-Sixto B, Cruces MJ. Criptococosis cutánea primaria en paciente oncológico siguiendo un patrón esporotricóide. *Actas Dermosifiliogr*. 2009;100:78-80.
  4. Hafner C, Linde HJ, Vogt T, Breindl G, Tintelnot K, Koellner K, et al. Primary cutaneous cryptococcosis and secondary antigenemia in a patient with long-term corticosteroid therapy. *Infection*. 2005;33:86-9.
  5. Moosbrugger EA, Adams BB, Kralovic SM. Cutaneous cryptococcosis in a patient on corticosteroid therapy for rheumatoid arthritis. *Int J Dermatol*. 2008;47:630-2.
  6. Neuville S, Dromer F, Morin O, Dupont B, Ronin O, Lortholary O, French Cryptococcosis Study Group. Primary cutaneous cryptococcosis: a distinct clinical entity. *Clin Infect Dis*. 2003;36:337-47.
  7. Sico JJ, Hughes E. Necrotising cryptococcal vasculitis in an HIV-negative woman. *Mycoses*. 2006;49:152-4.
  8. Kozic H, Riggs K, Ringpfeil F, Lee JB. Disseminated *Cryptococcus neoformans* after treatment with infliximab for rheumatoid arthritis. *J Am Acad Dermatol*. 2008;58(Suppl 1):S95-6.
  9. Sánchez-Albisua B, Rodríguez-Peralto JL, Romero G, Alonso J, Vanaclocha F, Iglesias L. Cryptococcal cellulitis in an immunocompetent host. *J Am Acad Dermatol*. 1997;36:109-12.
- C. Diaz-Sarrió,<sup>a,\*</sup> X. García-Navarro,<sup>a</sup> G. Claver-Cercós,<sup>b</sup> J.M. Baucells-Azcona,<sup>b</sup> C. Martín-Plata,<sup>c</sup> and M. Corcoy-Grabalosa<sup>d</sup>
- <sup>a</sup>Servicio de Dermatología, Consorci Sanitari Garraf, Hospital Sant Camil, Sant Pere de Ribes, Barcelona, Spain  
<sup>b</sup>Servicio de Medicina Interna, Consorci Sanitari Garraf, Hospital Sant Camil, Sant Pere de Ribes, Barcelona, Spain  
<sup>c</sup>Servicio de Anatomía Patológica, Consorci del Laboratori Intercomarcal de l'Alt Penedès, l'Anoia i el Garraf, Barcelona, Spain  
<sup>d</sup>Servicio de Microbiología, Consorci del Laboratori Intercomarcal de l'Alt Penedès, l'Anoia i el Garraf, Barcelona, Spain
- \*Corresponding author.  
 E-mail: carmediatz@eresmas.net (C. Diaz-Sarrió).

## Rat-bite Fever: A Case in Spain With Skin Lesions

### Fiebre por mordedura de rata. Un caso en España con lesiones cutáneas características

To the Editor:

Rat-bite fever is a zoonosis of worldwide distribution produced by *Streptobacillus moniliformis* or *Spirillum minus* that colonize the rodent oropharynx. These are transmitted by percutaneous inoculation, although the *S. moniliformis* may also be transmitted by the ingestion of food contaminated with excrement, a condition known as Haverhill fever or *erythema arthriticum epidemicum*.<sup>1,2</sup> *S. minus* is only found in Asia and produces disorder known as Sodoku, with fever, inflammatory changes in the area of the bite, and regional lymphangitis.<sup>2</sup>

In Spain the true incidence and prevalence of this illness is unknown. There are historical references to this condition

dating from 1947,<sup>3,4</sup> but only 6 cases have been documented in more recent times (3 arthritis, 1 subcutaneous abscess, and 2 bacteremias).<sup>5-7</sup>

We present the case of a 50-year-old male with mitral insufficiency secondary to subacute endocarditis, who consulted for a 10-day history of general malaise and fever, associated with diarrhea that resolved after a week. On the sixth day, lesions appeared on the hands; the lesions were initially papular and painful but progressed to pustules and also developed on the face and distal third of the legs. The patient also presented migratory arthralgias in the interphalangeal joints of the right hand and left knee, as well as odynophagia.

Elements of epidemiological interest in the past history included a visit to rural areas of Canada and Germany two months earlier, and the patient had been bitten by a wild rat 15 days earlier while working in the countryside. He reported no high-risk sexual practices.

On admission the patient presented a temperature of 39°C, he was hemodynamically stable, and there was a systolic murmur that radiated to the axilla.