

ACTAS Dermo-Sifiliográficas

Full English text available at
www.elsevier.es/ad



CASE REPORT

Nelson Syndrome: A Rare Cause of Generalized Hyperpigmentation of the Skin

R. Barabash,* F.G. Moreno-Suárez, L. Rodríguez, A.M. Molina, and J. Conejo-Mir

Servicio de Dermatología, Hospitales Universitarios Virgen del Rocío, Sevilla, Spain

Received February 3, 2009; accepted April 30, 2009

KEYWORDS

Nelson syndrome;
Hyperpigmentation;
Adrenalectomy

PALABRAS CLAVE

Síndrome de Nelson;
Hiperpigmentación;
Suprarrenalectomía

Abstract

Nelson syndrome is a rare cause of generalized mucocutaneous hyperpigmentation. Its clinical manifestations are due to excessive secretion of adrenocorticotrophic hormone from a pituitary adenoma, which develops after bilateral therapeutic adrenalectomy. As this operation has fallen into disuse, Nelson syndrome is now extremely rare and difficult to recognize. We present a very severe case of generalized hyperpigmentation due to Nelson syndrome in a 37-year-old woman.

© 2009 Elsevier España, S.L. and AEDV. All rights reserved.

Aspectos prácticos de la quinacrina como tratamiento del lupus eritematoso cutáneo: serie de casos

Resumen

El síndrome de Nelson (SN) supone una causa infrecuente de hiperpigmentación mucocutánea generalizada, cuyas manifestaciones clínicas se derivan de la secreción excesiva de corticotropina por un adenoma hipofisario secundario a la realización de una suprarrenalectomía bilateral terapéutica. Debido a que esta intervención quirúrgica ha caído en desuso en la actualidad, su presentación es hoy sumamente rara y poco reconocible. Presentamos un caso muy grave de hiperpigmentación generalizada por SN en una paciente de 37 años.

© 2009 Elsevier España, S.L. y AEDV. Todos los derechos reservados.

Introduction

Nelson syndrome refers to a set of clinical manifestations caused by hypersecretion of adrenocorticotrophic hormone (ACTH) by a pituitary adenoma which develops after

bilateral therapeutic adrenalectomy to treat Cushing disease.^{3,4} In 1958 Nelson described the first case of this disorder,^{1,2} which is an extremely rare cause of generalized skin hyperpigmentation.

Clinically, the syndrome is characterized by mucocutaneous hyperpigmentation caused by α -melanocyte-stimulating hormone (MSH). Both MSH and ACTH rise simultaneously, as both are derived from a precursor peptide commonly designated proopiomelanocortin (POMC).

*Corresponding author.

E-mail address: romanbarabash@hotmail.com (R. Barabash).

Because bilateral adrenalectomy is the last therapeutic option in patients with Cushing disease who have not responded to other measures, Nelson syndrome is now extremely uncommon.^{5,17} We describe a rare, very severe case in a 37-year-old woman.

Case Description

A 37-year-old white woman with no relevant personal or family history was referred to our outpatient clinic for generalized, progressive, and very pronounced increase in mucocutaneous pigmentation, to the point that she resembled a person of black race.

At age 27 the patient had initiated with severe headache and diplopia. The study revealed apoplexy of a pituitary macroadenoma. Following transsphenoidal hypophysectomy, she maintained normal hormone levels, and the only symptom was secondary amenorrhea of hypophyseal origin.

At age 30 the patient underwent fertility treatment and developed a clear case of Cushing syndrome with hyperglycemia, hypertension, and characteristic phenotype, accompanied by an increase in ACTH levels (1000 pg/mL). Petrosal sinus catheterization confirmed abnormal ACTH secretion of hypophyseal origin and Cushing disease.

The neurosurgery department ruled out another operation, and therapeutic attempts consisting of stereotactic radiotherapy and hormone replacement therapy were unable to control ACTH hypersecretion by the tumor.

At age 31, the patient underwent therapeutic bilateral adrenalectomy to eliminate the effect of ACTH on the adrenal glands. The clinical symptoms of Cushing disease gradually disappeared and the ACTH levels increased (1500-1800 pg/mL).

Symptoms of Nelson syndrome started to develop 2 months after the operation. Physical examination showed very intense generalized hyperpigmentation which was more pronounced in areas exposed to sunlight, such as the face, arms, and neck (Figure 1). A brownish-black coloring was also observed on all mucosae, but was particularly noticeable on the labial mucosa, gums, and

hard palate, with scattered brownish macules (Figure 2). Nail pigmentation was also observed (Figure 3).

Histology of an excisional biopsy from the abdominal area showed prominent basal hyperpigmentation and presence of abundant dermal melanophages (Figure 4).

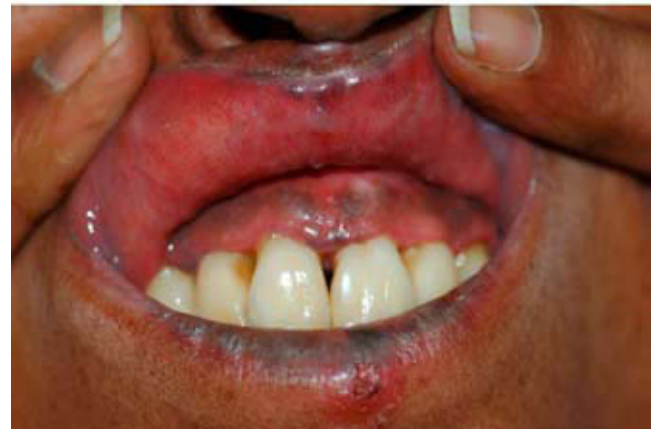
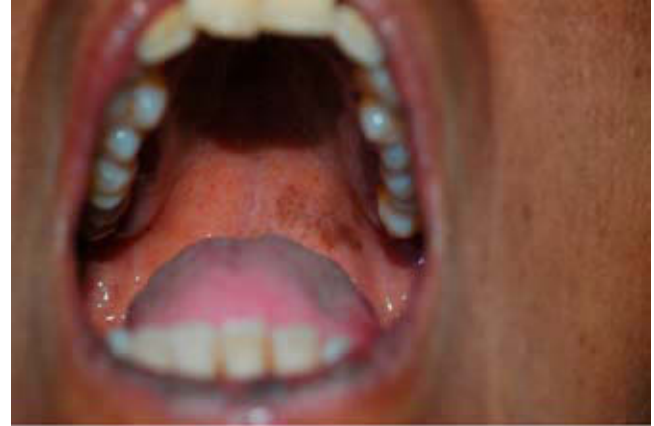
Figure 2 Hyperpigmented macule in palatal mucosa. Mucosal hyperpigmentation.

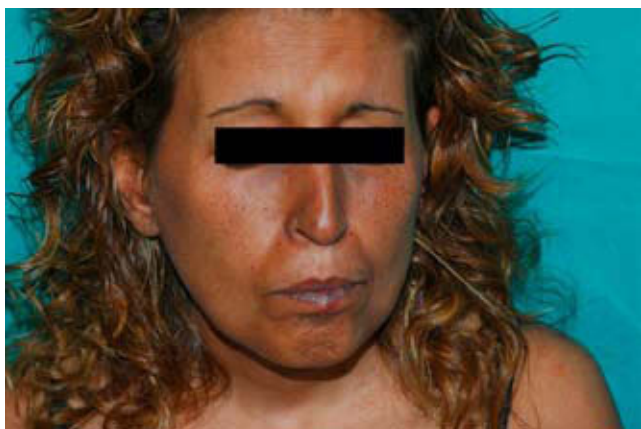

Figure 1 Facial hyperpigmentation.

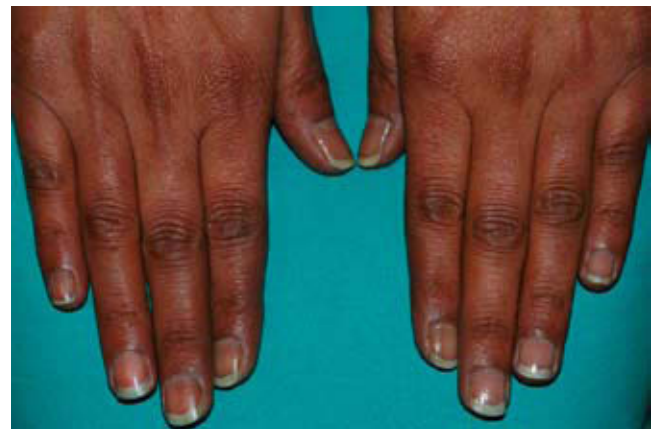

Figure 3 Hyperpigmentation on fingernails and backs of the hands.

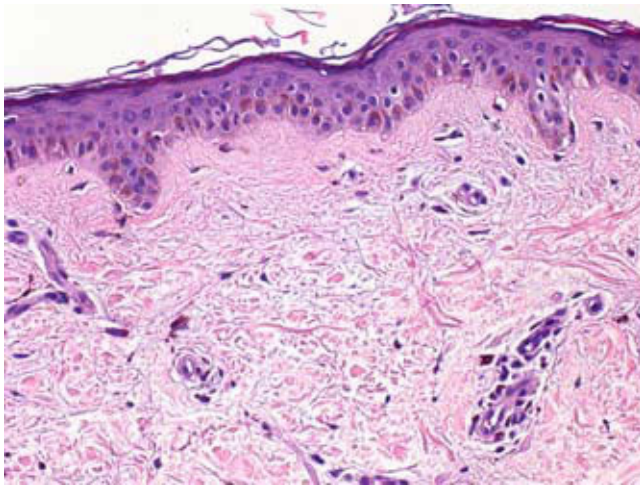


Figure 4 Histologic study showing hyperpigmentation of the basal layer of the epidermis and presence of abundant dermal melanophages (hematoxylin-eosin, $\times 100$).

In addition to hormone replacement therapy with hydrocortisone (20 mg/12 h), levothyroxine (50 $\mu\text{g}/24$ h), cabergoline (2 mg/wk), and lanreotide (120 mg/mo), adequate full sun protection and azelaic acid capsules (500 mg/8 h) were prescribed. After 7 months of treatment, the patient experienced a slight decrease in generalized hyperpigmentation. Despite hormone replacement therapy and stereotactic radiotherapy sessions of the pituitary gland, ACTH levels remained above 1000 pg/mL and, consequently, MSH levels remained elevated.

Discussion

Nelson syndrome is an extremely rare disorder (incidence, 8%-42% of patients who have undergone adrenalectomy^{5,7}) because bilateral adrenalectomy is now performed only very occasionally. The condition is more common among women in the third and fourth decades of life.⁶ It tends to occur 1 to 4 years after therapeutic bilateral adrenalectomy^{3,8} and has an iatrogenic origin.

The syndrome is an unusual cause of diffuse skin hyperpigmentation, and the differential diagnosis should include other conditions that provoke similar skin symptoms, particularly those with hormone disturbances (Table).

The pathophysiology of Nelson syndrome is clearly identified. ACTH is derived from POMC, whose secretion from the pituitary gland is stimulated by hypothalamic corticotropin-releasing hormone (CRH). POMC is also the common peptide precursor of MSH, β -lipotropin, and β -endorphin.⁹ When its levels rise, all derivative hormones also rise and their effects on skin therefore increase. Both ACTH and MSH (α , β , and γ) increase melanogenesis in humans. Because the ACTH molecule contains the MSH amino acid sequence, it stimulates skin pigmentation. On the other hand, α -MSH acts by binding to melanocyte membrane receptors, and its biologic function consists of stimulating melanocyte growth and proliferation, while also favoring melanin synthesis and

dispersion of its granules and thus increasing pigmentation. The other melanocortins, β -MSH and γ -MSH, have much weaker melanin-stimulating activity than α -MSH.

Before therapeutic bilateral adrenalectomy, the cortisol produced by the adrenal glands works to suppress hypothalamic CRH secretion and, consequently, ACTH secretion by the pituitary gland, which keeps serum levels of the hormone and its precursor peptides within normal limits or slightly elevated.¹⁰ The surgical elimination of adrenal secretion also removes the inhibitory effect on the hypothalamus and pituitary gland, and both CRH and ACTH and their effects increase. The result will be evident, generalized hyperpigmentation not limited to (although more severe in) areas exposed to the sun. The degree of pigmentation will depend on the patient's race and α -MSH levels. Hyperpigmentation does take some time to appear and is reported in only 42% of patients in recent series.⁷ Linear pigmentation from the pubis to the umbilicus (linea nigra) and exaggerated pigmentation of the breast areolas, mucosae, extensor surfaces of the limbs, and previous scars are characteristic.

The diagnosis is based on the cutaneous symptoms, elevated serum ACTH levels, and imaging studies. ACTH levels above 200 pg/mL are considered diagnostic of Nelson syndrome.^{11,12}

At present, treatment varies considerably. Because modern imaging and ACTH measurement techniques can detect small adenomas early, surgery will be the first and most effective therapeutic step. Regardless of whether the procedure is performed by the transsphenoidal route or craniotomy, its success will depend on tumor size and involvement of neighboring structures (cerebral parenchyma, optical apparatus, etc). Complete disappearance of the tumor is achieved in 70% to 80% of operations, with recovery of normal pigmentation in most cases.⁷ A type of stereotactic radiosurgery known as the gamma knife has proven to be successful in pituitary adenomas refractory to other surgical techniques. Transsphenoidal radiotherapy has also shown its usefulness when surgery is contraindicated.^{11,13} Effective pharmacological therapy does not exist, although drugs have been used to lower plasma levels (eg, dopamine antagonists such as bromocriptine and cabergoline and somatostatin analogs^{14,15} such as octreotide and lanreotide), to shrink the tumor (eg, valproic acid¹⁴ and rosiglitazone), and to avoid altering circadian rhythm¹⁶ (eg, 4 doses of hydrocortisone).

Dermatologic treatments in this syndrome alone are not encouraging. Our patient was given azelaic acid (500 mg/8 h) based on literature reports regarding its use.^{18,19} Azelaic acid is a 9-carbon dicarboxylic acid obtained by oxidation of oleic acid with nitric acid. The drug has been used to treat hyperpigmentation disorders from the time in vitro tests showed that it was a competitive inhibitor of tyrosinase, the key enzyme in melanogenesis. Moreover, the drug is nontoxic. It has been used in topical and oral form in various hyperpigmentation disorders, such as melasma, lentigo maligna, or melanoma.²⁰ In our patient, the agent was the only treatment that proved to be effective in reducing the pigmentation of Nelson syndrome without presenting, to date, any kind of adverse effect. Hence, we suggest that the drug should be considered in these cases and in other conditions with generalized skin hyperpigmentation.

Table 1 Diffuse Skin Hyperpigmentation: Differential Diagnosis

	Cutaneous Symptoms	Systemic Symptoms	Type of Pigment	Histologic Site	Laboratory Workup
Addison disease	Generalized pigmentation more pronounced in areas exposed to sunlight, palmar-plantar folds, mucosae, nails, recent scars, and areas exposed to friction On occasions, vitiligo or alopecia areata	Anorexia Weight loss Orthostatic hypotension Abdominal pain	Melanin	↑ Melanin in basal layer of the epidermis Melanophages in superficial dermis	↓ Plasma cortisol ↑ ACTH ↑ MSH Hypoglycemia Hyponatremia Hyperkalemia
Cushing disease	Similar to Addison disease, but less pronounced Skin atrophy Striae Hypertrichosis	Obesity Hypertension Osteoporosis Muscle atrophy Hypogonadism	Melanin	No increase in melanocytes ↑ Melanin in basal layer of the epidermis Melanophages in superficial dermis	↑ Plasma cortisol ↑ ACTH ↑ MSH Hyperglycemia
Nelson syndrome	Similar to Addison disease, but more pronounced	None, due to hormone replacement therapy	Melanin	No increase in melanocytes Melanin in basal layer of the epidermis Melanophages in superficial dermis	↓ Plasma cortisol ↑↑ ACTH ↑↑ MSH Hypoglycemia Hyponatremia Hyperkalemia
Hyperthyroidism (Graves disease)	Similar to Addison disease, but less pronounced and in high phototypes Warm, moist skin Diffuse alopecia	Weight loss Anxiety Weakness Heat intolerance	Melanin	No increase in melanocytes	↑ T3 and T4 ↓ TSH
Hemochromatosis	Grayish pigmentation Rare involvement of mucosae Not related to sun exposure	Weight loss Cirrhosis of the liver Diabetes mellitus Hypogonadism	Hemosiderin	Deposits in basal layer, dermal macrophages, and extracellular matrix in the dermis	

Abbreviations: ACTH, adrenocorticotropic hormone; MSH, melanocyte-stimulating hormone; T3, triiodothyronine; T4, thyroxine; TSH, thyroid-stimulating hormone.

Conflicts of Interest

The authors declare no conflicts of interest.

References

- Nelson DH, Meakin JW, Dealy JB, Matson DD, Emerson K, Thorn GW. ACTH-producing tumor of the pituitary gland. *N Engl J Med*. 1958;259:161-4.
- Hornyak M, Weiss MH, Nelson DH, Couldwell WT. Nelson syndrome: Historical perspectives and current concepts. *Neurosurg Focus*. 2007;23:E12.
- Nagesser SK, Van Seters AP, Kievit J, Hermans J, Krans HM, Van de Velde CJ. Long-term results of total adrenalectomy for Cushing's disease. *World J Surg*. 2000;24:108-13.
- Van Aken MO, Pereira AM, Van den Berg G, Romijn JA, Veldhuis JD, Roelfsema F. Profound amplification of secretory-burst mass and anomalous regularity of ACTH secretory process in patients with Nelson's syndrome compared with Cushing's disease. *Clin Endocrinol (Oxf)*. 2004;60:765-72.
- Chapuis Y, Pitre J, Conti F, Abboud B, Pras-Jude N, Luton JP. Role and operative risk of bilateral adrenalectomy in hypercortisolism. *World J Surg*. 1996;20:775-80.
- Tsigos C, Papanicolaou DA, Chrousos GP. Advances in the diagnosis and treatment of Cushing's syndrome. *Baillieres Clin Endocrinol Metab*. 1995;9:315-36.
- Kelly PA, Samandouras G, Grossman AB, Afshar F, Besser GM, Jenkins PJ. Neurosurgical treatment of Nelson's syndrome. *J Clin Endocrinol Metab*. 2002;87:5465-9.
- Gil-Cárdenas A, Herrera MF, Díaz-Polanco A, Ríos JM, Pantoja JP. Nelson's syndrome after bilateral adrenalectomy for Cushing's disease. *Surgery*. 2007;141:147-52.

9. Mains RE, Eipper BA, Ling N. Common precursor to corticotropins and endorphins. *Proc Natl Acad Sci USA*. 1977;74:3014-8.
10. Pereira MA, Halpern A, Salgado LR, Mendonça BB, Nery M, Liberman B, et al. A study of patients with Nelson's syndrome. *Clin Endocrinol (Oxf)*. 1998;49:533-9.
11. Höybye C, Grenbäck E, Rähn T, Degerblad M, Thorén M, Hulting AL. Adrenocorticotrophic hormone-producing pituitary tumors: 12- to 22-year follow-up after treatment with stereotactic radiosurgery. *Neurosurgery*. 2001;49:284-92.
12. Buchfelder M, Nistor R, Fahlbusch R, Huk WJ. The accuracy of CT and MR evaluation of the sella turcica for detection of adrenocorticotrophic hormone-secreting adenomas in Cushing disease. *Am J Neuroradiol*. 1993;14:1183-90.
13. Estrada J, Boronat M, Mielgo M, Magallón R, Millan I, Díez S, et al. The long-term outcome of pituitary irradiation after unsuccessful transsphenoidal surgery in Cushing's disease. *N Engl J Med*. 1997;336:172-7.
14. Kasperlik-Zaluska AA, Zgliczynski W, Jeske W, Zdunowski P. ACTH responses to somatostatin, valproic acid and dexamethasone in Nelson's syndrome. *Neuro Endocrinol Lett*. 2005;26:709-12.
15. Kelestimur F, Utas C, Ozbakir O, Selcuklu A, Kandemir O, Ozcan N. The effects of octreotide in a patient with Nelson's syndrome. *Postgrad Med J*. 1996;72:53-4.
16. Kasperlik-Zaluska AA, Bonicki W, Jeske W, Janik J, Zgliczynski W, Czernicki Z. Nelson's syndrome—46 years later: Clinical experience with 37 patients. *Zentralbl Neurochir*. 2006;67:14-20.
17. Assié G, Bahurel H, Coste J, Silvera S, Kujas M, Dugué MA, et al. Corticotroph tumor progression after adrenalectomy in Cushing's disease: A reappraisal of Nelson's syndrome. *J Clin Endocrinol Metab*. 2007;92:172-9.
18. Schallreuter KU, Pittelkow MR, Wood JM. Azelaic acid as a competitive inhibitor of thioredoxin reductase in human melanoma cells. *J Invest Dermatol*. 1987;88:516.
19. Nazzaro-Porro M, Passi S, Zina G, Breathnach AS. Ten years' experience of treating lentigo maligna with topical azelaic acid. *Acta Derm Venereol (Stockh)*. 1989;143:49-57.
20. Leibl H, Stingl G, Pehamberger H, Korschach H, Konrad K, Wolff K. Inhibition of DNA synthesis of melanoma cells by azelaic acid. *J Invest Dermatol*. 1985;85:417-22.