

ORIGINAL ARTICLE

Severe Adult Atopic Dermatitis: Treatment With Mycophenolate Mofetil in 8 Patients

I. Ballester, J.F. Silvestre, M. Pérez-Crespo, and A. Lucas

Servicio de Dermatología, Hospital General Universitario de Alicante, Alicante, Spain

Abstract. *Background.* Atopic dermatitis (AD) includes severe forms that can be refractory to various systemic treatments. Mycophenolate mofetil (MMF) has been found to be useful in patients with severe forms of AD and to have fewer side effects than long-term treatment with oral corticosteroids or cyclosporine.

Objectives. To evaluate the efficacy and adverse effects of MMF in patients seen in our skin allergy unit with severe adult AD refractory to other systemic treatments.

Methods. We performed a retrospective study of 8 patients with severe adult AD treated with MMF, analyzing the baseline characteristics, previous treatments used by the patients, and the outcome and adverse effects of treatment with MMF.

Results. Five patients treated with MMF showed improvement in the fourth week of treatment. In addition, 5 of the 8 patients presented a clear, long-term improvement in their disease. Remission of AD occurred in 1 patient, making it possible to discontinue MMF; this patient remains stable with no relapses after 4 months without treatment. The other 4 patients continue on maintenance therapy. Three patients continued to have frequent acute outbreaks of AD despite treatment with MMF for 16 to 72 weeks. All patients tolerated the treatment and there were few adverse effects.

Conclusions. MMF can be an effective option in selected patients with severe forms of atopic dermatitis. Although the response is not as rapid as with oral corticosteroids or cyclosporine, it can be used for maintenance treatment with good clinical control and few adverse effects.

Key words: mycophenolate mofetil, atopic dermatitis, immunosuppressive agents.

TRATAMIENTO DE LA DERMATITIS ATÓPICA GRAVE DEL ADULTO CON MOFETIL MICOFENOLATO EN 8 PACIENTES

Resumen. *Introducción.* La dermatitis atópica (DA) incluye formas graves que pueden ser refractarias a varios tratamientos sistémicos. Mofetil micofenolato (MMF) ha demostrado ser útil en pacientes con formas graves de DA y produce menos efectos secundarios que el tratamiento a largo plazo con ciclosporina o corticosteroides orales.

Objetivos. Valorar la eficacia y los efectos adversos del MMF en pacientes con DA grave del adulto refractaria a otros tratamientos sistémicos en nuestra Unidad de Alergia Cutánea.

Métodos. Realizamos un estudio retrospectivo de 8 pacientes con DA grave del adulto tratados con MMF. Analizamos las características basales y los tratamientos previos utilizados por los pacientes, así como los resultados y efectos secundarios obtenidos tras el empleo de MMF.

Resultados. Cinco pacientes tratados con MMF presentaron mejoría en la cuarta semana de tratamiento. Además, en 5 de 8 pacientes se consiguió una clara mejoría de la DA a largo plazo. En uno de ellos se logró una remisión de la DA, lo que permitió la retirada de MMF y después de 4 meses sin tratamiento permanece estable y sin recaídas. Los cuatro restantes siguen con terapia de mantenimiento. Tres pacientes continuaron con brotes agudos frecuentes de DA a pesar de haber mantenido el tratamiento con MMF entre 16-72 semanas. Todos los pacientes toleraron el tratamiento con escasos efectos secundarios.

Conclusiones. MMF puede ser una opción eficaz en pacientes seleccionados con formas graves de DA. Aunque MMF no produce una respuesta tan rápida como la que se obtiene con ciclosporina o con corticoides orales, permite un tratamiento mantenido, con buen control clínico y escasos efectos secundarios.

Palabras clave: mofetil micofenolato, dermatitis atópica, agentes inmunosupresores.

Correspondence:
Irene Ballester Nortes.
Servicio de Dermatología.
C/ Pintor Baeza, s/n.
03010 Alicante .
Spain.
ibalnor@coma.es

Introduction

Atopic dermatitis is a chronic inflammatory disease that affects between 2% and 17% of the population. Corticosteroids and immunomodulators can generally be used to control mild outbreaks. However, severe cases usually need treatment with oral corticosteroids or immunosuppressants such as azathioprine and cyclosporin, which have significant side effects that may limit their long-term use. For this reason, as with psoriasis, it is necessary to alternate treatment, combining and tailoring therapy to each patient.

Mycophenolate mofetil is an immunosuppressant used in transplant patients. It acts selectively on the lymphocytes and suppresses *de novo* purine biosynthesis. Although not approved by the US Food and Drug Administration (FDA) for the treatment of atopic dermatitis, its efficacy has been demonstrated in a number of publications, and it has fewer long-term adverse effects than corticosteroids or cyclosporin.¹

We report our experience with 8 patients with severe atopic dermatitis who were treated with mycophenolate mofetil.

Patients and Methods

In the last 18 months we treated 25 patients with severe adult atopic dermatitis in our skin allergy department. From this group of patients we selected 8 patients for treatment with mycophenolate mofetil. The patients were

assessed using the Severity Scoring of Atopic Dermatitis (SCORAD) index,² and severe cases were considered to be those with a score over 50. All the patients had previously received topical treatment and systemic corticosteroids or immunosuppressants with either lack of efficacy or side effects. We performed a retrospective study analyzing the baseline characteristics of the patients, the outcomes of the treatment, and the side effects observed.

For 3 patients we used a starting dose of mycophenolate mofetil of 500mg/12 h; however, given the slow response and good tolerability, we decided to increase the starting dose for the other 5 patients to either 750g/12 h or 1g/12 h, depending on the patient's weight. All 8 patients were assessed in the first 4 to 6 weeks and then once every 6 weeks, with treatment maintained depending on response (assessed using the SCORAD index).

Results

Of the 8 patients treated with mycophenolate mofetil, 6 were men and 2 were women. Mean age was 35 years. The initial SCORAD index score was 70.57 (± 13.96). All the patients except 1 had had atopic dermatitis since childhood, and all 8 patients had had frequent outbreaks treated with systemic corticosteroids. Other systemic treatments had also been used with no success or had been interrupted due to side effects (Table 1).

The first visit with all the patients took place in weeks 4 to 6: 5 out of 8 patients had a favorable response at the first visit. Another 2 patients who had not responded

Table 1. Details of 8 Patients Treated with Mycophenolate Mofetil

Patient	Sex	Age, y	Atopic dermatitis onset	Previous treatments	Dose	Duration, m	Response to treatment	Adverse effects
1	M	33	Childhood	OC, CS	1-2 g/d	8	Good	Palpitations
2	M	24	Childhood	OC, CS, MTX	1-2 g/d	9	Initial but not maintained	No
3	F	35	Childhood	OC, CS	1-2 g/d	7	Good	No
4	M	34	Childhood	OC, CS, NUVB	2 g/d	4	None	Folliculitis, HS
5	M	31	Childhood	OC, NUVB	1.5-2 g/d	4	Poor	Folliculitis
6	M	15	Childhood	OC, CS	1.5-2 g/d	6	Good	No
7	F	34	Childhood	OC, CS, NUVB	1-2 g/d	7	Good	Digestive discomfort
8	M	81	Adulthood	OC	1 g/d	7	Good	No

Abbreviations: CS, cyclosporin; HS, herpes simplex; MTX, methotrexate; NUVB, narrowband ultraviolet B; OC, oral corticosteroids.

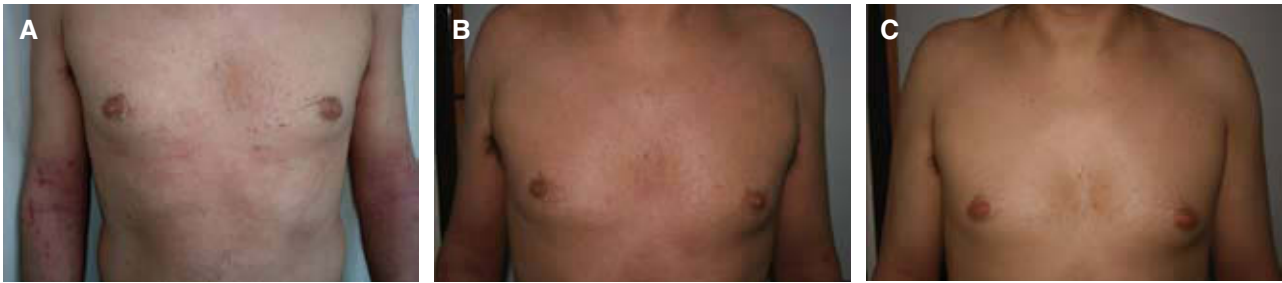

Figure 1. A. Patient with an initial Severity Scoring of Atopic Dermatitis (SCORAD) index of 55. B. Response to treatment with mycophenolate mofetil 1 g/12 h for 4 weeks (SCORAD 28). C. Response after 3 months (SCORAD 15).

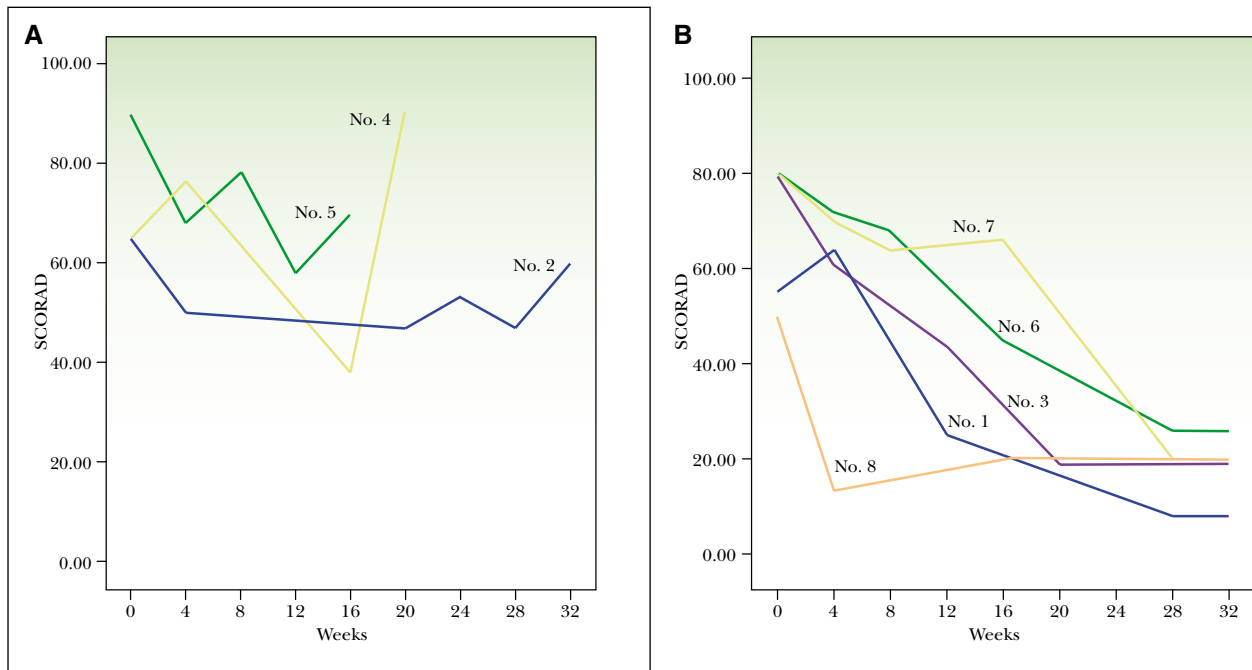


Figure 2. Severity Scoring of Atopic Dermatitis (SCORAD). Index progression during treatment with mycophenolate mofetil. Patients who failed to respond (A) and patients who responded (B). Patients are identified with the numbers given in Table 1.

to the starting dose of 500 mg/12 h prescribed in the first visit responded well after 4 weeks to an increased dose of either 750 mg/12 h or 1 g/12 h. The treatment was maintained for the 8 patients for 16 to 36 weeks; 3 of these continued to experience frequent acute outbreaks of atopic dermatitis that required treatment with oral corticosteroids. Patient number 4 (Table 1) experienced an erythrodermic outbreak of atopic dermatitis, and so treatment was suspended in week 16. A clear improvement in the atopic dermatitis was evident in 5 of the 8 patients, whose SCORAD score decreased to below 25 (Figure 1). By week 16, 3 of the patients had a SCORAD score below 25, and the other 2 patients had achieved this score by weeks 24 and 26. Mycophenolate mofetil treatment was withdrawn in

1 patient (number 3), with no signs of relapse after 4 months without treatment. Good control of the atopic dermatitis was achieved in 2 patients (numbers 1 and 8) with mycophenolate mofetil maintenance treatment at 500 mg/12 h.

Most of the patients tolerated the treatment with few side effects. The side effects observed (Table 1) were nausea, diarrhea, palpitations, folliculitis due to *Staphylococcus aureus* infection, and recurrent herpes simplex (Figure 2). An electrocardiogram study revealed no abnormalities in the patient who had reported palpitations, which resolved on reducing the dose to 500 mg/12 h. Blood counts and biochemistry analyses, including kidney function, liver function, electrolytes, blood sugar, lactate dehydrogenase, cholesterol, and triglycerides, were normal.

Table 2. Summary of Published Studies on Atopic Dermatitis Treated With Mycophenolate Mofetil

	<i>Patients, n</i>	<i>Dose</i>	<i>Weeks</i>	<i>Response</i>	<i>Adverse effects</i>
Murray and Cohen 2006 ⁴	20	1 g/12 h	5-200	All patients improved by 4 weeks: 10 full remissions, 7 maintenance therapy	HZ (4), <i>Staphylococcus aureus</i> (2), HS (1)
Satchell and Barnetson 2000 ¹¹	1	1250 mg × 2	20	Significant initial improvement, loss of response by 5 months	Nausea, CK, septicemia due to <i>S. aureus</i> , endocarditis
Neuber et al 2004 ¹⁷	10	2 g	12	100% improvement in 1 patient, >75% improvement in 3 patients, >50% improvement in 6 patients	Nausea (2), elevated LDH (2), thrombocytopenia (1), insomnia (1)
Hansen et al 2000 ⁶	5	2-2.5 g	4-12	Little improvement in 1 patient, no improvement in 1 patient, deterioration in 3 patients	Elevated ALT (1), nausea (1), headache (1)
Benez and Fierlbeck 2001 ¹⁸	3	2 g	52-116	Full response in 3-5 weeks, 1 of the 3 patients required topical corticosteroids	No
Grundmann-Kollman et al 200 ¹³	10	2 g	8	Full response in 7 patients at 4 weeks, subsequent relapse in 2 patients	Herpetic retinitis (1)
Heller et al 2007 ⁵	14	400 mg-3 g	2-24	4 full responses, 4 excellent (>90%) responses, 5 good (60%-90%) responses, 1 nonresponse	Nausea, HS, folliculitis
Ballester et al, 2009	8	500 mg-2 g	16-36	5 improvements, 1 full remission, 3 nonresponses	Nausea, palpitations, eczema herpeticum, HS, folliculitis (2)

Abbreviations: ALT, alanine transferase; CK, creatine kinase; HS, herpes simplex; HZ, herpes zoster; LDH, lactate dehydrogenase; MMF, mycophenolate mofetil.

Discussion

Management of severe adult atopic dermatitis continues to be a therapeutic challenge, despite the appearance of new alternative treatments.

There is a great deal of variability in individual responses to treatment, and patients frequently need systemic treatment for prolonged periods. There is also the risk of accumulated toxicity. A viable alternative is to consider alternating treatments.

Mycophenolate mofetil is a potent immunosuppressant, used for patients who have undergone transplants and to treat autoimmune diseases.³ It acts by selectively and reversibly inhibiting the inosine monophosphate dehydrogenase enzyme, suppressing *de novo* purine biosynthesis. Regulating this pathway enables selective inhibition of the lymphocytes, as the other inflammatory cells use the natural synthesis pathway.

Our review of the treatment of severe adult atopic dermatitis in 8 patients demonstrated efficacy and tolerability levels similar to those reported by other authors

(Table 2). The largest series was that reported by Murray and Cohen,⁴ who studied 20 patients with severe adult atopic dermatitis treated with mycophenolate mofetil for 5 to 200 weeks. Of the 20 patients, 17 improved within 4 weeks, with 10 achieving complete remission, and 7 attaining satisfactory control of the disease using mycophenolate mofetil as maintenance treatment. More recently, Heller et al⁵ also demonstrated the efficacy of mycophenolate mofetil used to treat severe atopic dermatitis in 14 children, with 4 achieving complete clearance, 4 achieving over 90% improvement, 5 achieving a 60% to 90% improvement, and 1 failing to respond. Only Hansen et al⁶ reported no improvement in any of the 5 patients in their series; this may be explained by the fact that the dose of mycophenolate mofetil was never increased beyond 2.5 g/d.

Regarding the response time for mycophenolate mofetil compared to other treatment alternatives, cyclosporin efficacy has been demonstrated (in randomized controlled trials) to be 59% in 8 weeks,⁷ that of azathioprine, 37% in 12 weeks,⁸ and that of phototherapy, 31% in 12 weeks.⁹ In

our study, of the 5 patients who responded to treatment, 3 had a SCORAD index of below 25 in week 16 and the same score was achieved by the other 2 patients by weeks 24 and 26. Overall, response was satisfactory, with gradual improvement evident for 5 of the 8 patients from the first visit in week 4. Murray et al⁴ also concluded that most patients respond by week 4 of treatment, although some patients might need 12 weeks before the efficacy of the treatment becomes evident.

The most frequent side effects are usually gastrointestinal symptoms such as nausea, vomiting, or diarrhea, which appear in 10% to 30% of patients.¹⁰ The most serious side effect reported was a case of septicemia and endocarditis caused by *S aureus*.¹¹ Although 90% of patients with atopic dermatitis are colonized by *S aureus*,¹² it seems that the reestablishment of the skin barrier resulting from treatment can also be protective and reduce the incidence of secondary infections.^{5,13} The FDA has recently reported a possible association between mycophenolate mofetil immunosuppression and the development of progressive multifocal leukoencephalopathy.¹⁴

Although mycophenolate mofetil is not approved by the FDA for the treatment of atopic dermatitis, it has been demonstrated to be efficacious for patients with severe cases of the disease, and also triggers fewer side effects than long-term treatment with cyclosporin or oral corticosteroids.^{15,16} Apart from treatment limitations due to long-term accumulated toxicity, it should be noted that these patients have severe forms of the disease that are resistant to several systemic treatments. Although mycophenolate mofetil is not a treatment that induces a response as rapid as that of cyclosporin or oral corticosteroids, its response time is similar to those of other treatments such as methotrexate, phototherapy, and azathioprine. Therefore, mycophenolate mofetil is an additional long-term maintenance therapy option for severe forms of atopic dermatitis. Although our study was limited by the fact that it was retrospective and had no control group, we conclude that mycophenolate mofetil may be useful for selected patients, provided they are closely monitored for infection.

Conflicts of Interest

The authors declare no conflicts of interest.

References

- Grundmann-Kollmann M, Korting HC, Behrens S, Leiter U, Krähn G, Kaufmann R, et al. Successful treatment of severe refractory atopic dermatitis with mycophenolate mofetil. *Br J Dermatol*. 1999;141:175-6.
- Oranje A, Glazenburg E, Wolkerstorfer A, Waard-van der Spek FB. Practical issues on interpretation of scoring atopic dermatitis: the SCORAD index, objective SCORAD and the three-item severity score. *Br J Dermatol*. 2007;157:645-8.
- Grundmann-Kollmann M, Podda M, Ochsendorf F, Boehncke WH, Kaufmann R, Zollner TM. Mycophenolate mofetil is effective in the treatment of atopic dermatitis. *Arch Dermatol*. 2001;137:870-3.
- Murray ML, Cohen JB. Mycophenolate mofetil therapy for moderate to severe atopic dermatitis. *Clin Exp Dermatol*. 2006;32:23-37.
- Heller M, Shin HT, Orlow SJ, Schaffer JV. Mycophenolate mofetil for severe childhood atopic dermatitis: experience in 14 patients. *Br J Dermatol*. 2007;157:127-32.
- Hansen ER, Buus S, Deleuran M, Andersen KE. Treatment of atopic dermatitis with mycophenolate mofetil. *Br J Dermatol*. 2000;143:1324-6.
- Sowden JM, Berth-Jones J, Ross JS, Motley RJ, Marks R, Finlay AY, et al. Double-blind, controlled, crossover study of cyclosporin in adults with severe refractory atopic dermatitis. *Lancet*. 1991;338:137-40.
- Meggitt SJ, Gray JC, Reynolds NJ. Azathioprine dosed by thiopurine methyltransferase activity for moderate-to-severe atopic eczema: a double-blind, randomised controlled trial. *Lancet*. 2006;367:839-46.
- Reynolds NJ, Franklin V, Gray JC, Diffey BL, Farr PM. Narrow-band ultraviolet B and broad-band ultraviolet A phototherapy in adult atopic eczema: a randomised controlled trial. *Lancet*. 2001;357:2012-6.
- Akhavan A, Rudikoff D. The treatment of atopic dermatitis with systemic immunosuppressive agents. *Clin Exp Dermatol*. 2003;21:225-40.
- Satchell AC, Barnetson R. Staphylococcal septicaemia complicating treatment of atopic dermatitis with mycophenolate. *Br J Dermatol*. 2000;143:198-233.
- Leyden JJ, Marples RR, Kligman AM. Staphylococcus aureus in the lesions of atopic dermatitis. *Br J Dermatol*. 1974;90:525-30.
- Akdis CA, Akdis M, Bieber T, Bindslev-Jensen C, Boguniewicz M, Eigenmann P, et al. Diagnosis and treatment of atopic dermatitis in children and adults: European Academy of Allergology and Clinical Immunology/American Academy of Allergy, Asthma and Immunology/PRACTALL Consensus Report. *Allergy*. 2006;61:969-87.
- Communication About an Ongoing Safety Review of Cell-Cept (mycophenolate mofetil) and Myfortic (mycophenolate acid). US Food and Drug Administration: Center for Drug Evaluation and Research; 2008.
- Schmitt J, Schäkel K, Schmitt N, Meurer M. Systemic treatment of severe atopic eczema: a systematic review. *Acta Derm Venereol*. 2007;87:100-11.
- Hsu CJ, Wang LF. Emerging treatment of atopic dermatitis. *Clin Rev Allergy Immunol*. 2007;33:199-203.
- Neuber K, Schwartz I, Itschert G, Dieck AT. Treatment of atopic eczema with oral mycophenolate mofetil. *Br J Dermatol*. 2000;143:385-91.
- Benez A, Fierlbeck G. Successful long-term treatment of severe atopic dermatitis with mycophenolate mofetil. *Br J Dermatol*. 2001;144:638-9.