

6. Pippione M, Aloï F, Depaoli MA. Hair-follicle nevus. *Am J Dermatopathol.* 1984;6:245-7.
7. Hyman AB, Clayman SJ. Hair-follicle nevus; report of a case and a review of the literature concerning this lesion and some related conditions. *AMA Arch Derm.* 1957;75: 678-84.
8. Ackerman AB, De Viragh PA, Chongchitnant N. Hamartomas. In: *Febiger LA, ed. Neoplasms with follicular differentiation.* Philadelphia: Lea & Febiger; 1993. p. 169-204.
9. Jaqueti G, Requena C, Requena L. Trichofolliculoma. In: Requena L, ed. *Neoplasias anexas cutáneas.* Madrid: Aula Médica; 2004. p. 221-6.
10. Ban M, Kamiya H, Yamada T, Kitajima Y. Hair follicle nevi and accessory tragi: variable quantity of adipose tissue in connective tissue framework. *Pediatr Dermatol.* 1997;14:433-6.

## Actinomyces of the Lip: an Exceptional Site

J. Sánchez-Estella, M.T. Bordel-Gómez, E. Cardeñoso-Álvarez, and E. Garabito-Solovera

Servicio de Dermatología Hospital Virgen de la Concha, Zamora, Spain

### To the Editor:

Actinomyces is a chronic bacterial infection that is becoming less common due to the widespread use of antibiotics and the improvement in oral hygiene.

There are 4 main clinical forms, differentiated according to the site affected: cervicofacial, thoracic, ileocecal, and pelvic. However, many other sites have been reported.

Actinomyces of the lip is very rare. In an extensive review, we only found 3 cases published in the past 30 years.<sup>1-3</sup>

We present the case of a 69-year-old man with no past history of interest, who was seen for a tender, nodular

lesion on the lip that had been present for 1 year. The patient reported no suppuration; the mouth showed signs of sepsis, and on the mucosal surface of the lower lip there was a round, violaceous, well-delimited, very hard nodule with a diameter of 2 cm (Figure 1). There were no palpable regional lymph nodes.

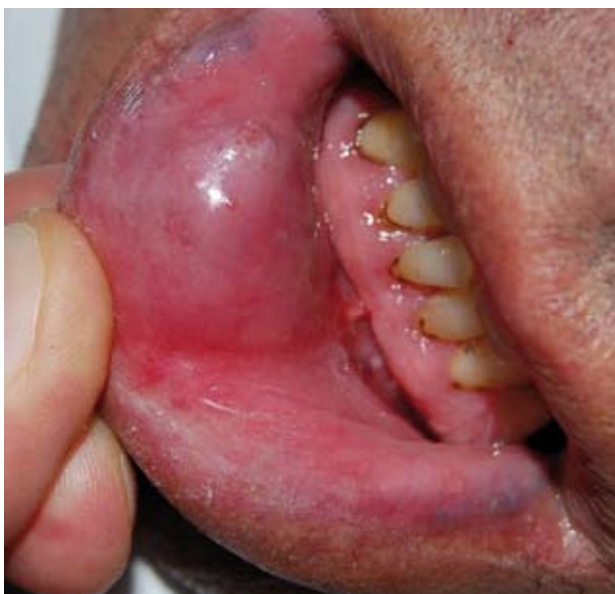On the suspicion of a tumor of the minor salivary glands, the lesion was excised under local anesthesia; the nodule proved very adherent to the adjacent tissues and significant bleeding occurred during the excision. Culture was not performed.

Histological study showed an abscess surrounded by a fibrous capsule. Within the abscess there were granulomatous areas with abundant macrophages and plasma cells and other areas with a predominance of multinuclear cells (Figure 2).

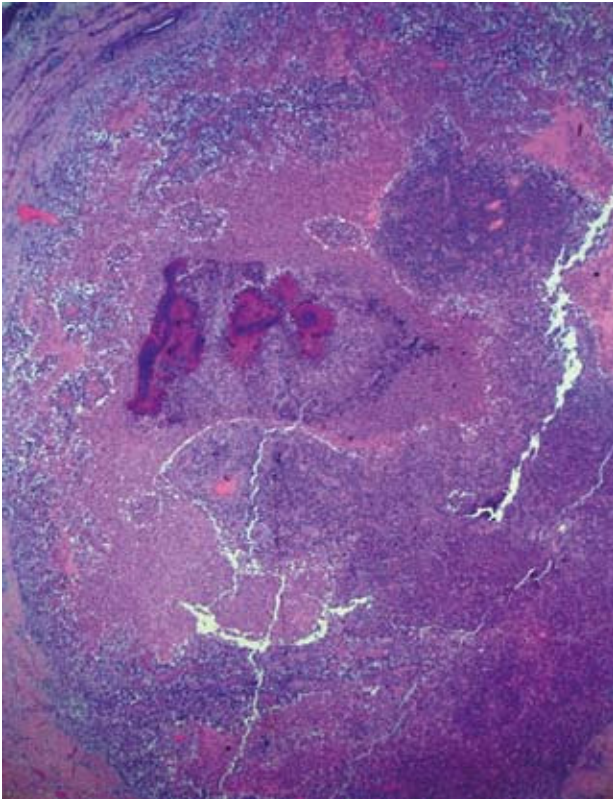
Some of these latter areas contained irregular, amorphous basophilic masses that had peripheral, radial, pear-shaped, eosinophilic projections (Figure 3). These masses did not stain with Ziehl-Neelsen stain, and the Gomori silver metenamine stain demonstrated that they were formed of aggregates of filamentous bacilli.

With the diagnosis of actinomyces of the lower lip, general blood tests with serology for human immunodeficiency virus, otorhinolaryngological examination, chest radiograph, and abdominal ultrasound were performed, with normal results. Complementary treatment was prescribed with oral amoxicillin 500 mg every 6 hours for 3 months. Two years later, the patient had suffered no recurrence.

Actinomyces is produced by various species of the genus *Actinomyces*, particularly *Actinomyces israelii*. These are branching, pleomorphic, filamentous, gram-positive bacilli that are obligate or facultative anaerobes and are not acid or alcohol fast. They form part of the normal flora of the mouth, gastrointestinal tract, and female genital



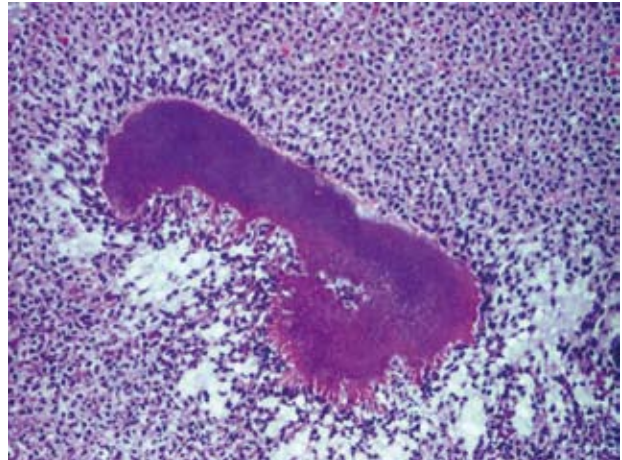
**Figure 1.** Violaceous nodule with a diameter of 2 cm, located in the mucosa of the lower lip.



**Figure 2.** Well-defined abscess with granulomatous areas and others with a predominance of multinuclear cells and that contain sulfur granules (hematoxylin-eosin, ×10).

tract. These organisms have a very low pathogenicity and therefore require a previous tissue lesion (surgery, trauma, foreign body, pre-existing inflammatory process, etc) and the presence of other cooperating microorganisms (copathogens) to cause infection.<sup>4</sup> Although actinomycosis usually affects immunocompetent individuals, factors that reduce host defenses favor this infection.

Clinically it is characterized by slowly developing, localized tumors that tend to develop abscesses and fistulas; the presence of yellowish granules of 1 to 2 mm in diameter in the exudate (sulfur granules) is characteristic but not pathognomic. The infection provokes an intense



**Figure 3.** Characteristic sulfur granules of actinomycosis: basophilic with eosinophilic, pear-shaped extensions (hematoxylin-eosin, ×200).

fibrotic reaction in the surrounding tissues, giving rise to a woody consistency, frequently mimicking a neoplasm.

Published cases of actinomycosis of the lip (Table) presented as isolated, small, hard abscesses that were not associated with deeper lesions or with immunosuppression, and the majority were confused with tumors of the minor salivary glands.

The diagnosis is made by anaerobic culture or by the histological demonstration of the presence of the characteristic sulfur granules within the abscesses. The histological differential diagnosis must include other conditions that produce sulfur granules. Although the size, morphology, and color of the granules is highly suggestive, it should be demonstrated that they are formed of aggregates of fine, filamentous bacilli using Gram or Gomori stains; these studies will detect granules formed of nonfilamentous bacilli (botryomycosis) or thick hyphae of fungi (eumycetomas) and those formed of nonfilamentous, acid and alcohol fast bacilli, which would exclude a diagnosis of actinomycetomas and nocardiosis.

The intense fibrosis that surrounds the abscesses in this condition impedes the penetration of antibiotics, and the ideal treatment is therefore a combination of surgical

**Table.** Clinical Features of Actinomycosis of the Lip

No.	Author	Year	Age, y	Sex	Site	Size, cm	Clinical Course	Clinical Diagnosis
1	Kikiewicz D <sup>1</sup>	1978	50	M	Upper lip	*	5 mo	Infected cyst
2	Appiah-Anane S and Tickle M <sup>2</sup>	1995	32	F	Upper lip	2	2 mo	MSG tumor
3	Lan MC et al <sup>3</sup>	2007	50	M	Lower lip	1	3 mo	MSG tumor
4	Sánchez Estella J et al	2009	69	M	Lower lip	2	1 y	MSG tumor

\*Size of a cherry. Abbreviations: F, female; M, male; MSG, minor salivary gland.

excision and antibiotic therapy. The antibiotic of choice is penicillin, and prolonged treatment is recommended in order to prevent recurrences; the duration of treatment will vary according to the complexity of the condition (from 3 to 18 months). Due to a lack of previous experience in such cases, we decided to prescribe complementary treatment for 3 months after surgery, using an oral penicillin derivative, with a good outcome after follow-up.

An interesting issue is how the infection becomes established in cases of actinomycosis of the lip in which there is no recent history of predisposing factors. Infection of minimal self-injury would be favored by poor oral hygiene, as in our patient, or, more probably, infection occurs in a previous mucocele, as suggested in one of the cases published after the histological finding of a possible salivary retention cyst adjacent to the actinomycotic abscess.<sup>2</sup>

## Dermatofibroma with Cholesterol Deposits in a Patient With HIV Infection

**B. Monteagudo, M. Ginarte, Ó. Suárez-Amor, and J. Toribio**

Servicio de Dermatología, Facultad de Medicina, Complejo Hospitalario Universitario de Santiago de Compostela, La Coruña, Spain

*To the Editor:*

Dermatofibroma (DF), also called histiocytoma, cutaneous fibrous histiocytoma, nodular subepidermal fibrosis, or sclerosing hemangioma, is a very common, benign skin tumor of fibrohistiocytic origin. It presents as firm, single or multiple tumors that are usually hyperpigmented and less than 1 cm in diameter; they tend to appear on the lower limbs of young women. Histologically they are characterized by a poorly demarcated dermal nodule consisting of variable proportions of fibroblasts, young and mature collagen, capillaries, and histiocytes. Treatment is by surgical excision, although this is not usually necessary. The debate continues as to whether this is a neoplastic disorder or if it is actually a reactive proliferation of fibroblasts secondary to insect bites or minor trauma.<sup>1</sup>

More than 40 clinical-pathologic variants of DF have been reported, classified according to their clinical presentation, structural and stromal features, or variations in their cellular make-up<sup>2</sup>; however, there are many other subvariants, given that 10% of all DFs are combined (simultaneous presence of 2 or more histopathological forms).<sup>3</sup>

The cholesterotic fibrous histiocytoma is a rare variant of DF described by Hunt et al<sup>4</sup> in 1990. It consists of a lesion that is clinically identical to classic DF, but the diagnosis is based on the histopathological study,

Correspondence:  
Juan Sánchez Estella  
Plaza de Alemania 3, 3.º 1.ª Pta  
49014 Zamora, Spain  
jsancheze@meditex.es

### Conflicts of Interest

The authors declare no conflicts of interest.

### References

1. Kikiewicz D. A case of actinomycosis of the upper lip. *Czas Stomatol.* 1978;3:187-9.
2. Appiah-Anane S, Tickle M. Actinomycosis—an unusual presentation. *Br J Oral Maxillofac Surg.* 1995;33:248-9.
3. Lan MC, Huang TY, Lin TY, Lan MY. Pathology quiz case 1. Actinomycosis of the lip mimicking minor salivary gland tumor. *Arch Otolaryngol Head Neck Surg.* 2007;133:411-4.
4. Brook I. Actinomycosis: diagnosis and management. *South Med J.* 2008;101:1019-23.

which reveals cholesterol deposits within the lesion. Its appearance should suggest the possibility of an underlying hyperlipoproteinemia. We report a new case of DF with deposits of cholesterol crystals seen in a patient with human immunodeficiency virus (HIV) infection, with no associated dyslipidemia.

The patient was a 37-year-old man with a past history of hepatitis C virus and HIV infection; his most recent CD4 lymphocyte count was 600/ $\mu$ L, with an undetectable viral load. He was on combination antiretroviral therapy with didanosine, nelfinavir, and stavudine. There was no personal or family history of hypercholesterolemia or hypertriglyceridemia. He came to the dermatology department for evaluation of 3 lesions on the left foot, left lateral chest wall, and left elbow; the lesions had been present for less than a year. All were asymptomatic except for the one on the left elbow, which was tender to pressure. The patient reported no trauma or previous lesions in those areas.

On physical examination, 3 brownish tumors were observed on the left foot, left lateral chest wall, and left elbow. They had a smooth surface, were between 0.5 and 1 cm in diameter, were firm on palpation, and were not adherent to the deep planes (Figure 1). Lateral pressure produced a depression in the overlying skin (dimple sign).