

Palmoplantar Cutaneous Reaction to Sorafenib

B. Echeverría, B. Llombart, R. Botella-Estrada, and C. Guillén

Servicio de Dermatología, Fundación Instituto Valenciano de Oncología, Valencia, Spain.

To the Editor:

Sorafenib is a new oral drug currently approved for the treatment of metastatic renal cell carcinoma and hepatocellular carcinoma. The drug acts partly by inhibiting the tyrosine kinase receptors implicated in angiogenesis and tumor progression, and partly by blocking Raf kinase pathways. Up to 90% of patients receiving this treatment are reported to develop dermatological side-effects. Hyperkeratosis-like lesions commonly appear on the pressure pads of palms and soles and this may require withdrawal of the medication in more serious cases.^{1,2}

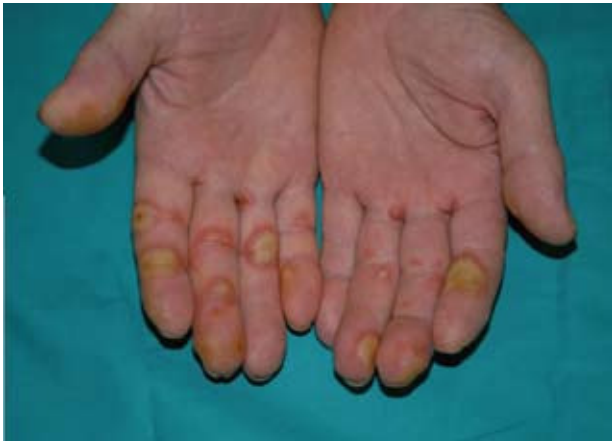

Figure 1. Yellowish hyperkeratotic papules with symmetrical erythematous halo.

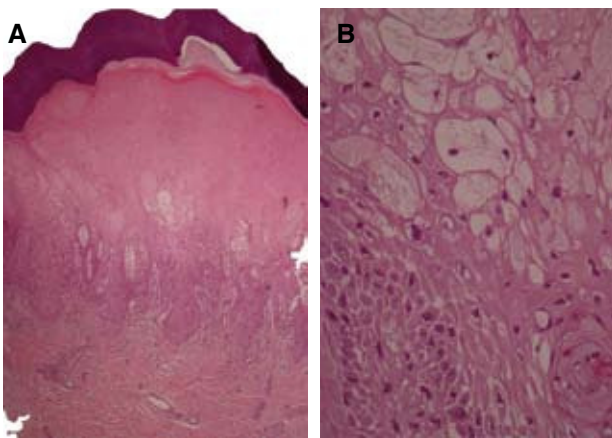


Figure 2. Epidermal vacuolar degeneration (A) and detail of the intra- and inter-cytoplasmic vesicles secondary to progressive spongiosis (B).

The patient was a 62-year-old man, with a medical history of diabetes mellitus treated with oral antidiabetic agents, and metastatic renal cell carcinoma treated with sorafenib at a dose of 400 mg twice daily for the previous 4 weeks. He consulted for some very painful and disabling lesions on the finger flexures and interdigital areas of the hands that had appeared 3 days previously (Figure 1).

Physical examination revealed yellowish hyperkeratotic plaques with a symmetrical erythematous halo that took on the form of tense blisters in some areas.

A 4 mm punch biopsy was taken of one of the lesions. Histology showed a superficial perivascular and periadnexal lymphocytic infiltrate that lacked atypical features and that was far more abundant at the dermal-epidermal junction. The epidermis displayed marked spongiosis, with the formation of intracytoplasmic vesicles and vacuolar degeneration of keratinocytes in the upper levels (Figure 2).

Topical treatment with clobetasol propionate ointment was prescribed and the discomfort and lesions resolved in 2 weeks without the need to suspend oncology treatment.

Sorafenib is a new oral chemotherapy treatment. It acts by inhibiting various kinase receptors including endothelial growth factors 2 and 3, transforming growth factor- β and c-kit, and blocking the Raf pathway.¹⁻³ Its use has currently been approved for metastatic renal cell carcinoma and hepatocellular carcinoma, and research is being undertaken into its application to breast cancer, non-small cell lung cancer and melanoma.

Dermatological manifestations are the most common side-effects, although the pathogenic mechanism is not entirely clear at present.

Palmoplantar cutaneous reaction is one of the most common side-effects (30%).⁴ This is characterized by paresthesia, pain, and discomfort that may even lead to immobilization or the inability to handle objects, followed by the appearance of yellowish hyperkeratotic plaques in the pressure areas—mainly on the palms, but also on the soles (Table 1).

This is clinically similar to the palmoplantar erythrodysesthesia caused by other oncology drugs such as capecitabine, cytarabine, doxorubicin, and fluorouracil.^{5,6} The differences are however that sorafenib-induced reaction tends to be hyperkeratotic and localized, occurring in the pressure areas with mild involvement, while palmoplantar erythrodysesthesia does not tend to

Tabla 1. National Cancer Institute Classification of Palmoplantar Cutaneous Reaction.

Grading of Skin Lesion	Description
Grade 1	Minimal changes or painless dermatitis
Grade 2	Cutaneous change or pain that does not interfere with function
Grade 3	Ulcerative dermatitis or cutaneous changes that are painful or interfere with function

be hyperkeratotic (except in chronic phases), has a diffuse distribution, and tends to be more serious.

Sunitinib—a treatment from the same family as sorafenib that also acts by inhibiting kinase receptors implicated in angiogenesis and tumor progression—is also known to generate similar palmoplantar cutaneous reactions.

In histological terms, some authors have considered vacuolar degeneration of keratinocytes, the presence of intracytoplasmic eosinophilic bodies, and the formation of vesicles in the Malpighian layer to be the most relevant features.⁷

These tend to be mild lesions (grade 1/2) that respond to topical treatment with urea and salicylic acid emollient creams and high potency corticosteroids. Occasionally, the presence of severe lesions (grade 3/4) may mean that doses of oncology drugs will need to be halved or administration suspended temporarily until the lesions have healed. The lesions do not generally reappear when treatment is reinitiated.

Other dermatological side-effects include: asymptomatic subungual splinter hemorrhages (60%)² in patients treated with both sorafenib and sunitinib; a scaly erythematous facial eruption (63%)¹ that resembles an outbreak of seborrheic dermatitis and resolves spontaneously; varying degrees of rash; alopecia (27%)⁴ with regrowth during treatment or after withdrawal; and cutaneous xerosis mostly on the lower limbs (10%-20%).²

It is important that patients be made aware of the higher frequency of dermatological side-effects produced by this new oncology treatment—including cases of palmoplantar cutaneous reaction like the one seen above. They should be provided with preventive guidance on hygiene, appropriate clothing, and footwear. Where the lesions do occur, appropriate topical treatment should be prescribed and the decision made on whether or not to reduce the dose or temporarily suspend medication (Table 2).

Tabla 2. Recommendations for and Treatment of Palmoplantar Cutaneous Reaction Depending on the Extent of Involvement.

Involvement	Treatment
Preventive measures	Emollient creams and comfortable footwear
Grade 1	Emollient and keratolytic creams in cases of hyperkeratosis
	Topical corticosteroids twice daily in cases of inflammation or painless erythema
Grade 2	Emollient and keratolytic creams and topical corticosteroids twice daily
Grade 3	50% reduction in dose or temporary suspension of treatment with sorafenib combined with the topical treatments described

Correspondence:
Begoña Echeverría García,
Servicio de Dermatología,
Instituto Valenciano de Oncología,
C/ Beltrán Báguena, 8,
46009 Valencia, Spain

Conflicts of Interest

The authors declare no conflicts of interest.

References

- Autier J, Escudier B, Wechsler J, Spatz A, Robert C. Prospective study of the cutaneous adverse effects of sorafenib, a novel multikinase inhibitor. *Arch Dermatol.* 2008;144:886-92.
- Robert C, Mateus C, Spatz A, Wechsler J, Escudier B. Dermatologic symptoms associated with the multikinase inhibitor sorafenib. *J Am Acad Dermatol.* 2009;60:299-305.
- Liu L, Cao Y, Chen C, Zhang X, McNabola A, Wilkie D, et al. Sorafenib blocks the RAF/MEK/ERK pathway, inhibits tumor angiogenesis, and induces tumor cell apoptosis in hepatocellular carcinoma model PLC/PRF/5. *Cancer Res.* 2006;66:11851-8.
- Robert C, Mateus C, Spatz A, Wechsler J, Escudier B. Dermatologic symptoms associated with the multikinase inhibitor sorafenib. *J Am Acad Dermatol.* 2009;60:299-305.
- Hueso L, Sanmartín O, Nagore E, Botella-Estrada R, Requena C, Llombart B, et al. Eritema acral inducido por quimioterapia: estudio clínico e histopatológico de 44 casos. *Actas Dermosifiliogr.* 2008;99:281-90.
- Nagore E, Insa A, Sanmartín O. Antineoplastic therapy-induced palmar plantar erythrodysesthesia ("hand-foot") syndrome. Incidence, recognition and management. *Am J Clin Dermatol.* 2000;1:225-34.
- Yang CH, Lin WC, Chuang CK, Chang YC, Pang ST, Lin YC, et al. Hand-foot skin reaction in patients treated with sorafenib: a clinicopathological study of cutaneous manifestations due to multitargeted kinase inhibitor therapy. *Br J Dermatol.* 2008;158:592-6.