

lesions of the fingers and palms of young individuals. Immunohistochemistry is characteristic.

Correspondence:  
Mónica García Arpa  
Servicio de Dermatología  
Hospital General de Ciudad Real  
Avda. Tomelloso, s/n  
13005 Ciudad Real, Spain  
mgarciaa73@yahoo.es

#### Conflicts of interest

The authors declare no conflicts of interest.

## References

1. Lazarus SS, Trombetta LD. Ultrastructural identification of a benign perineural cell tumor. *Cancer*. 1978;41:1823-9.
2. Fetsch J, Miettinen M. Sclerosing perineurioma: a clinicopathologic study of 19 cases of a distinctive soft tissue lesion with a predilection for the fingers and palms of young adults. *Am J Surg Pathol*. 1997;21:1433-42.
3. Huang HY, Sung MT. Sclerosing perineuriomas affecting bilateral hands. *Br J Dermatol*. 2002;146:129-33.
4. Canales-Ibarra C, Magariños G, Olsoff-Pagovich P, Ortiz-Hidalgo C. Cutaneous sclerosing perineurioma of the digits: an uncommon soft-tissue neoplasm. Report of two cases with immunohistochemical analysis. *J Cutan Pathol*. 2003;30:577-81.
5. Nakamura T, Kawamura T, Nariya S, Fujiwara M. Cutaneous sclerosing perineurioma of the digit. *Int J Dermatol*. 2006;45:1086-8.
6. Sciot R, Cin PD, Hagemeyer A, De Smet L, van Damme B, van den Berghe H. Cutaneous sclerosing perineurioma with cryptic NF2 gene deletion. *Am J Surg Pathol*. 1999;23:849-53.
7. Robson AM, Calonje E. Cutaneous perineurioma: a poorly recognized tumour often misdiagnosed as epithelioid histiocytoma. *Histopathology*. 2000;37:332-9.

## Two Patients With Cutaneous Manifestations of Edwards Syndrome

P. Hernández-Bel,<sup>a</sup> J. López,<sup>a</sup> I. Febrer,<sup>a</sup> J.L. Fayos,<sup>b</sup> C. García,<sup>b</sup> A. García,<sup>b</sup> and V. Alegre<sup>a</sup>

<sup>a</sup>Servicio de Dermatología and <sup>b</sup>Servicio de Pediatría, Consorcio Hospital General Universitario de Valencia, Valencia, Spain

#### To the Editor:

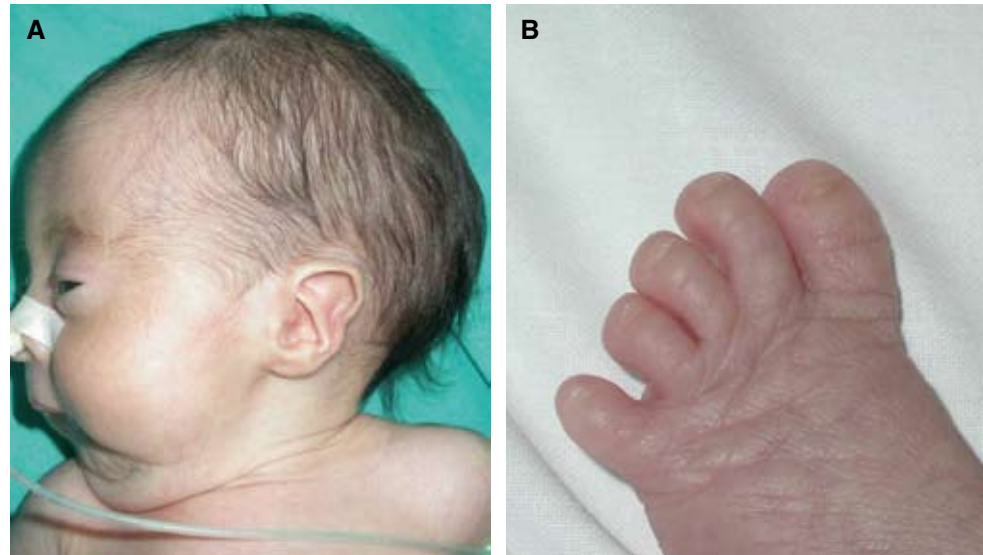Edwards syndrome or trisomy 18 is a chromosomal disorder with a wide variety of clinical manifestations. The skin lesions, together with other multiple malformations, can orientate the neonatal diagnosis in those cases that have escaped detection during gestation. We present 2 cases affected by this rare disease.

Case 1: The patient was an infant born at term to a 42-year-old mother. On examination, the infant presented a dysmorphic facies with low-set, dysplastic ears, retrognathia, and hirsutism of the forehead. Further important clinical findings included fingernail and toenail hypoplasia, hypoplasia of the labia majora, with a prominent clitoris, and syndactyly of the second and third toes of the right foot, with the presence of a prominent calcaneus (rocker-bottom foot). In addition, the fingers adopted a characteristic position, with the second digit overriding the third (trisomy hand) (Figures 1 and 2). The syndrome had not been diagnosed during pregnancy, and the gestational ultrasound controls were reported as normal. In view of the clinical findings, confirmatory karyotyping was performed; the result was 47XX+18, establishing the definitive diagnosis of Edwards syndrome. Additional tests showed the presence of a persistent ductus arteriosus, ostium secundum-type

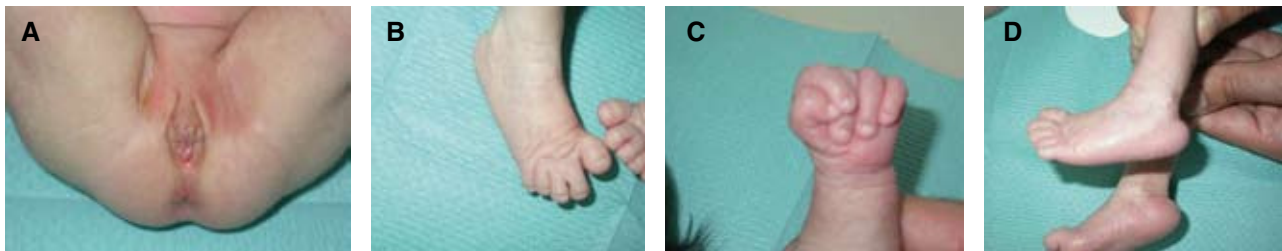
atrial septal defect, encephalic arachnoid cysts, and horseshoe kidneys. At 7 weeks of life, the infant developed respiratory insufficiency with acute pulmonary edema as a complication of the congenital cardiopathy, and died a few hours later.

Case 2: The patient was an infant born at term, in whom the ultrasound controls during the third trimester of gestation detected multiple neural tube defects, ventricular septal defect, and a possible transposition of the great vessels. For this reason, karyotyping was performed at week 34 using fluorescence in situ hybridization; the result was of a male fetus with trisomy 18 (47XY+18). At birth, the infant presented marked cyanosis with growth delay, an Apgar score of 2, and spinal dysraphism (lumbar myelomeningocele). There was also hirsutism of the forehead, fingernail and toenail hypoplasia, a dermatoglyphic pattern with ridges on the pulps of all the fingers, and the presence of bluish macules of reticular appearance affecting the skin of the trunk and limbs, compatible with cutis marmorata. The infant died 4 hours after birth.

Trisomy 18, described by Edwards in 1960,<sup>1</sup> is the second most common syndrome of multiple malformations after trisomy 21. It has an estimated incidence of 1 in 6000 to 1 in 13 000 live newborn



**Figure 1.** A, Characteristic dysmorphic facies with hypertelorism, low-set ears, and retrognathia. There is associated hirsutism of the forehead. B, Unguis hypoplasia of the toes.



**Figure 2.** Typical, multiple deformities of this syndrome. A, Hypoplasia of the labia majora with a prominent clitoris. B, Syndactyly of the second and third toes. C, Trisomy hand. D, Rocker-bottom foot.

infants, and appears to be more common in girls (3:1). Advanced age of the mother may be a risk factor for the syndrome.<sup>2</sup> It has a high lethality, with a mortality of 90% in the first year of life.<sup>3,4</sup> The main causes of death are congenital heart diseases, apnea, and pneumonia.<sup>5</sup> More than 130 different clinical abnormalities have been reported in these patients. They may present a delay in weight and height gain, cranial malformations with a characteristic facies and microcephaly, prominent occiput, low-set ears, and micrognathia; various congenital heart diseases, detectable in 90% of cases; urogenital malformations, such as horseshoe kidney; limb defects including the presence of trisomy hand or a prominent heel; and many further congenital malformations affecting the gastrointestinal and central nervous systems. The typical cutaneous features include unguis hypoplasia of the hands and feet, hirsutism affecting the forehead and back, absence of subcutaneous fat at birth, a dermatoglyphic pattern with ridges on the pulps of at least 6 fingers, and persistent reticulated lesions of cutis marmorata, as occurs in Down syndrome, Cornelia de Lange syndrome, congenital hypothyroidism, and

neonatal lupus. The persistent cutis marmorata in these patients should not be confused with cutis marmorata telangiectatica congenita, which causes phlebectasia and telangiectasias associated with ulcers and limb atrophy.<sup>2,5</sup>

In conclusion, we would like to highlight the importance of the cutaneous manifestations, which are present in more than 50% of patients with Edwards syndrome; in association with other multiple malformations, they can help to orientate the diagnosis. The definitive diagnosis is based on karyotyping, which will confirm the presence of trisomy 18.<sup>1,5,6</sup>

---

Correspondence:  
Pablo Hernández Bel  
Servicio de Dermatología  
Consorcio Hospital General Universitario de Valencia  
Avda. Tres Cruces, s/n  
46014 Valencia, Spain  
pablohernandezbel@hotmail.com

#### Conflict of Interest

The authors declare no conflicts of interest.

## References

1. Edwards JH, Harnden DG, Cameron AH, Crosse VM, Wolff OH. A new trisomic syndrome. *Lancet*. 1960;1:787-90.
2. Warkany J, Passarge E, Smith LB. Congenital malformations in autosomal trisomy syndromes. *Am J Dis Child*. 1966;112:502-17.
3. Rasmussen SA, Wong LY, Yang Q, May KM, Friedman JM. Population-based analyses of mortality in trisomy 13 and trisomy 18. *Pediatrics*. 2003;111:777-84.
4. Carter PE, Pearn JH, Bell J, Martin N, Anderson NG. Survival in trisomy 18. Life tables for use in genetic counselling and clinical paediatrics. *Clin Genet*. 1985;27:59-61.
5. Jones KL. Trisomy 18 syndrome. In: Jones KL, ed. *Smith's recognizable patterns of human malformation*. Philadelphia: Saunders;1997. p. 16-7.
6. Petek E, Pertl B, Tschernigg M, Bauer M, Mayr J, Wagner K, et al. Characterisation of a 19-year-old "long-term survivor" with Edwards syndrome. *Genet Couns*. 2003;14:239-44.

## Dermatologic Toxicity to Sorafenib

D. Velázquez,<sup>a</sup> P. de la Cueva,<sup>b</sup> P. Zamberk,<sup>a</sup> and P. Lázaro<sup>a</sup>

<sup>a</sup>Servicio de Dermatología, Hospital General Universitario Gregorio Marañón, Madrid, Spain

<sup>b</sup>Servicio de Dermatología, Hospital Infanta Leonor. Madrid, Spain

### To the Editor:

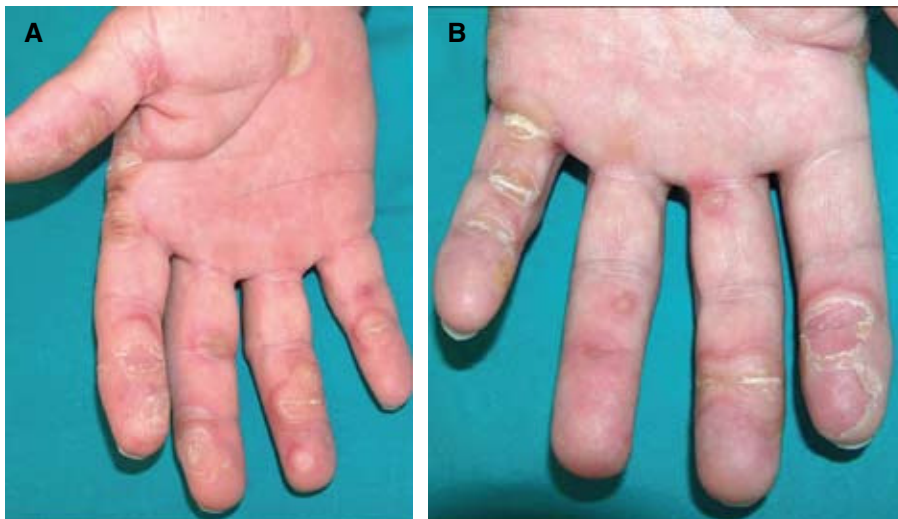
Sorafenib is a recent orally administered drug in the family of tyrosine kinase inhibitors; it has proved highly effective in the treatment of advanced renal cell and hepatocellular carcinomas.<sup>1</sup> Current research is investigating its application in the treatment of other tumors, such as metastatic melanoma or papillary thyroid carcinoma.<sup>2</sup> However, as with all chemotherapy drugs sorafenib has adverse effects, both systemic and dermatological. More than 93% of patients receiving sorafenib in monotherapy will suffer from some form of skin reaction.

We present the case of a 53-year-old man, diagnosed with hepatocellular carcinoma secondary to chronic liver disease due to hepatitis C virus infection, who began treatment with sorafenib at a dose of 400 mg twice a day. After 2 weeks of treatment, the patient began experiencing slightly painful skin lesions on the palms of the hands

and later on the soles of the feet, with no associated neurological symptoms. Physical examination revealed papules and plaques—some targetoid, edematous, and desquamative—located on the palms, the palmar surface of the fingers, and the soles of the feet (Figure 1).

Histology of tissue taken from a palmar lesion revealed a thick, orthokeratotic corneal layer in the epidermis, with an underlying area of parakeratosis and significant irregular acanthosis. Occasional necrotic keratinocytes were identified, with no sign of vacuolar degeneration of the basal layer. The blood vessels nearest the surface of the dermis were dilated and accompanied by a mild lymphocytic and histiocytic infiltrate (Figures 2 and 3).

The clinical findings and temporal relationship with the administration of sorafenib led to treatment with topical corticosteroids and a reduction of the drug dosage by half. This resulted in good response and progressive resolution of the skin lesions.



**Figure 1.** Edematous, desquamative papules and plaques in a symmetrical distribution on the palms and the soles of feet.