

CLINICAL SCIENCE LETTERS

Myointimoma: A Rare Tumor of the Penis

V. Monsálvez,^a J.L. Rodríguez-Peralto,^b L. Fuertes,^a C. Garrido,^a and S. López-Gómez^a

^aServicio de Dermatología and ^bServicio de Anatomía Patológica, Hospital 12 de Octubre, Madrid, Spain.

To the Editor:

Myointimoma is a benign tumor that was first described by Fetsch et al¹ in the year 2000. It is considered to be a rare tumor arising from the intima of the vessels of the corpora cavernosa of the penis, and has been included as a specific entity among the genitourinary tumors in the latest review by the World Health Organization in 2006. In our review of the literature using the term myointimoma, we found only 17 cases. Myointimoma is a tumor that is usually found at the level of the glans and corona of the penis and presents clinically as a palpable, asymptomatic nodule of variable size. It develops over a variable period of days or months (4 days to 6 months),² but despite the fast rate of growth, it is not an aggressive tumor. It can occur at any age, with cases reported from 2 to 61 years.¹ It is not related to a history of local trauma or to the presence or absence of circumcision or any concomitant disease (connective tissue diseases, diabetes mellitus, or other autoimmune disease).

Histologically it is characterized by a multinodular, mesenchymal proliferation that arises from the corpus cavernosum of the penis. The microscopic features that enable the diagnosis to be reached include the presence of a layer of spindle cells with a stellate pattern and with eosinophilic cytoplasm, set in a fibromyxoid matrix. It is situated in an intravascular position, in the form of nodules that occupy the endothelial lumen. There is no appreciable inflammatory infiltrate and mitoses are uncommon; there is no necrosis. Bundles of smooth muscle cells are observed at the periphery of the tumor. Although not essential for diagnosis of the tumor, immunohistochemical analysis can help in the differential diagnosis with other tumors of similar presentation. Cells are positive for α -smooth muscle actin, vimentin, and desmin (myoid origin) and negative for S-100 (melanocytic), CD34, CD31, epithelial membrane antigen, and factor VIII (endothelial origin). The peripheral stroma of the nodules is positive for CD34, CD31, neuron-specific enolase, and factor VIII antigen. Special stains, such as van Gieson stain, reveal abundant elastic fibers surrounding the nodular structures.^{1,2}

Although tumors of the glans are usually rare, the differential diagnosis does include other tumors that present clinically as asymptomatic nodules, and that require histological differentiation from myointimoma.^{3,4} In particular, these other tumors include myofibroma, nodular fasciitis, leiomyoma, plexiform schwannoma, nerve sheath myxoma, and plexiform fibrohistiocytic

tumor. Of all these, myofibroma is the main diagnosis to be considered, as many authors believe myointimoma to be a form of myofibroma, though arising exclusively in the penis, occupying the lumen of a vessel of the corpora cavernosa; these tumors are histologically identical and have a similar immunohistochemical pattern.⁴

The treatment of choice is surgical excision, though, given the tendency to remain stable and even to undergo involution, conservative management is chosen in the majority of cases. In the series by Fetsch et al,¹ 8 cases underwent remission and only 1 persisted after several years of follow-up; of the 5 cases reported by McKenny,² none recurred after excision, as was also found in the cases reported by Robbins⁵ and Vardar.⁶

We present the case of a 74-year-old man in whom the only past history of note was positive serology for hepatitis C virus and benign prostatic hypertrophy. He was seen for a hard, asymptomatic nodule that had appeared on the glans 4 months earlier. The patient referred no history of trauma. On physical examination, there was a palpable, well-defined nodule of less than 1 cm in diameter, situated on the right side of the glans, close to the coronal sulcus. The nodule was not visible. The skin surface and color were unchanged and there were no signs of inflammation and no accompanying symptoms.

Histopathological study revealed histological changes diagnostic of myointimoma (nodular structures derived from the intima of the cavernous vessels, formed of elongated cells with no atypia or mitoses) (Figures 1 and 2). Due to the benign nature of the lesion, it was decided to perform outpatient follow-up. Ten months after the biopsy, the nodule was still present, with no structural changes, and it remained asymptomatic.

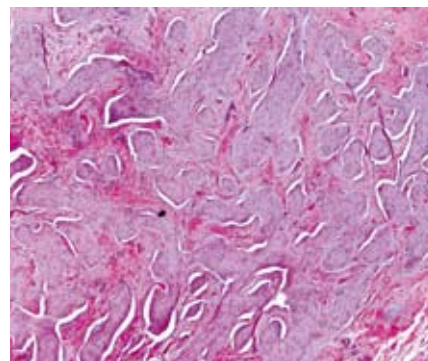
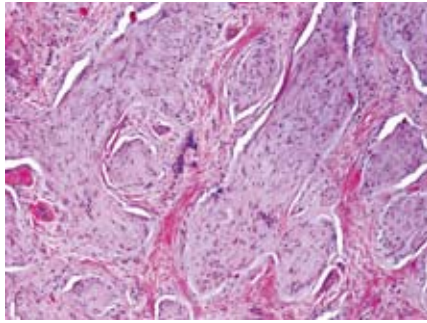


Figure 1. Low magnification histological image of the myointimoma, showing nodular structures that protrude into and completely occupy the vascular lumen (hematoxylin-eosin, $\times 10$).

Figure 2.

At higher magnification, the nodular structures are seen to be made up of spindle cells with a single nucleus, located between bundles of collagen (hematoxylin-eosin, $\times 20$).

**Correspondence:**

Verónica Monsálvez Honrubia
Servicio de Dermatología
Hospital 12 Octubre
Avda. Córdoba, s/n, 28041 Madrid, Spain
monsalvezhonrubia@hotmail.com

Conflicts of Interest

The authors declare no conflicts of interest.

References

1. Fetsch JF, Brinsko RW, Davis CJ Jr, Mostofi FK, Sesterhenn IA. A distinctive myointimal proliferation («myointimoma») involving the corpus spongiosum of the glans penis: a clinicopathologic and immunohistochemical analysis of 10 cases. *Am J Surg Pathol.* 2000; 24:1524-30.
2. McKenney JK, Collins MH, Carretero AP, Boyd TK, Redman JF, Parham DM. Penile myointimoma in children and adolescents: a clinicopathologic study of 5 cases supporting a distinct entity. *Am J Surg Pathol.* 2007;31:1622-36.
3. Katona TM, López-Beltrán A, MacLennan GT, Cheng L, Montironi R, Cheng L. Soft tissue tumors of the penis: a review. *Anal Quant Cytol Histol.* 2006;28:193-206.
4. Val-Bernal JF, Garijo MF. Solitary cutaneous myofibroma of the glans penis. *Am J Dermatopathol.* 1996;18:317-21.
5. Robbins JB, Kohler S. Penile nodule in a 54-year-old man: a case of a myointimoma. *J Am Acad Dermatol.* 2005;53:1084-6.
6. Vardar E, Gunlusoy B, Arslan M, Kececi S. Myointimoma of the glans penis. *Pathol Int.* 2007;57:158-61.

Spinulosis as a Manifestation of Demodicosis

B. Monteagudo,^a M. Cabanillas,^a J.A. García-Rego,^b and C. de las Heras^a

^aServicio de Dermatología and ^bServicio de Anatomía Patológica, Complejo Hospitalario Arquitecto Marcide-Novoa Santos, Ferrol, A Coruña, Spain

To the Editor:

Hyperkeratotic spicules are rare skin lesions of unknown origin, defined by the presence of multiple areas of circumscribed hyperkeratosis formed of keratotic material that protrudes from the stratum corneum.¹ The

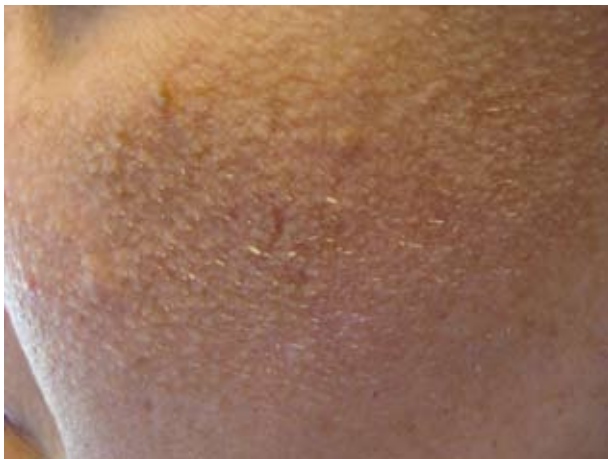

Figure 1. Multiple, filiform, follicular hyperkeratotic lesion on the left cheek.

lesions are seen particularly on the face. The disorder may be idiopathic or associated with various diseases such as hypovitaminosis A, chronic renal failure, Crohn disease, lymphoma, monoclonal gammopathy, and multiple myeloma.^{1,2}

In this letter, we would like to report the case of a 43-year-old woman seen in our department with multiple hyperkeratotic spicules on the left cheek. Histopathology revealed keratotic material and multiple *Demodex folliculorum* in the dilated follicular infundibula.

The patient was a 43-year-old woman with a past history of depression and fibrocystic disease of the breast. She was seen for a 1-year history of multiple, asymptomatic lesions on the left cheek. The patient denied using cosmetics and had not performed any treatment except for facial cleansing with soap and water twice a day.

On examination, there were dozens of yellowish-white, filiform, follicular hyperkeratotic spicules of 1-to-3 mm in height on the left cheek (Figure 1). There was no diffuse facial erythema and there were no similar lesions on other areas of the body.

The laboratory studies performed included complete blood count, biochemistry, protein electrophoresis, alkaline