

CASES FOR DIAGNOSIS

Long-standing Vulvar Pruritus

L. Fuertes, V. Monsálvez, and R. Rivera

Servicio de Dermatología, Hospital 12 de Octubre, Madrid, Spain

Clinical History

The patient was a 19-year-old woman with a past history of type 1 diabetes mellitus and recurrent vulvovaginal candidiasis. She was seen in our outpatient clinic for vulvar pruritus of more than 1 year's duration and that had intensified, even becoming painful.

Physical Examination

Smooth, well-defined, erythematous papules with a diameter of 4 to 5 mm were observed on the internal aspect of the labia majora on physical examination (Figure 1). They were not infiltrated and some were slightly eroded. In addition, there was an abundant, whitish vaginal discharge that was not foul smelling.

Additional Tests

A number of additional tests were performed: serology, which was negative for human immunodeficiency virus, hepatitis C virus, hepatitis B virus, and syphilis; culture of the vaginal discharge, which was positive for *Candida albicans*; and biopsy of 1 of the lesions. Histology revealed skin from the genital region with a superficial erosion occupied by fibrin deposits, marked regenerative changes at the borders, and a dense linear infiltrate in the upper dermis (Figure 2), composed mainly of plasma cells (Figure 3); there were no other apparent changes. Immunohistochemical analysis of the biopsy was performed and was negative for treponemes.

What Was the Diagnosis?

Correspondence:
Laura Fuertes de Vega
Hospital 12 de Octubre
Avda. Córdoba, s/n
28041 Madrid, Spain
cottonmouth_g@hotmail.com

Manuscript accepted for publication November 10, 2008.

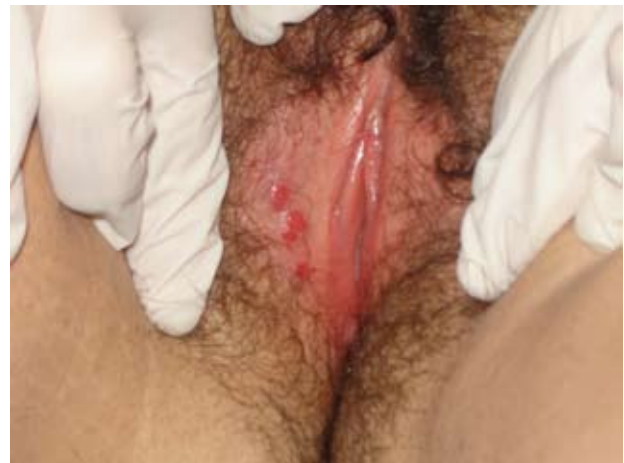

Figure 1.

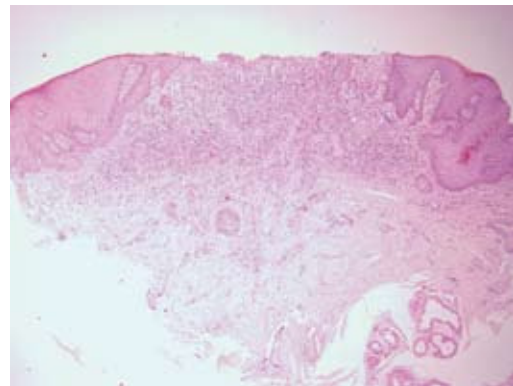


Figure 2. Hematoxylin-eosin, $\times 10$.

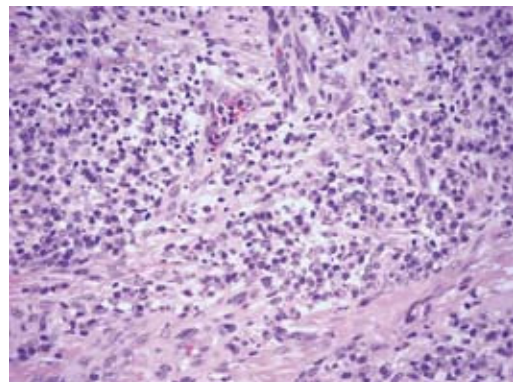


Figure 3. Hematoxylin-eosin, $\times 40$.

Diagnosis

Based on these data, we reached the diagnosis of Zoon vulvitis or plasma cell vulvitis.

Clinical Course and Treatment

Treatment for the candidiasis was given with cycles of oral fluconazole, leading to resolution of both conditions.

Discussion

Zoon or plasma cell vulvitis is a rare condition (less than 40 cases reported in the literature) of unknown etiology, although a number of causes have been proposed (viral,^{1,2} autoimmune,³ hormonal, and irritant). Its pathogenesis is unclear, although many authors describe it as a nonspecific inflammatory response to an undefined exogenous factor, in the presence of numerous predisposing factors: poor hygiene, excessive heat and sweating, trauma, and persistent friction.

Clinically, the disorder presents as lesions on the vulvar mucosa in the form of well-defined, shiny, slightly orange-colored, erythematous papules that are sometimes eroded. They are typically seen on the labia minora and periurethral mucosa and, less commonly, on the labia majora. Occasionally they are associated with purpuric papules described as cayenne pepper spots.

The symptoms are variable, with pruritus, stinging, pain, and even dyspareunia; asymptomatic cases have also been reported. It is important to note that it tends to have a chronic course and does not undergo malignant change.

As the clinical data are relatively nonspecific, the differential diagnosis is extensive: lichen planus, lichen sclerosus et atrophicus, pemphigus vulgaris, contact dermatitis, infections such as syphilis or herpes simplex, various tumors, and other causes such as trauma, Jacquet dermatitis (infantile gluteal granuloma), etc.

Histological study is essential to reach the diagnosis and enables other disorders, principally those of a malignant nature, to be excluded. The main histological findings are the presence of a dense, linear dermal infiltrate formed mainly of plasma cells (more than 50% according to some authors),⁴ and other possible features such as epidermal atrophy with the presence of elongated

(lozenge-shaped) keratinocytes, vascular proliferation with extravasation of red cells, hemosiderin deposits, and an absence of atypia or mitoses. The course of the disease is frequently chronic and resistant to numerous treatments—corticosteroids,^{1,2} estrogens, antifungal agents,⁵ etretinate,⁴ topical cyclosporine, antibiotics, topical misoprostol, cryotherapy, neurologic blockade, interferon,² laser ablation, imiquimod,¹ and surgery have been used although none has proved effective. Our patient achieved complete remission after receiving treatment for her candidiasis, which we considered to be a predisposing factor due to irritation and the consequent scratching of the persistent pruritus.

Cases have been reported with lesions that were clinically and histologically identical to those in the present case, but that were located outside the genital area, mainly on the lips, gums, palate, tongue, epiglottis, larynx,⁶ and conjunctiva; these have been considered to be a response to mechanical trauma, actinic damage, or contact sensitization to chewing gum, toothpaste, mint, etc.

The term plasma cell mucositis is used to describe both the clinical and the histopathological features of this condition.⁶

Conflicts of Interest

The authors declare no conflicts of interest.

References

1. Frega A, Rech F, French D. Imiquimod treatment of vulvitis circumscripta plasmacellularis. *Int J Gynaecol Obstet.* 2006;95:161-2.
2. Morioka S, Nakajima H, Naito K, Iwara K, Ogawa H. Vulvitis circumscripta plasmacellularis treated successfully with interferon alpha. *J Am Acad Dermatol.* 1988;19:947-50.
3. Virgili A, Levratti A, Marzola A, Corazza M. Retrospective histopathologic reevaluation of 18 cases of plasma cell vulvitis. *J Reprod Med.* 2005;50:3-7.
4. Robinson JB, Im DD, Simmons-O'Brien E, Rosenshein NB. Etretinate: therapy for plasma cell vulvitis. *Obstet Gynecol.* 1998;92:706.
5. Scurry J, Dennerstein G, Brenan J, Ostor A, Mason G, Dorevitch A. Vulvitis circumscripta plasmacellularis. A clinicopathologic entity? *J Reprod Med.* 1993;38:14-8.
6. Smith ME, Crighton AJ, Chisholm DM, Mountain RE. Plasma cell mucositis: A review and case report. *J Oral Pathol Med.* 1999;28:183-6.