

## ADVANCES IN DERMATOLOGY

# Update on the Treatment of Alopecia Areata

M. Galán-Gutiérrez, A. Rodríguez-Bujaldón and J.C. Moreno-Giménez

Servicio de Dermatología Médico-Quirúrgica y Venereología, Hospital Universitario Reina Sofía, Córdoba, Spain

**Abstract.** Alopecia areata is nonscarring telogenic alopecia of autoimmune etiology. It is estimated to be the presenting complaint in 2% of dermatologic consultations, and can appear at any age although it is more common in young patients. Treatment depends on several factors, such as extent of the disease and age, and maybe local or systemic. Local treatments aim to achieve hair regrowth, but do not alter the underlying condition, whereas systemic treatments can modify the course of the disease. In neither case does treatment provide a cure. In this article, we review most of the therapeutic options described in the literature for alopecia areata.

**Key words:** alopecia areata, diphenylcyclopropenone, corticosteroids, cyclosporine.

### ACTUALIZACIÓN TERAPÉUTICA EN ALOPECIA AREATA

**Resumen.** La alopecia areata es una alopecia no cicatricial telogénica de base autoinmune. Se estima que origina un 2 % de las consultas dermatológicas y puede aparecer a cualquier edad, aunque es más frecuente en pacientes jóvenes. Su tratamiento va a depender de varios factores, fundamentalmente de la extensión de la enfermedad, de la edad del paciente, así como de medidas locales y sistémicas. Mientras que los tratamientos locales tienen como objetivo conseguir el recrecimiento piloso, sin influir en la evolución de la enfermedad, los tratamientos sistémicos pueden interferir en la evolución de la misma, siendo ambas medidas paliativas. En este trabajo revisamos la mayoría de las opciones terapéuticas descritas en la literatura para la alopecia areata.

**Palabras clave:** alopecia areata, difenciprona, corticoides, ciclosporina.

## Introduction

Alopecia areata (AA) is nonscarring telogenic alopecia of autoimmune etiology. Predisposing genetic factors (as evidenced by the presence of certain human leukocyte antigens [HLAs] such as DQ3, DQ7, DR4, and DR11), a cell-based autoimmune response (CD4<sup>+</sup> T helper cells), association with autoimmune diseases (such as Hashimoto thyroiditis), and external triggers (psychological problems, stress, etc) may all contribute to the pathogenesis of the disease.

It affects both sexes equally and its prevalence in Spain is unknown, although it is thought to affect between 0.5 and 1 individuals per thousand population.<sup>1</sup> Although onset can occur at any age, 60% of new cases present in patients between 5 and 20 years of age.

Clinically, the disease is characterized by the appearance

of alopecic patches or plaques of varying size and number on the scalp. Short exclamation mark hairs (distal end wider than the proximal one) can often be observed.

Although such a presentation (whether as a single patch or multiple ones) is the most common, other clinical presentations such as alopecia totalis (hair loss from the entire scalp), alopecia universalis (loss of body hair as well), ophiasis AA (pattern of hair loss affecting the frontoparietal, temporal, and occipital regions), salsipho AA (hair loss affecting the entire scalp except the peripheral ring), reticular AA (numerous patches of hair loss on the scalp with areas of hair remaining in between), alopecia diffusa (acute and generalized hair loss, which may be hard to diagnose), AA with castling phenomena (alopecia totalis in which one or several tufts of terminal hair remain), AA resembling male/female pattern hair loss (hair loss follows a similar pattern to male-pattern and female-pattern hair loss), and perinevoid AA (hair loss around a melanocytic nevus) may also occur.

Although the most common site of presentation is the scalp, other sites, such as the beard, eyebrows, eyelashes, body, armpits, and pubic region, may also be affected. Nail involvement in the form of pitting or punctate depressions, mottled lunula, onychomadesis, punctate

Correspondencia: Manuel Galán Gutiérrez  
Servicio de Dermatología. Hospital Universitario Reina Sofía  
Av. Menéndez Pidal, s/n  
14004 Córdoba, Spain  
Minos72@hotmail.com

Manuscript accepted July 24, 2008.

leukonychia, trachyonychia (sandpaper-like or shiny), and pseudomycotic pachyonychia may also be present.

## Management

There are no standard guidelines on the therapeutic approach for AA, except for those published in 2003 in the *British Journal of Dermatology*.<sup>2</sup> When considering our therapeutic approach in patients with AA, we must first decide whether or not to treat, as a relatively high proportion of patients will experience spontaneous regrowth of patches of hair loss. The high number of spontaneous remissions, particularly in mild cases, is an obstacle for evaluating the efficacy of treatment. Some trials have been restricted to patients with severe forms of the disease, which are much more resistant to treatment. The lack of efficacy observed for certain treatments in severe forms therefore does not preclude their usefulness in milder disease. Several treatments may stimulate hair growth in AA, but none have been shown to modify the course of the disease. If we decide to treat, we must consider a number of points before starting:

1. Although the psychological repercussions may well be substantial, there is no direct impact of the disease on the general health of the patients to justify the use of treatments associated with risks to the patient, particularly treatments of unproven efficacy.
2. We should bear in mind side effects and long-term and short-term complications associated with treatment.
3. We must evaluate the possible factors likely to be associated with a poor response to treatment, such as alopecia totalis and universalis, the presence of ophiasis, early onset of the disease, and the number and size of patches of hair loss, as well as family history of the disease and whether or not atopy is present.
4. The outcomes should be assessed and possible changes in therapy considered only after a minimum treatment period of 3 months.
5. In cases of extensive AA, the entire scalp should be treated, given that the presence of inflammatory infiltrate in unaffected or apparently healthy areas has been demonstrated. Nevertheless, an untreated area can be left to control for spontaneous repopulation and so provide an indication as to whether treatment should be discontinued.
6. Combined therapies seem more effective than single agents, although this has not been confirmed in controlled studies.
7. A stepwise therapeutic approach should be taken, starting with the least aggressive measures before moving on to more aggressive ones if no response is obtained, depending on the severity of the disease.

## Treatment

There are a series of general measures that we employ in all patients with AA. These include giving an explanation of the disease and the therapeutic options with their risks and benefits; making an assessment of the patients' attitudes and attempting to change negative ones; and providing information on patient groups and associations that can provide psychological support.

We should also remember that—with the exception of contact immunotherapy—few treatments have been tested in randomized trials. We will review the different treatments used in AA, classifying them as topical or systemic. Topical treatments aim to achieve hair regrowth without altering the disease course whereas systemic ones may also influence the underlying disease course while remaining essentially palliative measures. Whenever available, we will make reference to the level of evidence and to the strength of recommendation (Tables 1 and 2).<sup>2</sup>

### Topical Treatments

#### Dithranol

There are only a few reports of case series using dithranol (anthralin) in AA.<sup>3-5</sup> Although the mechanism of action is unknown, the interaction of the drug with different cytokines such as interferons, tumor necrosis factor (TNF), interleukin (IL) 1, and IL-10, point to a nonspecific immunomodulatory effect as possibly responsible for regrowth.<sup>3</sup> The lack of controls in the studies to date makes it hard to determine the level of response, but only a small percentage of patients reported achieving a cosmetically acceptable regrowth. Data published on the topic suggest that frequent applications of high doses are needed to achieve a rapid and effective irritant reaction. Concentrations of between 0.25% and 1%, applied

**Table 1.** Strength of Recommendation

A:	There is solid evidence to support the use of the procedure
B:	There is reasonable evidence to support the use of the procedure
C:	There is only scant evidence to support the use of the procedure
D:	There is reasonable evidence against the use of the procedure
E:	There is solid evidence against the use of the procedure

Adapted from MacDonald Hull SP.<sup>2</sup>

**Table 2.** Level of Evidence

1:	Evidence obtained from at least 1 randomized controlled clinical trial without significant methodological flaws
2-a:	Evidence obtained from nonrandomized clinical trials without significant methodological flaws
2-b:	Evidence obtained from cohort or case-control studies without significant methodological flaws, preferably from more than 1 site or research group
2-c:	Evidence obtained from multiple series compared in time with or without intervention.
	Includes “dramatic” results obtained from uncontrolled studies (such as the results of the introduction of penicillin in the 1940s)
3:	Expert opinion based on clinical experience, descriptive studies, and reports of expert panels
4:	Evidence is inadequate due to methodological problems

Adapted from MacDonald Hull SP.<sup>2</sup>

overnight, can be used. Alternatively, so-called “short-contact therapy” may be used, which involves applications of 30 minutes with progressive increases until reaching an exposure of 1 hour. The effect is slow and several months may be needed to achieve an acceptable cosmetic outcome. The dark brown coloring of the follicular orifices that may bother some patients can be prevented if the product is removed with warm water.<sup>6</sup> Level of evidence 4 and strength of recommendation C.<sup>2</sup>

### Topical Cyclosporine

Gilhar et al<sup>7</sup> failed to find a favorable response after 12 months’ use of 10% cyclosporine in oil in 10 patients.<sup>7</sup> Other clinical trials have assessed the efficacy of topical cyclosporine in AA without satisfactory results.<sup>8,9</sup> A recent publication reports the use of a mixture of ethanol and phospholipids in the formulation of new topical cyclosporine preparations in order to increase penetration.<sup>10</sup>

### Corticosteroids

*Topical corticosteroids.* The clinical efficacy of topical corticosteroids in AA is subject to much controversy. Although there is little evidence for hair regrowth, potent topical corticosteroids are widely used. A randomized clinical trial compared a cream containing 0.25% desoximetasone with placebo in patients with patchy AA and found no significant treatment effect.<sup>11</sup> Other

studies reported different findings; Mancuso et al<sup>12</sup> found that topical application of betamethasone valerate foam, twice a day for 12 weeks, was effective in the treatment of AA with an extension of less than 25% while Tosti et al<sup>13</sup> evaluated 0.05% clobetasol propionate under occlusion, applied daily 6 days a week for 6 months, and observed hair regrowth from week 6 of treatment onwards in patients with alopecia totalis and universalis, although with frequent relapses. Recently, a study, also by Tosti and coworkers,<sup>14</sup> obtained good results in a randomized, double-blind, placebo-controlled trial with 0.05% clobetasol propionate foam, with regrowth of more than 50% observed in 25% of the patients. The most frequent side effect is folliculitis, although other adverse reactions such as erythema, acneiform eruption, atrophic striae, telangiectasis, and hypertrichosis can also occur. In general, this agent is not used alone but in combination with minoxidil or anthralin. Level of evidence 3 and strength of recommendation C.<sup>2</sup>

*Intralesional corticosteroids.* Intradermal corticosteroids alone or in combination with another agent to treat single or multiple patches of AA are popular with dermatologists. The most widely used drug is triamcinolone acetonide, with regrowth in up of 60% after several sessions.<sup>15</sup> Porter and Burton<sup>16</sup> also achieved good results with this method, using triamcinolone acetonide and hexacetonide for more than 9 months. Several intradermal injections approximately 1 cm apart were performed every 4 to 6 weeks (Figure 1). The drugs generally used are triamcinolone acetonide (40 mg/mL), paramethasone acetate (20 mg/mL), and betamethasone (3 mg of betamethasone acetate and 3 mg of betamethasone sodium phosphate). After each injection, a gentle massage of the treated area is recommended to help prevent treatment-induced atrophy. Injections in frontoparietal areas are not recommended because of the potential risk of thrombosis in the central retinal artery due to the formation of crystalline deposits. Ferrando and Moreno<sup>17</sup> propose the use of mesotherapy multi-injectors with 5 or 7 needles, an approach which has the advantage of optimizing the process while economizing on product use and ensuring homogeneity, with a shorter application time and a decrease in painful injections.<sup>17</sup> This then is a useful method in cases of patchy AA of less than 50% extension, especially at the onset of the disease or when the patient fails to respond to other therapeutic measures. It is also useful in certain cosmetically sensitive sites such as the outer eyebrows (although particular care should be taken at this site due to the risk of cataracts and increased intraocular pressure<sup>18</sup>). This treatment is not appropriate in rapidly progressing or very extensive forms. Level of evidence 3 and strength of recommendation B.<sup>2</sup>

## Minoxidil

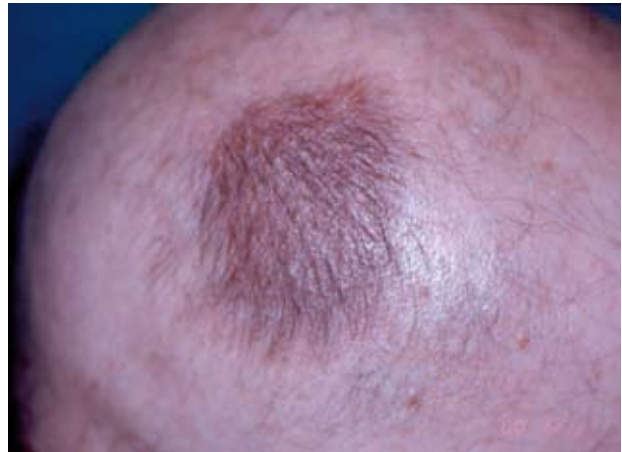Despite numerous experimental studies, the exact mechanism of action of minoxidil is not known, although it appears to prolong the anagen phase of the hair follicle. Fenton and Wilkinson<sup>19</sup> undertook a double-blind study that confirmed the greater hair growth in patients treated with topical 1% minoxidil compared to placebo. Subsequent studies using concentrations of 1% and 3% have not found similar results.<sup>20,21</sup> A study has been conducted to compare the 1% formulation with the 5% formulation, and it was found that regrowth appeared more frequently in the group treated with the 5% formulation, although few of the patients reported esthetically pleasing outcomes.<sup>22</sup> This drug may therefore be useful in treatment of patchy AA but not alopecia totalis or universalis. It is generally used at a concentration of 5% in combination with a topical corticosteroid or anthralin, which enhance its action by increasing absorption. A product combining minoxidil (2%-5%) with clobetasol propionate (0.05%) and, optionally, retinoic acid (0.025%-0.05%) in a shampoo can also be used. However, clinical studies confirming the usefulness of such combinations are not available. Likewise, 2% minoxidil has also been used in combination with systemic corticosteroids because this seems to limit hair loss after suspending corticosteroid therapy.<sup>23</sup> The side effects reported include allergic and irritant contact dermatitis, and localized facial hypertrichosis. Level of evidence 4 and strength of recommendation C.<sup>2</sup>

## Topical Immunotherapy

The mechanism of action of topical immunotherapy is unknown, although the following different factors have been postulated as responsible for hair regrowth<sup>24-26</sup>:

1. An immunomodulatory effect that alters the ratio, in the peribulbar region, of CD4<sup>+</sup> to CD8<sup>+</sup> cells, and changes the site of inflammatory infiltrate, which shifts from the peribulbar region to the interfollicular region and the dermis.
2. Elimination of the antigenic stimulus, because the new T-cell population attracted by the contact immunogen would decrease the stimulatory effect of the preexisting population.
3. Antigenic competition, in which the reaction triggered is responsible for a nonspecific inhibition of the immune response mediated by the suppressor T cells.
4. Inhibition of proinflammatory cytokine production.

In short, the technique consists of sensitizing the patient with a laboratory allergen that is not normally found in the environment. Once obtained, the substance is applied to the affected area. A delayed eczematous reaction will



**Figure 1.** Regrowth in an alopecic area treated by infiltration of triamcinolone acetonide.

appear, giving rise to an inflammatory infiltrate that is able to displace the AA-specific lymphocytic infiltrate and therefore allow hair regrowth.

A review of all the articles published on contact immunotherapy concluded that 50% to 60% of the patients experienced worthwhile regrowth, although the range of response was very broad (9% to 87%)<sup>27</sup> and lower in those patients with more extensive alopecia. In most studies, treatment was discontinued if a response was not apparent after 24 weeks.

In children with AA, 2 case reports described degrees of response of around 30%.<sup>28,29</sup> In a third study, similar findings were reported in children with severe AA, although substantial benefit was obtained in fewer than 10%.<sup>30</sup>

The adverse drug reactions to topical immunotherapy include enlargement of cervical lymph nodes during the sensitization phase, though this is usually transient. Other reactions include severe dermatitis (which is reduced by decreasing the concentration of the applied product), while urticaria<sup>31</sup> and vitiligo<sup>32,33</sup> have also been reported.

Health professionals and family members who apply the product should be careful about taking protective measures to avoid becoming sensitized themselves. Safety data are not available on the use of contact immunotherapy in pregnant women, and so it should be avoided in such cases and in women who are attempting to get pregnant. Level of evidence 3-b and strength of recommendation B.<sup>2</sup> Three substances are used in this type of therapy:

*Dinitrochlorobenzene (DNCB)*. This was the first such drug to be used. Initially the patient is sensitized with a 1% to 2% solution. Once sensitization has been

demonstrated by patch testing, topical applications of the product with very diluted concentrations—of the order of 0.0001%—are made, with adjustments made to that concentration according to clinical response. The goal is to induce mild allergic contact dermatitis (hardly any erythema) that can stimulate the growth of hair. DNCB is no longer used today due to its mutagenic properties and the risk of carcinogenesis.

*Squaric acid dibutyl ester (SADE)*. In the opinion of some authors this is the ideal allergen because of its sensitizing potency, the fact that it is not found in the environment, and the lack of cross reactivity with other chemicals. It does have a drawback though—it is not very stable in acetone.<sup>34</sup> Sensitization is performed with a 2% solution of SADE in acetone. After 3 weeks, treatment is started with weekly topical applications of the solution at an initial concentration of 0.00001% with progressive increases up to concentrations as high as 1% depending on the clinical response obtained. The clinical goal of the increases in concentration is none other than to induce weak contact eczema with predominance of erythema and pruritus.

*Diphenzippone or diphenylcyclopropenone (DPCP)*. This is the most widely used sensitizing agent at present, perhaps because it is the most stable. The first step in using this product is sensitization, achieved with daily applications of a 2% solution of the product to a convex area (back of the neck or arm) until an eczematous reaction occurs. Subsequently, patch tests are undertaken by applying dilutions of the chemical to the back to determine the minimum concentration needed to induce a reaction. This concentration will be the starting one for treatment, which consists of application of the solution every day or every other day, initially, as above, with the minimum concentration able to induce a mild eczematous reaction. If no effect is apparent, the concentration is increased until a reaction occurs, and this concentration is then taken as the ideal one. When the maximum response is reached, the number of applications is reduced, and then the drug is discontinued if complete regrowth is attained. Relapses, should they occur, will generally respond to a new cycle of immunotherapy, although response is not guaranteed. Regrowth generally appears after 12 weeks of treatment, although acceptable cosmetic regrowth may take longer, up to 24 weeks. The response rate ranges from 30% to 50%, with relapses in half the cases. If no response is observed after 24 weeks, further applications are not recommended. DPCP is light sensitive, and so solutions should be kept in dark places (usually in a refrigerator). Patients should be advised to wear a hat, cap, or wig after application of the product if they are going outside or

plan to undertake any activity in which light may come into contact with the treated area.

*Nickel*. Those individuals who have become sensitized to nickel are eligible to use this substance as a sensitizing agent. The metal is applied as a 1% nickel sulfate solution in petroleum jelly in similar fashion to that described above, every day or every other day.<sup>35,36</sup>

### Phototherapy and Photochemotherapy

In 2001, Behrens-Williams et al<sup>37</sup> reported hair regrowth in 6 patients with AA refractory to other treatments after applying a 0.0001% solution (1 g/L) of 8-methoxypsoralen (8-MOP) at 37°C to the scalp for 20 minutes with subsequent exposure to UVA radiation (PUVA-turban). The treatment regimen consisted of 3 to 4 sessions per week, with an irradiation dose of 0.3 to 8 J/cm<sup>2</sup> and a total flux of 60 to 170 J/cm<sup>2</sup> over a 24-week treatment period.

Another study that included patients with multiple patches of AA refractory to treatment with topical corticosteroids used topical protoporphyrin and UVA radiation; hair regrowth was observed in 2 out of 3 patients treated after 3 and 4 months of treatment.<sup>38</sup> Two retrospective reviews have reflected low response rates and suggested that response is no better than what would be observed in the natural disease course.<sup>39,40</sup>

Although the erythema induced by UVB radiation is similar to that produced by other irritants, there is little evidence in the literature of the efficacy of this technique.<sup>2</sup> Level of evidence 3 and strength of recommendation C.<sup>2</sup>

### Prostaglandin Analogues

Latanoprost is an analogue of prostaglandin F<sub>2α</sub>. The drug is indicated for treating glaucoma and its use in alopecia of the eyebrows was proposed after eyelash growth was detected in glaucoma patients.<sup>41</sup> Subsequently, a similar effect was observed in patients with other analogues such as bimatoprost.<sup>42</sup> Nevertheless, recently, the lack of efficacy of latanoprost has been reported in the treatment of AA of the eyebrows, and so its use remains the subject of debate.<sup>43</sup>

### Tacrolimus

The results of tacrolimus use in a number of animal models of AA have been positive,<sup>44,45</sup> and so the product has been tried in the treatment of AA in humans, but with inconsistent results.

In a study published recently by the *Journal of the American Academy of Dermatology*, no benefit was observed in using 0.1% tacrolimus in 11 patients who

completed the study, although 1 patient did show minor regrowth.<sup>46</sup>

### Imiquimod

Like tacrolimus, the clinical outcomes obtained with imiquimod have been inconsistent: some authors have reported regrowth whereas others have found no response.<sup>47</sup> The most recent article is a report of transient hair regrowth in a 15-year-old girl affected by alopecia universalis since she was 8 years old.<sup>48</sup>

### Intralesional Candidin

In 2006, the efficacy of treatment by intralesional antigenic stimulation with candidin was reported (0.5 mL every 4 to 6 weeks). This represents an alternative form of immunotherapy that may be easy to administer and at least as effective as DPCP. Intralesional injection of antigens to *Candida albicans* was successfully used as an immunostimulatory treatment in recalcitrant warts.<sup>49</sup> The treatment is generally well tolerated, although some patients present with fever lasting 3 to 4 days and tender swollen cervical lymph nodes. Hair regrowth usually starts after 2 months of treatment and full recovery occurs after 8 or 10 sessions, even in untreated areas such as the eyebrows.<sup>50</sup>

### Topical Rubefaciants

A 5% solution of cantharides (which includes 10% chloral hydrate in sufficient quantity of Hoffman anodyne for 100 mL), phenol, benzoyl peroxide, and other substances may be useful in the case of small patches. However, there are no controlled clinical studies to confirm their supposed efficacy.

### Laser Therapy

Given that excimer lasers operating at 308 nm induce T-cell apoptosis in vitro, and that AA is an autoimmune disorder in which T cells are implicated, Zakaria et al<sup>51</sup> suggested that such a laser might be beneficial in the treatment of this disease. Nine patients with patchy AA underwent 2 sessions a week for up to a maximum of 24 sessions. The authors observed hair regrowth in all patients, and this was sustained for at least 3 months of follow-up. The only side effects described were erythema and mild hyperpigmentation. Treatment was well tolerated and so the authors suggested that this type of excimer laser could be a good therapeutic option.<sup>51</sup> In another study, Waiz et al<sup>52</sup> observed regrowth in 90% of the patches of hair loss after 4 sessions a week of therapy with diode laser light at 904 nm.<sup>52</sup> However, further studies are needed to confirm these findings.

### Garlic Acid and Betamethasone Valerate

Recently, the efficacy of a combination of 5% garlic gel with 0.1% betamethasone valerate has been reported.<sup>53</sup> The study compared 20 patients treated with this combination and 20 patients who only received the betamethasone cream. Good and moderate responses were obtained in 19 patients in the treatment group compared to 1 in the control group, and so the authors concluded that the combination may be useful for treating patchy AA.<sup>53</sup>

## Systemic Therapies

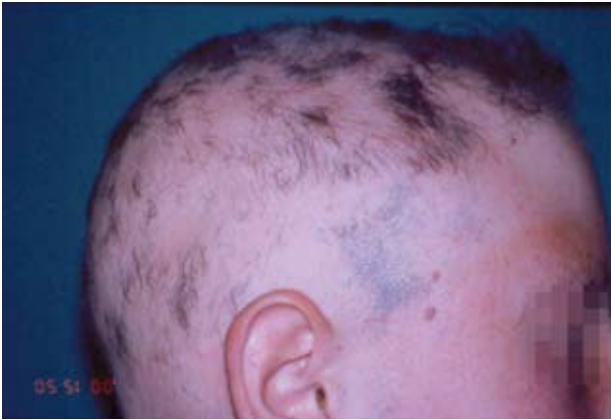### Systemic Corticosteroids

*Continuous systemic oral corticosteroids.* Long-term therapy with oral corticosteroids may lead to hair regrowth in some patients. In a small, partially controlled study, between 30% and 47% of the patients who received treatment with oral prednisolone for 6 weeks (starting dose of 40 mg/d) showed more than 25% regrowth.<sup>23</sup> Unfortunately, continuous treatment was necessary in most of the patients to maintain the regrowth while the response was generally not sufficient to justify exposing the patients to the risks associated with prolonged systemic corticosteroid use. Indeed, the frequent relapses when tapering the dose, the need for prolonged treatment, and the associated side effects would seem to limit the use of these drugs.<sup>54</sup>

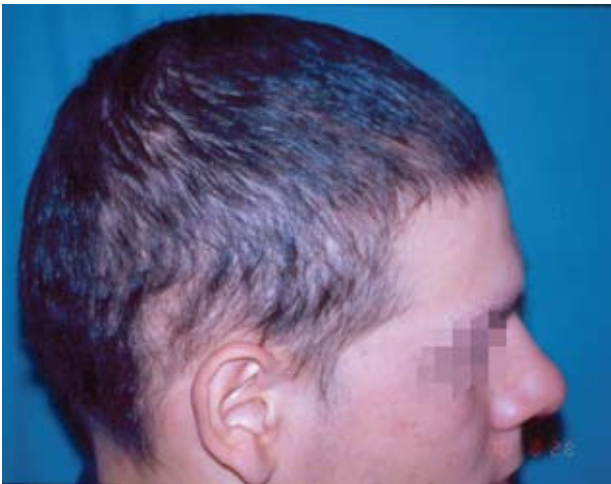*Pulsed systemic corticosteroids.* One way to minimize the side effects of systemic corticosteroids is to use them in the form of pulses; several modalities for use of high doses in the form of pulses in different oral and intravenous regimens have been reported:

1. Intravenous methylprednisolone 250 mg administered twice a day in adults or 5 mg/kg twice a day in children for 3 consecutive days, once a month<sup>55</sup>
2. Intravenous prednisolone 2 g as a single dose or 0.5 g/d administered orally for 5 consecutive days<sup>56</sup>
3. Oral prednisolone 300 mg once a month<sup>57</sup>
4. Oral dexamethasone 5 mg twice a week<sup>58</sup>
5. Oral betamethasone 5 mg twice a week (0.1 mg/kg in children)<sup>59</sup>

Differences in the treatment protocols and patient selection hinder direct comparison of these studies, none of which were controlled. In general, around 60% of the patients with extensive patchy AA showed a cosmetically worthwhile response whereas only 10% of the patients with ophiasic forms and alopecia totalis or universalis responded.<sup>2</sup> Oral and intravenous routes of administration appear equally effective. Our experience with this type of treatment has been good (Figures 2 and 3). Level of evidence 3 and strength of recommendation C.<sup>2</sup>



**Figure 2.** Image prior to treatment with pulsed intravenous corticosteroids.



**Figure 3.** Outcome after 6 months' treatment with 500 mg/d of intravenous methylprednisolone for 3 consecutive days a month. Regrowth can be observed on almost 90% of the scalp.

### Cyclosporine

The use of cyclosporine in the treatment of AA is controversial given that cases of this disease have been reported in transplanted patients receiving immunosuppressor treatment with cyclosporine.<sup>60,61</sup> However, it is known that cyclosporine stimulates T cells and the pilosebaceous unit, thereby inducing hypertrichosis and sebaceous hyperplasia. Some investigators have reported regrowth with the use of cyclosporine, although high doses have been necessary for a prolonged period, with relapse after discontinuation.<sup>62</sup> Other authors, such as Shapiro et al<sup>63</sup> have improved

outcomes by combining cyclosporine A with low doses of prednisone.<sup>63</sup> Level of evidence 3 and strength of recommendation D.<sup>2</sup>

### Methotrexate

Methotrexate is an immunosuppressor that is widely used in the treatment of chronic autoimmune diseases such as psoriasis. Joly<sup>64</sup> achieved good results in the treatment of AA with methotrexate alone or in combination with low doses of oral corticosteroids. Of the 22 patients evaluated, 6 took methotrexate alone (15-25 mg/wk) while 16 took a combination with corticosteroids (10-20 mg/d of prednisone). Regrowth was observed in 14 patients, 3 of whom were taking methotrexate alone and 11 the combination. Of these 14 patients, 6 discontinued methotrexate; the treatment effect was sustained after discontinuation in 3 and the other 3 relapsed but responded to a further cycle of methotrexate. Although this was an uncontrolled study, the results do suggest that treatment with a combination of methotrexate and low steroid doses may be useful in severe forms of AA.<sup>64</sup> Nevertheless, more studies are needed to be able to draw clear conclusions on the topic.

### Sulfasalazine

Salazopyrin, also known as sulfasalazine, is an anti-inflammatory drug that inhibits the release of IL-2 and prostaglandin E2, thereby reducing chemotaxis of inflammatory cells.<sup>65</sup> It also inhibits cytokines and antibody production, and probably acts on certain T-cell subpopulations. Given that some anti-IL-2 drugs such as cyclosporine have been used in the treatment of this disease, a number of authors have suggested using sulfasalazine. Although some studies report hair regrowth with this treatment (with doses ranging from 500 mg/d to 1.5 g/d), relapse once the treatment is discontinued is common.<sup>66,67</sup>

### Immunomodulators

**Biotin.** Camacho and García<sup>68</sup> have used biotin at oral doses of 20 mg/d in combination with oral zinc aspartate 100 mg/d and topical 0.025% clobetasol propionate to treat AA in children. The outcomes were good (regrowth occurred in 5 of the 9 patients treated) with no local or systemic side effects. Likewise, Ferrando et al<sup>69</sup> have suggested a beneficial effect of long-term oral treatment with 10 mg/d in children.<sup>69</sup> The possible mechanism of action for this effect is unknown.

**Zinc.** Zinc sulfate at a dose of 200 to 600 mg/d has been used in the treatment of AA with inconsistent

results.<sup>70</sup> As mentioned above, zinc aspartate at doses of 100 mg/d has been used in combination with biotin and the topical application of clobetasol in the treatment of children with AA with good outcomes.<sup>71</sup>

### Biologic Therapies

For some time now, the so-called biologic agents have been extending the therapeutic arsenal available to dermatologists. Within dermatology, these products—which are proteins designed to block specific molecular mechanisms—have been used mainly for treating psoriasis. However, there are an increasing number of references in the literature to the use of these drugs in patients with AA. There have been reports of patients receiving anti-TNF- $\alpha$  drugs (infliximab, etanercept, and adalimumab) who developed AA, suggesting that TNF- $\alpha$  does not play a primary role in the pathogenesis of the disease.<sup>72,73</sup> In contrast, recently, good outcomes with biologic agents such as efalizumab and alefacept that block T cells have been reported. Efalizumab is a humanized anti-CD11a monoclonal antibody, CD11a being a component of lymphocyte function-associated antigen (LFA). Spectacular improvement in a case of alopecia universalis associated with atopic dermatitis and autoimmune thyroiditis has been reported with a initial dose of 0.7 mg/kg and subsequent doses of 1 mg/kg, as used in psoriasis.<sup>74</sup> Hair regrowth appeared after 1 month, and by 6 months of treatment, had reached 90%. Recently, another study published in March 2008 in the *Journal of the American Academy of Dermatology* did not find this drug to be effective in 62 patients with moderate to severe AA who received a 12-week treatment course.<sup>75</sup> Alefacept is a fusion protein formed from the extracellular domain of LFA-3 bound to the fragment-crystallizable region of immunoglobulin G1. It binds to CD2 on memory T cells thereby preventing their activation and inducing apoptosis.<sup>76</sup> In a study published recently of 4 patients with severe AA, alefacept was administered as a weekly intermuscular dose of 15 mg for 12 weeks. Patients were assessed every 4 weeks from the start of treatment until completion. Subsequently, they were assessed every 4 weeks after finishing treatment until completing 15 weeks of follow-up, when they made the final study visit. All patients showed an improvement in AA. These improvements were of 90%, 50%, 7%, and 5%. In fact, 2 patients received a further cycle of alefacept for 12 more weeks, starting from when they had completed the first 12 weeks of treatment. All patients tolerated treatment well, with no changes in the total CD4<sup>+</sup> T-cell count, which remained within normal limits at all times. Another case report has recently been published with good results after use of alefacept in a 21-year-old woman suffering

from alopecia universalis.<sup>76</sup> She achieved complete regrowth after a 12-week cycle of treatment. Therefore, despite the limited number of patients, this therapeutic approach opens up new possibilities in the treatment of AA in certain cases, although further studies are needed to draw firm conclusions.<sup>77</sup>

### Miscellaneous Treatments

*Thalidomide.* This drug is a potent suppressor of IL-2 and therefore strongly inhibits T-helper-cell-mediated immune response. Some authors have suggested its use in cases of recalcitrant AA. For example, Namaz<sup>78</sup> obtained good results although that study was open-label and lacked a control group. More studies with an appropriate design are needed to draw firm conclusions about this drug.

*Aromatherapy.* In a double-blind, randomized study, Hay et al<sup>79</sup> found regrowth of patches of hair loss in 44% of the patients treated with essential oils extracted from thyme, rosemary, lavender, and cedar, compared to 15% in individuals in the control group, who only received the oils (jojoba and grape) used as a vehicle for the essential oils. The group differences were statistically significant ( $P=.008$ ).

*Soy oil.* McElwee et al<sup>80</sup> have suggested that soy oil and the phytoestrogen genistein can protect against the appearance of AA in an experimental murine model, although such an effect has yet to be demonstrated in humans.

*Imipramine.* In a double-blind study, Peirini et al<sup>81</sup> compared 7 patients with AA treated with imipramine and patients given placebo. They observed hair regrowth in the active-treatment group, along with an improvement in psychological state in both groups (active treatment and control). However, the mechanism of action for regrowth using this drug is not known and the sample was too small to enable firm conclusions to be drawn.<sup>81</sup>

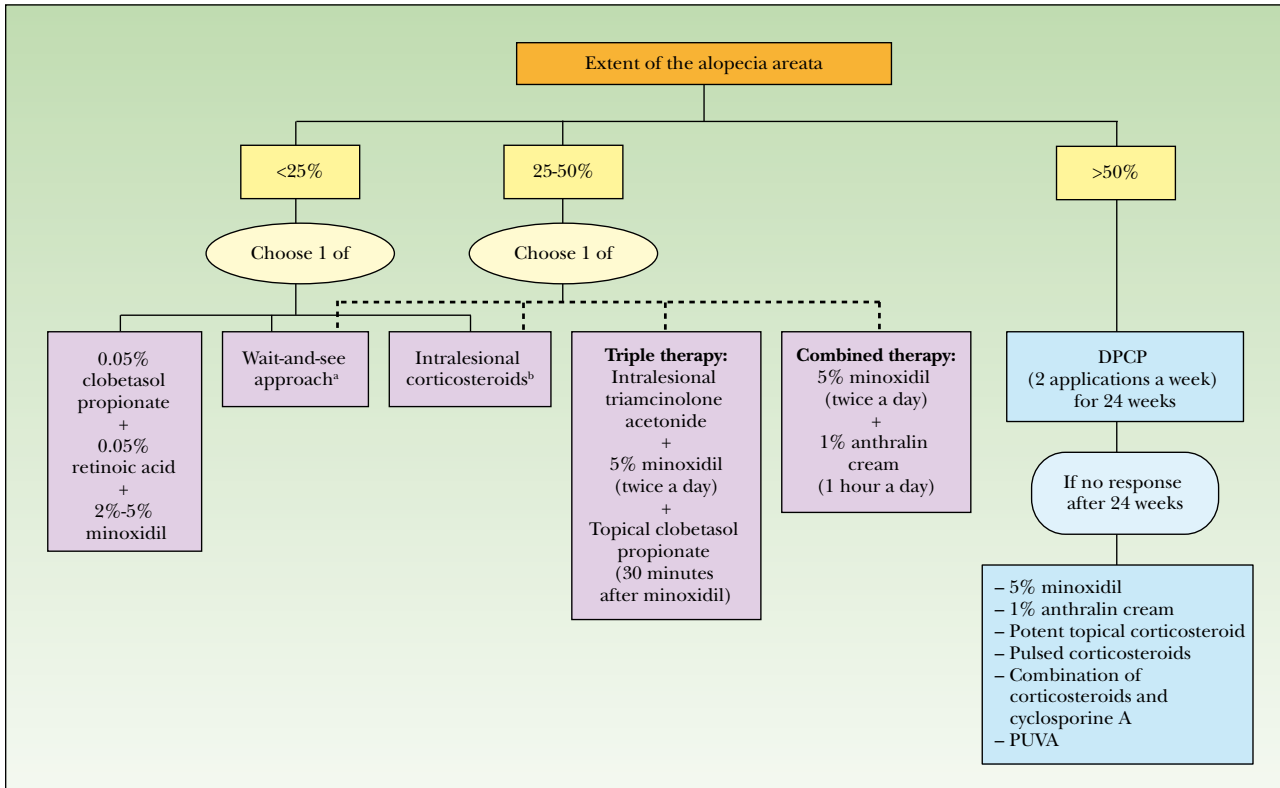
### Treatment Algorithm

In summary, the treatment of each patient should be tailored to individual needs. The therapeutic approach should consider the severity of the condition, its repercussion for the patient, and the chances of success. It is extremely important to assess the risk/benefit ratio for each case, and start with safer treatments and progress to potentially riskier ones with more severe disease and according to therapeutic response. Figure 4 shows the treatment algorithm.

### Conflicts of Interest

The authors declare no conflicts of interest.





**Figura 4.** Treatment decision algorithm for alopecia areata. DPCP indicates diphenylcyclopropanone; PUVA, psoralen UV-A.

<sup>a</sup> Spontaneous regrowth may occur in 50% of the cases without treatment, particularly in localized forms.

<sup>b</sup> Triamcinolone acetonide 5 mg/mL, 2 mL in 20 injections of 0.1 mL every 4 to 6 weeks. Evaluate response at 4 to 8 weeks; if there is no response after 3 to 4 months, consider switching therapies. In children, add biotin 10 to 20 mg/d.

## References

- García Hernández MJ, Camacho Martínez F. Epidemiología clínica de la alopecia areata. *Actas Dermosifiliogr.* 2002;93:223-8.
- MacDonald Hull SP, Wood ML, Hutchinson PE, Sladden M, Messenger AG; British Association of Dermatologists. Guidelines for the management of alopecia areata. *Br J Dermatol.* 2003;149:692-9.
- Fiedler-Weiss VC, Buys CM. Evaluation of anthralin in the treatment of alopecia areata. *Arch Dermatol.* 1987;123:1491-3.
- Nelson DA, Spielvogel RL. Anthralin therapy for alopecia areata. *Int J Dermatol.* 1985;24:606-7.
- Schmoeckel C, Weissmann I, Plewig G, Braun-Falco O. Treatment of alopecia areata by anthralin-induced dermatitis. *Arch Dermatol.* 1979;115:1254-5.
- Fiedler VC, Alaiti S. Treatment of alopecia areata. *Dermatol Clin.* 1996;14:733-8.
- Gilhar A, Pillar T, Etzioni A. Topical cyclosporin A in alopecia areata. *Acta Derm Venereol.* 1989;69:252-3.
- Mauduit G, Lenvers P, Barthelemy H, Thivolet J. Treatment of severe alopecia areata with topical applications of cyclosporin A. *Ann Dermatol Venereol.* 1987;114:507-10.
- DeProst Y, Teillac D, Paquez F, Carrugi C, Bachelez H, Touraine R. Treatment of severe alopecia areata by topical applications of cyclosporine: comparative trial versus placebo in 43 patients. *Transplant Proc.* 1988;20:112-3.
- Verma DD, Fahr A. Synergistic penetration enhancement effect of ethanol and phospholipids on the topical delivery of cyclosporin A. *J Control Release.* 2004;97:55-66.
- Charuwichitratana S, Wattanakrai P, Tanrattanakorn S. Randomized double-blind placebo-controlled trial in the treatment of alopecia areata with 0.25 % desoximetasone cream. *Arch Dermatol.* 2000;136:1276-7.
- Mancuso G, Balducci A, Casadio C, Farina P, Staffa M, Valenti L, et al. Efficacy of betamethasone valerate foam formulation in comparison with betamethasone dipropionate lotion in the treatment of mild-to-moderate alopecia areata: a multicenter, prospective, randomized, controlled, investigator-blinded trial. *Int J Dermatol.* 2003;42:572-5.
- Tosti A, Piraccini BM, Pazzaglia M, Vicenzi C. Clobetasol propionate 0,05 % under occlusion in the treatment of alopecia totalis/universalis. *J Am Acad Dermatol.* 2003;49:96-8.
- Tosti A, Iorizzo M, Botta GL, Milani M. Efficacy and safety of a new clobetasol propionate 0.05 % foam in alopecia areata: a randomized, double-blind placebo-controlled trial. *J EADV.* 2006;20:1243-7.
- Kubeyinje EP. Intralesional triamcinolone acetonide in alopecia areata amongst 62 Saudi Arabs. *East Afr Med J.* 1994;71:674-5.

16. Porter D, Burton JL. A comparison of intra-lesional triamcinolone hexacetonide and triamcinolone acetonide in alopecia areata. *Br J Dermatol.* 1971;85:272-3.
17. Ferrando J, Moreno-Arias GA. Multi-injection plate for intralesional corticosteroid treatment of patchy alopecia areata. *Dermatol Surg.* 2000;26:690-1.
18. Carnahan MC, Goldstein DA. Ocular complications of topical, peri-ocular, and systemic corticosteroids. *Curr Opin Ophthalmol.* 2000;11:478-83.
19. Fenton DA, Wilkinson JD. Topical minoxidil in the treatment of alopecia areata. *Br Med J.* 1983;287:1015-7.
20. Vestey JP, Savin JA. A trial of 1 % minoxidil used topically for severe alopecia areata. *Acta Derm Venereol.* 1986;66:179-80.
21. Ranchoff RE, Bergfeld WF, Steck WD. Extensive alopecia areata. Results of treatment with 3 % topical minoxidil. *Cleve Clin J Med.* 1989;56:149-54.
22. Fiedler-Weiss VC. Topical minoxidil solution (1 % and 5 %) in the treatment of alopecia areata. *J Am Acad Dermatol.* 1987;16:745-8.
23. Olsen EA, Carson SC, Turney EA. Systemic steroids with or without 2 % topical minoxidil in the treatment of alopecia areata. *Arch Dermatol.* 1992;128:1467-73.
24. Happle R, Klein H, Macher E. Topical immunotherapy changes in the composition of the peribulbar infiltrate in alopecia areata. *Arch Dermatol Res.* 1986;278:214-8.
25. Happle R. Antigenic competition as a therapeutic concept for alopecia areata. *Arch Dermatol Res.* 1980;267:109-14.
26. Goldsmith L. Summary of alopecia areata research workshop and future research directions. *J Invest Dermatol.* 1991;96:98-100.
27. Rokhsar CK, Shupack JL, Vafai JJ, Washenik K. Efficacy of topical sensibilizers in the treatment of alopecia areata. *J Am Acad Dermatol.* 1998;39:751-61.
28. MacDonald Hull SP, Pepall L, Cunliffe WJ. Alopecia areata in children: response to treatment with diphencyprone. *Br J Dermatol.* 1991;125:164-8.
29. Schuttelaar ML, Hamstra JJ, Plinck EP, Peereboom-Wynia JD, Vuzevski VD, Mulder PG, et al. Alopecia areata in children: treatment with diphencyprone. *Br J Dermatol.* 1996;135:581-5.
30. Tosti A, Guidetti MS, Bardazzi F, Misciali C. Long-term results of topical immunotherapy in children with alopecia totalis or alopecia universalis. *J Am Acad Dermatol.* 1996;35:199-201.
31. Tosti A, Guerra L, Bardazzi F. Contact urticaria during topical immunotherapy. *Contact Dermatitis.* 1989;21:196-7.
32. Henderson CA, Ilchyshyn A. Vitiligo complicating diphencyprone sensitization therapy for alopecia areata. *Br J Dermatol.* 1995;133:496-7.
33. MacDonald Hull SP, Norris JF, Cotterill JA. Vitiligo following sensitisation with diphencyprone. *Br J Dermatol.* 1989;120:323.
34. Wilkerson MG, Henkin J, Wilkin JK. Squaric acid and esters: analysis for contaminants and stability in solvents. *J Am Acad Dermatol.* 1985;13:229-34.
35. García-Bravo B, Rodríguez-Pichardo A, Sánchez-Pedreno P, Camacho F. Nickel sulphate in the treatment of alopecia areata. *Contact Dermatitis.* 1989;20:228-9.
36. Suárez Martín E. Treatment of alopecia areata profiting from «natural» allergy to nickel. *Arch Dermatol.* 1984;120:1138-9.
37. Behrens-Williams SC, Leiter U, Schiener R, Weidmann M, Peter RU, Kerscher M. The PUVA-turban as a new option of applying a dilute psoralen solution selectively to the scalp of patients with alopecia areata. *J Am Acad Dermatol.* 2001;44:248-52.
38. Monfrecola G, D'Anna F, Delfino M. Topical hematoporphyrin plus UVA for treatment of alopecia areata. *Photodermatology.* 1987;4:305-6.
39. Taylor CR, Hawk JL. PUVA treatment of alopecia areata partialis, totalis and universalis: audit of 10 years' experience at St John's Institute of Dermatology. *Br J Dermatol.* 1995;133:914-8.
40. Healy E, Rogers S. PUVA treatment for alopecia areata—does it work? A retrospective review of 102 cases. *Br J Dermatol.* 1993;129:42-4.
41. Mehta JS, Raman J, Gupta N, Thong D. Cutaneous latanoprost in the treatment of alopecia areata. *Eye.* 2003;17:444-6.
42. Tosti A, Pazzaglia M, Voudouris S, Tosti G. Hypertrichosis of the eyelashes caused by bimatoprost. *J Am Acad Dermatol.* 2004;51:149-50.
43. Ross EK, Bolduc C, Lui H, Shapiro J. Lack of efficacy of topical latanoprost in the treatment of eyebrow alopecia areata. *J Am Acad Dermatol.* 2005;53:1095-6.
44. McElwee KJ, Rushton DH, Trachy R, Oliver RF. Topical FK506: a potent immunotherapy for alopecia areata? Studies using the Dundee experimental bald rat model. *Br J Dermatol.* 1997;137:491-7.
45. Freyschmidt-Paul P, Ziegler A, McElwee KJ, Happle R, Kissling S, Sundberg JP, et al. Treatment of alopecia areata in C3H/HeJ mice with the topical immunosuppressant FK506 (Tacrolimus). *Eur J Dermatol.* 2001;11:405-9.
46. Price VH, Willey A, Chen BK. Topical tacrolimus in alopecia areata. *J Am Acad Dermatol.* 2005;52:138-9.
47. D'Ovidio R, Claudatus J, Di Prima T. Ineffectiveness of imiquimod therapy for alopecia totalis/universalis. *J Eur Acad Dermatol Venereol.* 2002;16:416-7.
48. Letada PR, Sparling JD, Norwood C. Imiquimod in the treatment of alopecia universalis. *Cutis.* 2007;79:138-40.
49. Clifton MM, Johnson SM, Roberson PK, Kincannon J, Horn TD. Immunotherapy for recalcitrant warts in children using intralesional mumps or Candida antigens. *Pediatr Dermatol.* 2003;20:268-71.
50. Rosemberg EW, Skinner Jr RB. Immunotherapy of alopecia areata with intralesional candida antigen. *Pediatr Dermatol.* 2006;23:299.
51. Zakaria W, Passeron T, Ostovari N, Lacour JP, Ortonne JP. 308-nm excimer laser therapy in alopecia areata. *J Am Acad Dermatol.* 2004;51:837-8.
52. Waiz M, Saleh AZ, Hayani R, Jubory SO. Use of the pulsed infrared diode laser (904 nm) in the treatment of alopecia areata. *J Cosmet Laser Ther.* 2006;8:27-30.
53. Hajheydari Z, Jamshidi M, Akbari J, Mohammadpour R. Combination of topical garlic gel and betamethasone valerate cream in the treatment of localized alopecia areata: a double-blind randomized controlled study. *Indian J Dermatol Venereol Leprol.* 2007;73:29-32.
54. Mandani S, Shapiro J. Alopecia areata update. *J Am Acad Dermatol.* 2000;42:549-66.
55. Assouly P, Reygagne P, Jouanique C, Matard B, Marechal E, Reynert P, et al. Intravenous pulse methylprednisolone therapy for severe alopecia areata: an open study of 66 patients. *Ann Dermatol Venereol.* 2003;130:326-30.

56. Burton JL, Shuster S. Large doses of glucocorticoid in the treatment of alopecia areata. *Acta Dermatol Venereol (Stockh)*. 1975;55:493-6.
57. Sharma VK. Pulsed administration of corticosteroid in the treatment of alopecia areata. *Int J Dermatol*. 1996;35:133-6.
58. Sharma VK, Gupta S. Twice weekly 5 mg dexamethasone oral pulse in the treatment of extensive alopecia areata. *J Dermatol*. 1999;26:562-5.
59. Agarwal A, Nath J, Barna KN. Twice weekly 5 mg betamethasone oral pulse therapy in the treatment of alopecia areata. *JEADV*. 2006;20:1375-6.
60. Cerottini JP, Panizzon RG, de Viragh PA. Multifocal alopecia areata during systemic cyclosporine A therapy. *Dermatology*. 1999;198:415-7.
61. Dyal-Smith A. Alopecia areata in renal transplant recipient on cyclosporin. *Australas J Dermatol*. 1996;37:226-7.
62. Rallis E, Nasiopoulou A, Kouskoukis C, Roussaki-Schulze A, Koumantaki E, Karpouzis A, et al. Oral administration of cyclosporin A in patients with severe alopecia areata. *Int J Tissue React*. 2005;27:107-10.
63. Shapiro J, Lui H, Tron V, Ho V. Systemic cyclosporine and low-dose prednisone in the treatment of chronic severe alopecia areata: a clinical and immunopathologic evaluation. *J Am Acad Dermatol*. 1997;36:114-7.
64. Joly P. The use of methotrexate alone or in combination low doses of oral corticosteroids in the treatment of alopecia totalis or universalis. *J Am Acad Dermatol*. 2006;55:632-6.
65. Smedegard G, Bjork K. Sulphasalazine: mechanism of action in rheumatoid arthritis. *Br Soc Rheumatol*. 1995;34:7-15.
66. Ellis CN, Brown MF, Voorhees JJ. Sulfasalazine for alopecia areata. *J Am Acad Dermatol*. 2002;46:541-4.
67. Misery L, Sannier K, Chastaing M, Le Gallic G. Treatment of alopecia areata with sulfasalazine. *J Eur Acad Dermatol*. 2007;21:547-8.
68. Camacho FM, García-Hernández MJ. Zinc aspartate, biotin, and clobetasol propionate in the treatment of alopecia areata in childhood. *Pediatr Dermatol*. 1999;16:336-8.
69. Ferrando J, Grimalt R, Lacueva L, Artuch R, Vilaseca MA. Biotinidase activity and biotin treatment in alopecia areata. Second Intercontinental Meeting of Hair Research Societies. Washington, 1998.
70. Ead RD. Oral zinc sulphate in alopecia areata—a double blind trial. *Br J Dermatol*. 1981;104:483-4.
71. Posten W, Swan J. Recurrence of alopecia areata in a patient receiving etanercept injections. *Arch Dermatol*. 2005;141:759-60.
72. Strober BE, Siu K, Alexis AF, Kim G, Washenik K, Sinha A, et al. Etanercept does not effectively treat moderate to severe alopecia areata: an open-label study. *J Am Acad Dermatol*. 2005;52:1082-4.
73. Etefagh L, Nedorost S, Mirmirani P. Alopecia areata in a patient using infliximab: new insights into the role of tumor necrosis factor on human hair follicles. *Arch Dermatol*. 2004;140:1012.
74. Kaelin U, Hassan AS, Braathen LR, Yawalkar N. Treatment of alopecia areata partim universalis with efalizumab. *J Am Acad Dermatol*. 2006;55:529-32.
75. Price VH, Hordinsky MK, Olsen EA, Roberts JL, Siegfried EC, Rafal ES, et al. Subcutaneous efalizumab is not effective in the treatment of alopecia areata. *J Am Acad Dermatol*. 2008;58:395-402.
76. Bui K, Polissety S, Gilchrist H, Jackson SM, Frederic J. Successful treatment of alopecia universalis with alefacept: a case report and review of the literature. *Cutis*. 2008;81:431-4.
77. Hefferman MP, Hurley MY, Martin KS, Smith DL, Anadkat MJ. Alefacept for alopecia areata. *Arch Dermatol*. 2005;141:1513-6.
78. Namazi MR. The potential efficacy of thalidomide in the treatment of recalcitrant alopecia areata. *Med Hypotheses*. 2003;60:513-4.
79. Hay IC, Jamieson M, Ormerod AD. Randomized trial of aromatherapy. Successful treatment for alopecia areata. *Arch Dermatol*. 1998;134:1349-52.
80. McElwee KJ, Niiyama S, Freyschmidt-Paul P, Wenzel E, Kissling S, Sundberg JP, et al. Dietary soy oil content and soy-derived phytoestrogen genistein increase resistance to alopecia areata onset in C3H/HeJ mice. *Exp Dermatol*. 2003;12:30-6.
81. Pierini G, Zara M, Cipriani R, Carrazo C, Preti A, Gava F, et al. Imipramine in alopecia areata. A double-blind, placebo-controlled study. *Psychother Psychosom*. 1994;61:195-8.