

CASES FOR DIAGNOSIS

Disseminated Crusted Papules in a Newborn

N. Guillermo, B. Hernández-Machín, and L. Borrego

Servicio de Dermatología, Hospital Universitario Insular de Gran Canaria, Las Palmas de Gran Canaria, Spain

Clinical History

The patient was a 1-month-old girl with a good general state, born after an uncomplicated pregnancy and delivery, and with no family or personal history of interest. The patient was referred to us for the presence of crusted lesions on the scalp since birth. These lesions had spread onto the trunk, axillas, and buttocks.

Physical Examination

The patient presented generalized, crusted, sometimes honey-colored, erythematous papules that were not infiltrated. The majority were situated on the scalp, axillas, upper part of the back, buttocks, and abdomen. There were also a number of residual lesions (Figure 1).

Complementary Tests

Complete blood count, blood and urine biochemistry, coagulation studies, protein electrophoresis, chest radiograph, abdominal ultrasound, and bone marrow aspiration were performed, all with normal results.

Histopathology

The pathologic study revealed parakeratosis in the epidermis and a band infiltrate that blurred the dermal-epidermal junction and that was formed of homogeneous, round, histiocytic cells, some with reniform nuclei, and with infrequent mitoses. There were occasional eosinophils (Figure 2). The histiocytic cells were positive for S100 protein and CD1a (Figure 3).

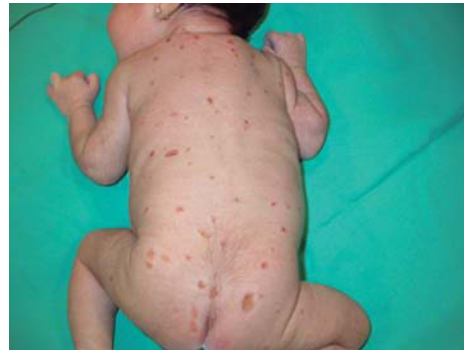

Figure 1.

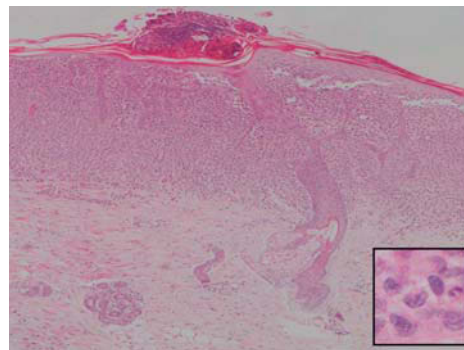


Figure 2.
Hematoxylin-eosin $\times 4$.
Inset: $\times 40$.

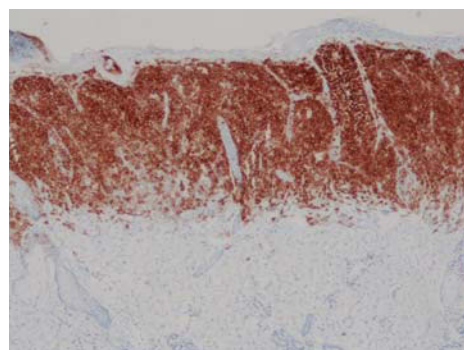


Figure 3.
CD1a, $\times 4$.

Correspondence:
N. Guillermo Martínez
Servicio de Dermatología
Hospital Universitario Insular de Gran Canaria
Avda. Marítima del Sur, s/n
35016 Las Palmas de Gran Canaria, Spain
nguimar@gobiernodecanarias.org

Manuscript accepted for publication January 18, 2008.

What Was the Diagnosis?

Diagnosis

Congenital self-healing Langerhans cell histiocytosis.

Clinical Course and Treatment

Cultures for bacteria, mycobacteria, and fungi were negative. No treatment was given. The lesions had resolved spontaneously by 2 months of age and the patient remained asymptomatic during 6 months of follow-up.

Discussion

Congenital self-healing Langerhans cell histiocytosis was first described in 1973 by Hashimoto and Pritzker,¹ who reported the case of a baby girl with 30 to 35, nodular, erythematous-brownish lesions at birth. The lesions were widespread but were most numerous on the face and scalp; they began to disappear at 5 weeks and had resolved completely by 3½ months, leaving small, atrophic scars. Histology revealed a histiocytic infiltrate of the dermis and Birbeck granules were visible in 10% of cells with electron microscopy. There was no recurrence of the lesions during 16 weeks of follow-up. Since that time, only a few more than 40 cases have been published.² The cutaneous lesions are described as papules, vesicles, or nodules of erythematous-violaceous or sometimes yellowish color, occasionally with an ulcerated or crusted center.³ Mucosal involvement is rare.³ The lesions are usually widespread, as occurred in our patient, although there may be a single lesion in 25% of cases.⁴ Despite being called congenital, lesions can present not only at birth but also after days, weeks, or months of life.³ Consensus has not been reached about the pathogenesis. Some authors attribute the disease to alterations of adhesion molecules such as E-cadherin, though this has been rejected by others more recently.

According to the Histiocyte Society, congenital self-limiting Langerhans cell histiocytosis is classified in the group of class I histiocytoses or Langerhans cell histiocytoses; according to the protocol, no treatment is recommended, as it is a localized, cutaneous form.⁵ As highlighted by Stein et al,⁶ the cutaneous lesions of the different histiocytoses do not enable us to predict whether there is systemic involvement, and a staging study is therefore essential. Langerhans cell histiocytosis should always be included in the differential diagnosis in any newborn infant with chronic lesions on the scalp and widespread over the rest of the body surface, and appropriate staging studies should be performed to exclude systemic disease.

Conflicts of Interest

The authors declare no conflicts of interest.

References

1. Hashimoto K, Pritzker MS. Electron microscope study of reticulohistiocytoma. An unusual case of congenital, self-healing reticulohistiocytosis. *Arch Dermatol.* 1973;107:263-70.
2. Kapur P, Erickson C, Rakheja D, Robin Carder K, Hoang MP. Congenital self-healing reticulohistiocytosis (Hashimoto-Pritzker disease): ten-year experience at Dallas Children's Medical Center. *J Am Acad Dermatol.* 2007;56:290-94.
3. Velázquez E, Medina DE, Vidal A. Histiocitosis de células de Langerhans congénita autolimitada (enfermedad de Hashimoto-Pritzker). *Piel.* 2006;21:142-45.
4. Mestre F, Saus C, Martín A, González A, Escalas J, Caimari M. Histiocitosis de células de Langerhans congénita autoinvoluntiva y solitaria (Hashimoto Pritzker). Presentación de un caso. *Actas Dermosifiliogr.* 1996;87:621-23.
5. Stéphan JL. Langerhans and non-Langerhans histiocytosis. *Arch Pediatr.* 2002;9:934-41.
6. Stein SL, Paller AS, Haut PR, Mancini AJ. Langerhans cell histiocytosis presenting in the neonatal period: a retrospective case series. *Arch Pediatr Adolesc Med.* 2001;155:778-83.