

CASES FOR DIAGNOSIS

Patient with a Pigmented Lesion Present for 2 Years

C. García-Millán,^a M. Martín-González,^a C. González-García,^b and P. Jaén^a

^aServicio de Dermatología and ^bServicio de Anatomía Patológica, Hospital Ramón y Cajal, Madrid, Spain

Clinical History

The patient was a 38-year-old man who was seen for an asymptomatic, pigmented lesion on the right arm. The lesion had been present for 2 years. He reported that the lesion had grown and become darker over the previous 6 months, but had not bled or ulcerated. There were no other similar lesions and no systemic symptoms.

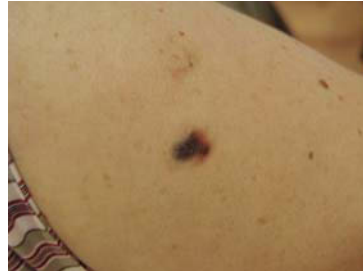

Figure 1.

Physical Examination

An irregular plaque with poorly defined borders was observed on the proximal third of the right arm. The whole surface was blue-black in color except for the distal part, which was red-brown (Figure 1), and the maximum diameter was 2 cm. No infiltration was noted on palpation, although the distal part of the lesion was depressed. There were no palpable axillary or cervical lymph nodes.

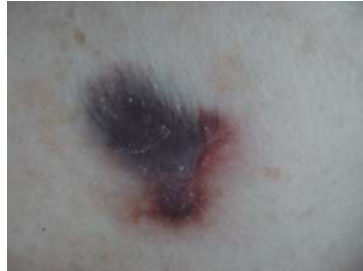

Figure 2.

Dermoscopy

An image was observed of homogeneous blue-black color, which became red-brown in the distal third; fine, whitish, linear structures were seen in this area. No reticular pigmentation or vascular structures were visible (Figure 2).

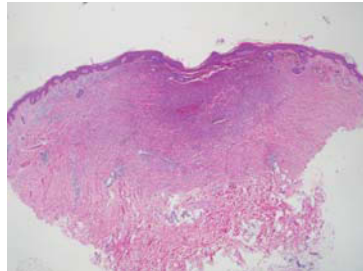


Figure 3. Hematoxylin-eosin, $\times 2.5$.

Histopathology

The lesion was completely excised. Histology revealed a tumor with poorly defined borders situated in the dermis and composed of fibrohistiocytic cells, numerous blood vessels, areas of collagen in the periphery, and abundant hemosiderin deposits, which were confirmed using Perls stain. There was hyperkeratosis of the epidermis and loss

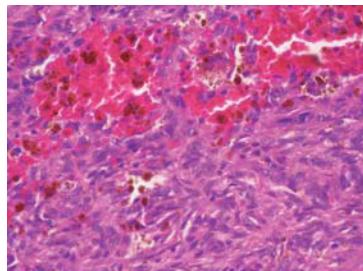


Figure 4. Hematoxylin-eosin, $\times 10$.

Correspondence:
Cristina García Millán
Hospital Ramón y Cajal
Ctra. de Colmenar, km 9,100
28034 Madrid, Spain
cgmillan@gmail.com

of the rete ridges, with no hyperpigmentation of the basal layer (Figures 3 and 4).

What Was the Diagnosis?

Manuscript accepted for publication February 27, 2008.

Diagnosis

Hemosiderotic dermatofibroma.

Discussion

Dermatofibroma or histiocytoma is one of the most common connective tissue tumors. It occurs mainly in young or middle-aged women, usually on the lower limbs. The average size is of 0.5 to 1 cm, except in the giant forms.¹

It has been suggested that dermatofibroma could represent a reactive process to an insect bite, but it is currently considered to be a benign tumor of histiocytic origin, with clonality being present in some cases.²

These are usually solitary, asymptomatic, papular or nodular lesions that grow slowly over a period of years. They can appear in an eruptive form, and are often associated with human immunodeficiency virus infection or connective tissue diseases.³

Excision is usually curative, although recurrences do occur.^{2,3} There have been reports of numerous variants, based on the histopathologic appearance¹: cellular, aneurysmal, epithelioid, pseudosarcomatous, clear cell, atrophic, lipidized, and palisading, among others.

The aneurysmal variant represents 2% of all cases.⁴ It usually presents as a dark blue or brown nodular lesion situated on the lower limbs. Occasionally it grows rapidly and can bleed. This neoplasm may be confused with tumors of melanocytic or vascular origin. A significant histological finding is the presence of clefts or cystic spaces mimicking dilated vascular spaces, though with no endothelial lining.

Two histologic types can sometimes coexist, corresponding to different stages of the same lesion. This is the case with hemosiderotic dermatofibroma, which can be a precursor form of the aneurysmal dermatofibroma.⁴ Extravasation of blood from the capillaries of the lesion gives rise to the formation of hemosiderin, which is phagocytosed by the dermal histiocytes and tumor cells. If extravasation continues, particularly in areas with little reticulin content, it can

produce the dilated spaces typical of aneurysmal dermatofibroma.

We have only found 2 studies that describe the dermoscopic features of the hemosiderotic variant.^{5,6} Zaballos et al⁶ published a series of 6 patients with the particular characteristic of the presence of homogeneous pigmentation with a variable spectrum of coloration from blue-grey to red-brown; this was also observed in our patient. In addition, they observed fine, whitish, linear structures that corresponded to fibrosis. Reticular pigmentation may be observed in the periphery. All these data are suggestive of the diagnosis of hemosiderotic or aneurysmal dermatofibroma, but are not sufficient to differentiate them from melanoma; the treatment indicated in these cases is therefore excision of the lesion and histologic examination.

Conflicts of Interest

The authors declare no conflicts of interest.

References

1. Micantonio T, Fagnoli MC, Peris K. Giant dermatofibroma appearing during pregnancy. *Acta Derm Venereol.* 2006;86: 86-7.
2. Hui P, Glusac EJ, Sinard JH, Perkins AS. Clonal analysis of cutaneous fibrous histiocytoma (dermatofibroma). *J Cutan Pathol.* 2002;29:385-9.
3. Lu I, Cohen PR, Grossman ME. Multiple dermatofibromas in a woman with HIV infection and systemic lupus erythematosus. *J Am Acad Dermatol.* 1995;32:901-3.
4. Calonje E, Fletcher CD. Aneurysmal benign fibrous histiocytoma: clinicopathological analysis of 40 cases of a tumour frequently misdiagnosed as a vascular neoplasm. *Histopathology.* 1995;26:323-31.
5. Blum A, Jaworski S, Metzler G, Bauer J. Lessons on dermoscopy: Dermoscopic pattern of hemosiderotic dermatofibroma. *Dermatol Surg.* 2004;30:1354-5.
6. Zaballos P, Llambrich A, Ara M, Olazaran Z, Malvey J, Puig S. Dermoscopic findings of haemosiderotic and aneurysmal dermatofibroma: report of six patients. *Br J Dermatol.* 2006; 154:244-50.