

ORIGINAL ARTICLES

Clinical Follow-up and Presence of Visceral Tumors in 12 Patients With Sebaceous Gland Tumors

P. Mercader,^a M.L. García-Melgares,^b E. Roche,^b J.L. Sánchez-Carazo,^b and V. Alegre-de Miquel^b

^aServicio de Dermatología, Hospital General Universitario Morales Meseguer, Murcia, Spain

^bServicio de Dermatología, Consorcio Hospital General Universitario de Valencia, Valencia, Spain

Background. Sebaceous gland tumors are a rare type of neoplasm. In some cases they have been associated with visceral tumors in patients with Muir-Torre syndrome, a hereditary form of nonpolyposis colorectal cancer. The aim of this study was to review the diagnosis and follow-up of a series of patients with sebaceous gland tumors to assess how many met the criteria for Muir-Torre syndrome.

Patients and methods. A search was performed of records from 1990 to 2005 in the database of the Department of Dermatology of the Consorcio Hospital General Universitario de Valencia in Valencia, Spain, to identify patients with sebaceous gland tumors. The biopsy material was reviewed to confirm the diagnosis. We also searched the patient histories for information suggestive of a diagnosis of Muir-Torre syndrome; when the histories were incomplete, we contacted the patients by telephone.

Results. We identified 20 patients diagnosed with sebaceous gland tumors, but after reviewing the biopsy material diagnosis was only confirmed in 12. Two patients belonged to a family with a history of visceral tumors that met the clinical criteria for hereditary nonpolyposis colorectal cancer syndrome. Follow-up was not uniform in all patients and not all underwent the same tests.

Conclusions. It is essential to rule out the presence of Muir-Torre syndrome in patients with sebaceous gland tumors. The use of new techniques such as immunohistochemistry or detection of microsatellite instability may help to identify families at increased risk of Muir-Torre syndrome.

Key words: Muir-Torre syndrome, Lynch syndrome, sebaceous gland tumors.

TUMORES SEBÁCEOS: SEGUIMIENTO CLÍNICO Y PRESENCIA DE NEOPLASIAS EN UNA SERIE DE 12 PACIENTES

Resumen. *Introducción.* Los tumores sebáceos son un grupo infrecuente de neoplasias. En algunos casos se han relacionado con neoplasias viscerales en pacientes con el síndrome de Muir-Torre; una variante clínica del síndrome de cáncer de colon hereditario no polipósico. El objetivo de este trabajo es revisar el diagnóstico y el seguimiento de una serie de pacientes con tumores sebáceos para comprobar cuántos de ellos cumplían criterios de síndrome de Muir-Torre.

Pacientes y métodos. Se realizó una búsqueda en la base de datos del Servicio de Dermatología del Consorcio Hospital General Universitario de Valencia entre 1990 y 2005, buscando pacientes con tumores sebáceos. Se revisaron las biopsias para confirmar el diagnóstico. También buscamos datos en las historias clínicas que sugiriesen un diagnóstico de síndrome de Muir-Torre, cuando las historias estaban incompletas nos pusimos en contacto por teléfono con los pacientes.

Resultados. Encontramos 20 pacientes diagnosticados de tumores sebáceos, pero después de revisar la biopsia sólo confirmamos este diagnóstico en 12 pacientes. Dos pacientes pertenecían a una familia con antecedentes de neoplasias viscerales, que cumplía los criterios clínicos de síndrome de cáncer de colon hereditario no polipósico. No hubo un seguimiento uniforme de los pacientes ni se realizaron las mismas pruebas en todos ellos.

Conclusiones. Es fundamental descartar la presencia de un síndrome de Muir-Torre en pacientes con tumores sebáceos. El uso de nuevas técnicas como la detección de la inestabilidad de microsatélites o la inmunohistoquímica pueden ayudar a detectar a las familias que tienen un mayor riesgo de padecer el síndrome de Muir-Torre.

Palabras clave: síndrome de Muir-Torre, síndrome de Lynch, neoplasias de la glándula sebácea.

The authors declare that they have received no funding.

Correspondence:
Pedro Mercader
Servicio de Dermatología
Hospital Morales Meseguer
Avda/ Marqués de los Vélez, s/n., 30008 Murcia, Spain
pedromercader@hotmail.com

Manuscript accepted for publication February 27, 2008

Introduction

Sebaceous tumors are a rare type of neoplasm with a complex nomenclature system.¹ They have acquired importance due to their association with visceral malignancies in Muir-Torre syndrome (MTS).^{2,3} MTS is an autosomal-dominant hereditary disease featuring at least 1 sebaceous tumor with a visceral malignancy, or multiple keratoacanthomas with visceral malignancies and a family history of MTS in the absence of other predisposing factors.^{4,5} According to reports in the literature, the percentage of patients with sebaceous tumors who develop visceral malignancies varies from 13.9%⁶ to 42%.⁷

Reports of MTS in families with hereditary nonpolyposis colorectal cancer (HNPCC), also known as Lynch syndrome,⁸ appeared for the first time in the 1980s. It was subsequently discovered that patients with MTS and HNPCC had the same genetic defect involving proteins responsible for DNA mismatch repair.^{9,10} It is now believed that MTS is a clinical form of HNPCC.¹¹ When HNPCC is suspected, a set of clinical diagnostic criteria known as the Amsterdam Criteria^{12,13} and the Bethesda Guidelines¹⁴ is applied to assess the history of cancer in the patient and his/her family.

Visceral malignancies in HNPCC typically affect the colon, but they can also be found in the endometrium, the ovary, the stomach, the small intestine, the ureter, the renal pelvis, and the brain.¹² Other features of MTS include the presence of multiple tumors, early-age onset of tumors, and, in some cases, improved prognosis when tumors appear spontaneously.¹¹

The aim of this study was to review the diagnosis and follow-up of a series of patients with sebaceous tumors to determine how many of them met the criteria for MTS.

Patients and Methods

We searched entries in the dermatologic disease database of the Department of Dermatology at Hospital General Universitario in Valencia, Spain, between 1990 and 2005 using the following search terms: sebaceous adenoma, sebaceous epithelioma, basal cell carcinoma with sebaceous differentiation, sebaceoma, and sebaceous carcinoma. We excluded from our search other types of sebaceous tumors unrelated to MTS such as sebaceous hyperplasia, nevus sebaceous of Jadassohn, and mixed neoplasms with sebaceous and apocrine differentiation. We reviewed the biopsy material to confirm the original diagnosis, searching for signs of sebaceous differentiation¹⁵ (Table 1) and selecting biopsies revealing unequivocal evidence of sebaceous tumors.

We also reviewed the patients' medical records in search of data indicating a personal or family history of cancer which met the Amsterdam criteria^{12,13} or the Bethesda

Table 1. Histopathologic Criteria for Sebaceous Differentiation

1. Cells with sebocytes that are morphologically similar to those of a normal sebaceous gland
2. Ducts that become keratinized in a similar manner to sebaceous ducts
3. Sebum
4. Horny layer typical of the sebaceous duct

Source: Requena et al¹⁵

Table 2. Diagnostic Criteria for Hereditary Nonpolyposis Colorectal Cancer (HNPCC)

Amsterdam Criteria I¹²

- At least 3 relatives must have colorectal cancer.
- One member of the family must be a first-degree relative of the other 2.
- At least 2 generations must be affected.
- At least 1 tumor must have been diagnosed before the age of 50.
- Familial adenomatous polyposis must be ruled out.

Amsterdam Criteria II¹³

- The same as the Amsterdam I criteria but including patients with other HNPCC-associated tumors (in the endometrium, ovary, small intestine, ureter, and renal pelvis).

Bethesda Criteria¹⁴

- Colorectal cancer in a patient under 50 years of age
- Presence of colorectal tumors or other synchronous or metachronous HNPCC-associated tumors^a at any age
- Colorectal cancer with a mucinous/signet ring cell-type histology, lymphocytes infiltrating the tumor, and a Crohn-like peritumoral lymphocyte reaction with a medullary growth pattern in patients under 60 years
- Patients with colorectal cancer and a first-degree relative with a HNPCC-associated tumor,^a with 1 of the tumors diagnosed before the age of 50
- Patients with colorectal cancer with 2 or more first- or second-degree relatives with a HNPCC-associated tumor diagnosed at any age.

^aIncludes tumors of the endometrium, ovary, small intestine, stomach, pancreas, biliary tract, sebaceous tumors, and brain tumors.

Guidelines¹⁴ (Table 2). Finally, we searched for information on additional studies that might have been performed and details of clinical outcome. When this information was not found, we contacted the corresponding patient by telephone.

Table 3. Patients Diagnosed With Sebaceous Tumors Not Confirmed During the Biopsy Review

| | Age, y | Sex | Year | Initial Diagnosis | Reviewed Diagnosis | Examinations |
|-----------|--------|--------|------|---|---------------------------------|--------------|
| Patient a | 67 | Male | 1990 | Sebaceous epithelioma | Eccrine spiradenoma | Opaque enema |
| Patient b | 64 | Male | 1991 | Sebaceous adenoma | Sebaceous hyperplasia | Colonoscopy |
| Patient c | 79 | Male | 1992 | Sebaceous carcinoma | Squamous cell carcinoma | Colonoscopy |
| Patient d | 59 | Male | 1992 | Sebaceous epithelioma | Squamous cell carcinoma | No |
| Patient e | 85 | Female | 1993 | Squamous cell carcinoma versus sebaceous carcinoma | Bowen Disease | No |
| Patient f | 86 | Female | 1995 | Sebaceous carcinoma | Apocrine hidradenocarcinoma | No |
| Patient g | 65 | Male | 1996 | Basal cell carcinoma with sebaceous differentiation | Clear-cell basal cell carcinoma | Opaque enema |
| Patient h | 95 | Female | 1997 | Sebaceous adenoma | Sebaceous hyperplasia | No |

Results

We identified 20 patients who had been diagnosed with a sebaceous tumor between 1990 and 2005. According to the histology results, however, only 12 of these patients had clear signs of such a tumor. The other 8 patients had results indicating tumors unrelated to MTS (see Table 3 for data on these patients). Partial biopsies only were performed in 2 patients (patients d and e) and the original diagnosis coincided with ours after the corresponding tumors had been removed. On reviewing the medical records of these 8 patients, we found that 4 of them (patients a, b, c, and g) had undergone additional tests to rule out the presence of neoplasms.

The data for patients with confirmed sebaceous tumors are shown in Table 4. There were 6 men and 6 women, with a mean age of 68 years. The majority of tumors were sebaceous adenomas, and only 1 patient (patient 6) had multiple tumors. Two patients (patients 7 and 10) were attended at an outpatient clinic but not referred to hospital. We therefore had no access to data on their outcome or on additional tests that might have been performed. There was no contact telephone number for another patient (patient 2), meaning that we were unable to inquire about his outcome or ascertain whether he or his family had a history of cancer (this information was not in his medical record). Although another 3 medical records (for patients 4, 5, and 11) were also incomplete in this sense, we were able to locate these patients by telephone and ascertain that they did not meet the diagnostic criteria for HNPCC.

Additional studies designed to rule out neoplasms were performed in 6 of the 12 patients with confirmed sebaceous tumors (patients 1, 3, 5, 6, 9, and 12). Two patients (patients 4 and 8) refused to undergo such studies.

The reason for not ordering complementary tests was not specified in 2 cases (patients 2 and 11) and there was

no information on possible tests performed in another 2 cases (patients 7 and 10).

Only 2 patients (patients 6 and 12) had a history of cancer in the family. These patients were relatives and had a family history fulfilling the Amsterdam criteria.^{12,13} Their case is described in more detail in the next section.

Patients 6 and 12

In September 1998, patient 6 presented with a small eroded papule, yellowish in color, on the right cheek, (Figure 1) which was initially diagnosed as basal cell carcinoma. Histopathologic analysis of the lesion revealed a neoplasm located in the superficial dermis, formed mostly by mature scattered sebocytes (Figure 2), and the final diagnosis was sebaceous adenoma. Several of the patient's first- and second-degree relatives had a history of cancer of the colon and the endometrium (Figure 3) and the family history met the Amsterdam criteria.^{12,13} The patient was enrolled in a colon cancer screening program involving 6-monthly colonoscopies and gynecologic examinations. During the first gynecologic examination in January 1999, an endometrial tumor was found and the patient underwent a hysterectomy with bilateral adnexectomy that same year. All of the patient's first-degree relatives, with the exception of 1 brother, were enrolled in a similar screening program. During the follow-up of the family, the patient's daughter (patient 12) (patient III-2 Figure 3) developed a lesion similar to the one on her mother's nose; the lesion was removed in 2004, when the patient was 28 years old. The biopsy revealed poorly defined nodules in the mid dermis, formed mostly of mature sebocytes, with an infundibulum in the serial slices (Figure 4). The diagnosis was also sebaceous adenoma. That same year, the family was referred for a genetic study, which revealed a deletion of exons 1 and 2 of the *MSH2* gene in patient 6 and

Table 4. Patients Diagnosed With Sebaceous Tumors Confirmed During the Biopsy Review

| | Age, y | Sex | Year ^a | Diagnosis | Cancer, PH | Cancer, FH | Tests | Clinical Course |
|-------------------------|--------|--------|-------------------|---------------------|-----------------|-----------------------------|--|---|
| Patient 1 | 61 | Male | 1994 | Sebaceous adenoma | No | No | Colonoscopy | No complications ^b |
| Patient 2 ^c | 70 | Male | 1997 | Sebaceous adenoma | NR | NR | No | NR |
| Patient 3 | 81 | Female | 1997 | Sebaceous carcinoma | No | No | Colonoscopy | Cutaneous squamous cell carcinoma (2003) |
| Patient 4 | 86 | Female | 1998 | Sebaceous carcinoma | No ^b | No ^b | No | No complications |
| Patient 5 | 66 | Male | 1998 | Sebaceoma | No ^b | No ^b | Opaque enema | No complications ^b |
| Patient 6 | 52 | Female | 1998 | Sebaceous adenoma | No | Yes (colon and endometrium) | Colonoscopy Gynecological examination | Endometrial carcinoma (1999), sebomatricoma (2002) Six-monthly colonoscopy |
| Patient 7 ^c | 76 | Male | 1998 | Sebaceous adenoma | NR | NR | NR | NR |
| Patient 8 | 61 | Male | 1998 | Sebaceous adenoma | No | No | No | No complications ^b |
| Patient 9 | 72 | Male | 1998 | Sebaceous carcinoma | No | No | Colonoscopy | Cutaneous squamous cell carcinoma (1999) Human immunodeficiency virus positivity (2001) Squamous cell carcinoma of the lip (2003) |
| Patient 10 ^c | 93 | Female | 1999 | Sebaceous adenoma | NR | NR | NR | NR |
| Patient 11 | 81 | Female | 2002 | Sebaceous adenoma | No ^b | No ^b | No | No complications |
| Patient 12 | 28 | Female | 2004 | Sebaceous adenoma | No | Yes (colon and endometrium) | Colonoscopy Gynecological examination | Daughter of patient 6 No complications |

Abbreviations: FH, family history; NR, no record; PH, personal history.

^aRefers to year of diagnosis.

^bData collected by telephone.

^cNo contact telephone number.

her 2 children; at the time of the tests, her son (patient III: 1, figure 3) had not developed any tumors (Figure 3). Two of the patient's siblings refused to do the tests. We do not have information on the rest of the family as follow-up was conducted by other centers.

Discussion

The first step towards diagnosing MTS is the histopathologic detection of an associated sebaceous tumor. This does not include sebaceous hyperplasia, sebaceous nevus, or other tumors originating in the pilosebaceous-apocrine unit which may exhibit focal sebaceous differentiation. Differential diagnosis should also include other entities featuring clear-cell lesions such as clear-cell basal cell carcinoma, clear-cell squamous cell carcinoma, Paget disease, pagetoid Bowen disease, clear-cell hydradenoma, clear-cell syringoid carcinoma, and skin metastases from renal carcinoma. Differential diagnosis can be complicated; in our series, for

example, a considerable proportion of patients originally diagnosed with sebaceous tumors (40%) actually had other types of clear-cell tumors or sebaceous hyperplasia.

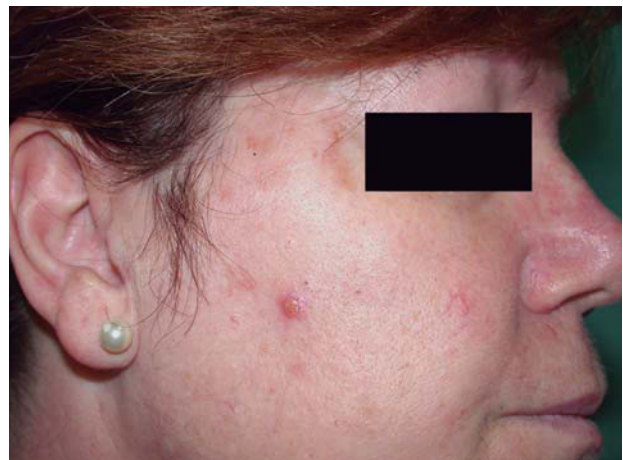

Figure 1. Yellowish papule on the right cheek.

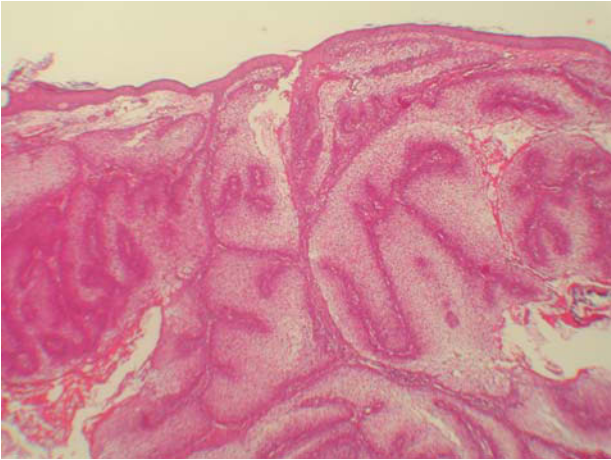

Figure 2. Well differentiated sebocytes in the superficial dermis grouping to form poorly defined lobes. No adnexal structures identified. (Hematoxylin–eosin, original magnification $\times 100$).

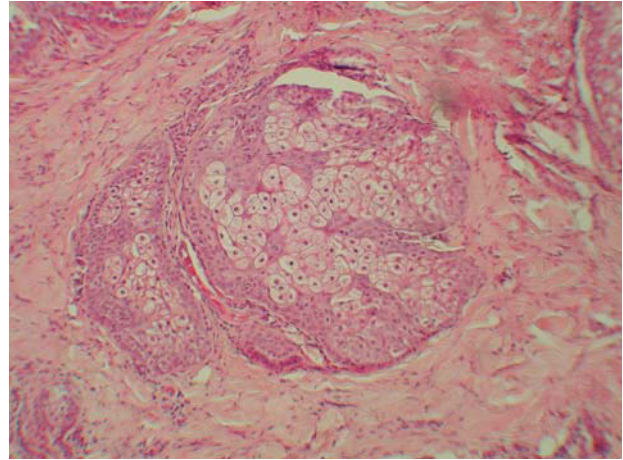


Figure 4. Well differentiated sebocytes forming irregular lobes and unconnected to hair follicles. (Hematoxylin–eosin, original magnification $\times 200$).

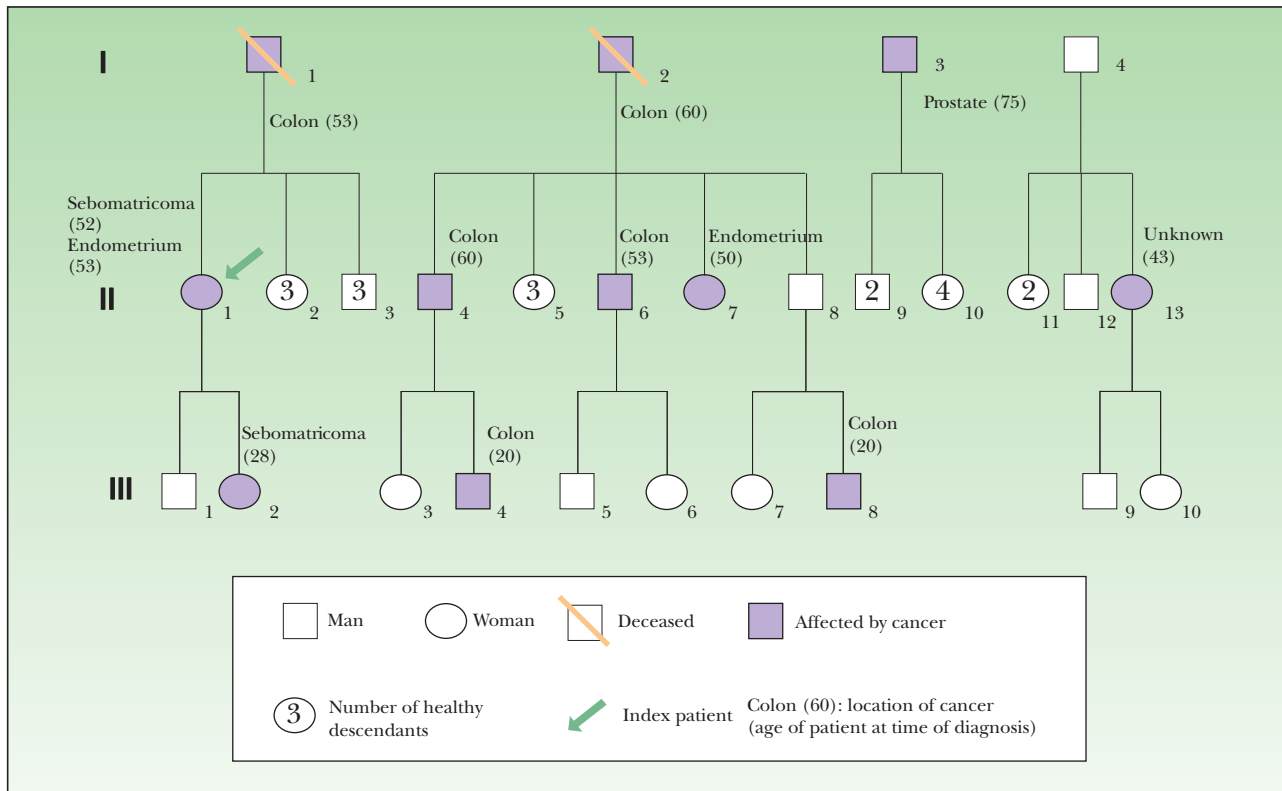


Figure 3. Genealogical tree of patients 6 (index case) and 12.

The existence of poorly defined terms such as basal cell carcinoma with sebaceous differentiation may explain why biopsy findings were misinterpreted in our series. It has been proposed that most cases of basal cell carcinoma with sebaceous differentiation described in the literature are actually clear-cell basal cell carcinoma (as was the case with patient g in our series) or sebaceous glands trapped as a

result of tumor growth.¹⁶ One way of avoiding such confusion would be to establish terms which group different sebaceous tumors into well-defined entities and embrace all benign tumors with sebaceous differentiation. One example is the term sebomatrixoma proposed by Sánchez Yus et al¹⁷ and supported by other authors such as Simon et al.¹⁸

Erroneous diagnoses can also occur when biopsy specimens are small or contain artefacts. This occurred in 2 of our patients (patients d and e), in whom a correct diagnosis was not made until the tumor was completely removed.

Before deciding whether or not to perform a histologic analysis to confirm the existence of a sebaceous tumor, one should consider that this might require the performance of additional tests to rule out internal malignancies (as occurred in 4 of our patients [patients a, b, c, and g]), leading to unnecessary costs and emotional stress for patients facing the possibility that they might have an occult tumor.

Once the histologic analysis is complete, the next step is to conduct an exhaustive examination of the patient's medical history in search of evidence of a personal or family history of cancer^{6,19} consistent with the Amsterdam criteria^{12,13} or the Bethesda guidelines.¹⁴ This information was only available for 50% of the patients with sebaceous tumors in our series, possibly because the records were not properly completed or because the physicians were unaware of the clinical implications of the histopathologic diagnosis. To address the problem of missing data, we contacted patients by telephone to inquire about the history of cancer in their family.

We found that only 2 (22.2%) of 9 patients (patients 6 and 12)—who were in fact from the same family—had a history that was indicative of HNPCC. Although our series was very small, this figure of 22.2% is similar to that reported in a recent study by Ponti et al,⁶ in which 5 (13.9%) of 36 patients with sebaceous neoplasms had criteria suggestive of MTS, but considerably lower than the figure of 42% (25 of 59 patients) reported by Finan and Connolly⁷ in the 1980s. This difference could be because some of the patients studied by Finan and Connolly had potentially confusing entities such as basal cell carcinoma with sebaceous differentiation (n=2) and “adenomatous” (sic) lesions with features of sebaceous hyperplasia, epithelioma, and keratin pearls (n=9). In all likelihood, not all of these patients had a sebaceous tumor associated with MTS, and if they did not, the findings of the study would be invalid. It should be borne in mind that our study had certain limitations. Because our sample was small and selected from a single hospital, we were unable to evaluate the prevalence of visceral tumors in patients with sebaceous tumors with sufficient accuracy. Furthermore, because the study was retrospective and follow-up was not the same for all patients, tumor prevalence may have been underestimated.

The family history of the 2 relatives in our study (Figure 3) met the Amsterdam II criteria and is a clear example of autosomal-dominant disease with variable expression and incomplete penetrance. Variable expression refers to fact that the same genetic defect can express itself in different ways in different individuals. In our case, for example, the 2 members of the family in our series had sebaceous tumors

whereas the other members had developed other types of tumors. Incomplete penetrance refers to the fact that not all individuals who inherit a defective gene will develop the corresponding disease. The best example of incomplete penetrance in this family is member II-8, who did not develop colon cancer, even though one of his children (III-8) and his father did (I-3). Such individuals are heterozygotes for the mutation, meaning that they conserve a healthy copy of the affected gene and do not develop disease because environmental factors prevent the defective gene from being expressed.

Family history cannot always be evaluated; this occurs in the case of adoption, false paternity, unfamiliarity with the causes of death within a family, incomplete penetrance in small families, and de novo mutations.²⁰ Consequently, the absence of a family history does not completely rule out the presence of a DNA mismatch repair protein mutation.

To exclude such a mutation, more recent protocols recommend analyzing microsatellite instability in tumors of patients or their relatives.^{6,19} Microsatellites are repetitive sequences of dinucleotides, trinucleotides, or tetranucleotides distributed in the genome which become considerably altered in the case of DNA mismatch gene damage.

It may, however, be more practical to use immunohistochemical analysis to detect such damage as this method has been shown to correlate well with microsatellite instability analysis.²¹ Coinciding with our findings, the 2 most commonly altered proteins are MLH1 and, above all, MSH2,²² although there have also been reports of MSH6 mutations.²³ In immunohistochemical analysis, special reagents are used to detect these 3 proteins. If the proteins are deficient, the corresponding areas will not be stained. If alterations are detected during screening, a search is then performed to locate the sequence mutation in the gene; if this is found, the patient's relatives will be examined and any carriers detected advised to enroll in a cancer screening program. If a mutation is not found in a family member, this does not mean that future disease can be completely ruled out as he/she might have a defective gene that has not yet been detected.¹¹ If a patient's medical record contains information which suggests the possible existence of a mutation, both the patient and his/her first-degree relatives should be enrolled in a cancer screening program.

Because such tests were not available when our patients were diagnosed, colonoscopies and barium enema screening were used to exclude the presence of associated tumors in half of the patients in our series, and most of these tests were conducted sporadically. If we consider that internal neoplasms appear after a sebaceous tumor has been detected in as many as 22% of patients with MTS,²⁸ several of the patients in our series might have developed a tumor several years after the colonoscopy or barium enema test as follow-

up was irregular and incomplete in certain patients. This possibility, however, is unlikely in view of the high mean age of our patients (68 years). In our series, only 2 patients (patients 6 and 12) underwent regular screening for cancer; both of these had a history consistent with HNPCC and were relatively young. The rest of their family, with the exception of their first-degree relatives, was monitored in other centers.

Patients enrolled in HNPCC screening programs undergo a colonoscopy every 1 or 2 years starting at the age of 20 to 25 years. Women over the age of 30 must additionally undergo a gynecologic examination with transvaginal ultrasound, suction endometrial biopsy, and serum cancer antigen-125 testing. Other studies may be performed depending on the family history of cancer.^{24,25}

In the case of MTS, several authors have proposed performing mammograms every 1 or 2 years from the time the syndrome is diagnosed to when the patient reaches 50, and yearly thereafter.^{19,26} Nonetheless, it should be borne in mind that breast cancer and indeed other cancers described in patients with MTS have not been definitively associated with HNPCC,²⁵ meaning that their existence may, on occasions, be purely coincidental. Another group of authors proposed performing a computed tomography scan of the abdomen and pelvis every 2 to 5 years¹⁹ because 35% of abdominal tumors in MTS occur at sites other than the colon.²⁷

Dermatologists play a key diagnostic role in MTS. Our findings suggest that some dermatologists underestimate the potential severity of sebaceous tumors, disregard the importance of family history of cancer, and fail to order additional studies to exclude visceral malignancies.

New techniques such as microsatellite stability analysis, immunohistochemical analysis, and gene sequencing all help to identify patients with sebaceous tumors at risk of developing cancer but they are no substitute for a reliable medical record.

Conflicts of Interest

The authors declare no conflicts of interest.

References

1. Requena C, Requena L. Clasificación de las proliferaciones con diferenciación sebácea. En: Requena L, editor. Neoplasias anxiales cutáneas. Madrid: Grupo Aula Médica; 2004. p 365-9.
2. Muir EG, Bell AJY, Barlow KA. Multiple primary carcinoma of the colon, duodenum and larynx associated with keratoacanthomata of the face. *Br J Surg*. 1967;54:191-5.
3. Torre D. Multiple sebaceous tumours. *Arch Dermatol*. 1968; 98:549-51.
4. Schwartz RA, Torre DP. The Muir-Torre syndrome: a 25 years retrospect. *J Am Acad Dermatol*. 1995;33:90-104.
5. National Center for Biotechnology Information. OMIM: online Mendelian inheritance in man. Disponible en: www.ncbi.nlm.nih.gov/entrez/dispomim.cgi?id=158320
6. Ponti G, Losi L, Di Gregorio C, Roncucci L, Pedroni M, Scarselli A, et al. Identification of Muir-Torre syndrome among patients with sebaceous tumors and keratoacanthomas. Role of clinical features, microsatellite instability and immunohistochemistry. *Cancer*. 2005;103:1018-25.
7. Finan MC, Connolly SM. Sebaceous gland tumors and systemic disease: a clinicopathologic analysis. *Medicine*. 1984;63: 232-42.
8. Lynch HT, Lynch PM, Pester J, Fusaro RM. The cancer family syndrome: rare cutaneous phenotypic linkage of Torre's syndrome. *Arch Intern Med*. 1981;141:607-11.
9. Kruse R, Lamberti C, Wang Y, Ruelfs C, Bruns A, Esche C, et al. Is the mismatch repair deficiency type of Muir-Torre syndrome confined to mutations in the hMSH2 gene? *Hum Genet*. 1996;99:736-9.
10. Bapat B, Xia L, Madlensky L, Mitri A, Tonin P, Narod SA, et al. The genetics basis of Muir-Torre syndrome includes the hMLH1 locus. *Am J Hum Genet*. 1996;98:747-50.
11. Lynch HT, Fusaro RM. The Muir-Torre syndrome in kindreds with hereditary nonpolyposis colorectal cancer (Lynch syndrome): a classic obligation in preventive medicine. *J Am Acad Dermatol*. 1999;41:797-9.
12. Vasen HF, Mecklin JP, Khan PM, Lynch HT. The International Collaborative Group on Hereditary Non-Polyposis Colorectal Cancer (ICG-HNPCC). *Dis Colon Rectum*. 1991;34:424-5.
13. Vasen HF, Watson P, Mecklin JP, Lynch HT. New clinical criteria for hereditary nonpolyposis colorectal cancer (HNPCC, Lynch syndrome) proposed by the International Collaborative Group on HNPCC. *Gastroenterology*. 1999; 116:1453-6.
14. Umar A, Boland CR, Terdiman JP, Syngal D, de la Chapelle A, Rüschoff J, et al. Revised Bethesda guidelines for hereditary nonpolyposis colorectal cancer (Lynch Syndrome) and microsatellite instability. *J Natl Cancer Inst*. 2004;96:261-8.
15. Requena C, Requena L. Criterios histopatológicos de diferenciación sebácea. In: Requena L, editor. Neoplasias anxiales cutáneas. Madrid: Grupo Aula Médica; 2004. p. 359-63.
16. Requena L, Requena C. Carcinoma basocelular de diferenciación sebácea. En: Requena L, editor. Neoplasias anxiales cutáneas. Madrid: Grupo Aula Médica; 2004. p. 459-65.
17. Sánchez Yus E, Requena L, Simón P, del Río E. Sebomatricoma: a unifying term that encompasses all benign neoplasms with sebaceous differentiation. *Am J Dermatopathol*. 1995; 17:213-21.
18. Simón RS, Eusebio E, Álvarez Viéitez A, Sánchez Yus E. Proliferaciones con diferenciación sebácea. II: Hiperplasias y neoplasias. *Actas Dermosifiliogr*. 1998;89:651-64.
19. Ponti G, Ponz de León M. Muir-Torre syndrome. *Lancet Oncol*. 2005; 6:980-7.
20. Jass JR. Hereditary non-polyposis colorectal cancer: the rise and fall of a confusing term. *World J Gastroenterol*. 2006; 21:4943-50.
21. Mathiak M, Rutten A, Mangold E, Fischer HP, Ruzicka T, Friedl W, et al. Loss of DNA mismatch repair proteins in skin tumors from patients with Muir-Torre syndrome and MSH2 or MLH1 germline mutations: establishment of

- immunohistochemical analysis as a screening test. *Am J Surg Pathol.* 2002;26:338-43.
22. Mangold E, Pagenstecher C, Leister M, Mathiak M, Rutten A, Friedl W, et al. A genotype-phenotype correlation in HNPCC: strong predominance of MSH2 mutations in 41 patients with Muir-Torre syndrome. *J Med Genet.* 2004; 41: 567-72.
 23. Mangold E, Rahner N, Friedrichs N, Buettner R, Pagenstecher C, Aretz S, et al. MSH6 mutation in Muir-Torre syndrome: could this be a rare finding? *Br J Dermatol.* 2007; 156: 158-62.
 24. Akthar S, Oza KK, Khan SA, Wrigth J. Muir-Torre syndrome: case report of a patient with concurrent jejunal and ureteral cancer and a review of the literature. *J Am Acad Dermatol.* 1999;41:681-6.
 25. Thorson AG, Knezetic JA, Lynch HT. A century of progress in hereditary nonpolyposis colorectal cancer (Lynch syndrome). *Dis Colon Rectum.* 1999;42:1-9.
 26. Cohen PR, Kohn SR, Kurzrock R. Association of sebaceous gland tumors and internal malignancy: the Muir-Torre syndrome. *Am J Med.* 1991;90:606-13.
 27. Serleth HJ, Kiskan WA. A Muir-Torre syndrome family. *Am Surg.* 1998;64:365-9.