

PRACTICAL DERMATOLOGY

Usefulness of Bilateral Sympathectomy Using Video-Assisted Thoroscopic Surgery in the Treatment of Essential Hyperhidrosis

C.E. García Franco^a and A. España^b

^aDepartamento de Cirugía Torácica and ^bDepartamento de Dermatología, Clínica Universitaria de Navarra (CUN), Pamplona, Spain

Abstract. Essential, idiopathic, or primary hyperhidrosis is defined as excessive sweating in certain areas of the body due to factors unrelated to other disease. Clinical presentation can be categorized as palmar, plantar, axillary, or craniofacial. Medical treatment (aluminium salts, iontophoresis, anticholinergic drugs, and alfa-2-agonists) is of questionable effectiveness. Intradermal injections of botulinum toxin are very effective for the treatment of axillary hyperhidrosis. Surgical treatment involves resection (sympathectomy) or electrocautery (sympathicolysis) of the thoracic sympathetic chain, or compression of the sympathetic chain with clips, in all cases via video-assisted thoroscopic surgery. One or more ganglia between T2 and T5 are usually resected depending on the area affected by hyperhidrosis: T2 for craniofacial hyperhidrosis, T3 and T4 for palmar hyperhidrosis, and T3 to T5 for combined palmar and axillary hyperhidrosis. The technique is very useful and is effective in those patients with primary hyperhidrosis who have not responded to conservative treatment.

Key words: palmar, plantar, axillary, craniofacial, hyperhidrosis, thoracic sympathetic chain, botulinum toxin, endoscopic thoracic sympathectomy.

UTILIDAD DE LA SIMPATECTOMÍA VIDEOTORACOSCÓPICA BILATERAL EN EL TRATAMIENTO DE LA HIPERHIDROSIS ESENCIAL

Resumen. Se define como hiperhidrosis esencial, idiopática o primaria la excesiva sudoración de determinadas áreas del cuerpo debido a una causa no asociada a otras patologías. Distinguimos 4 formas de presentación clínica: palmar, plantar, axilar y/o cráneo-facial. El tratamiento médico (sales de aluminio, iontoforesis, anticolinérgicos y alfa-2-agonistas) tiene una eficacia cuestionada. El tratamiento con inyecciones intradérmicas de toxina botulínica tiene una gran eficacia en el tratamiento de la hiperhidrosis axilar. El tratamiento quirúrgico consiste en la resección de la cadena simpática ganglionar torácica (simpatectomía), en la electrocoagulación de ésta (simpaticolisis) o en la compresión de la cadena con clips; todas ellas mediante cirugía videotoracoscópica. Se suelen seccionar una o varias estaciones situadas entre T2 y T5 en función del área afecta de hiperhidrosis: T2 para la hiperhidrosis cráneo-facial, T3-4 para la palmar, T3-T5 para la palmar y la axilar asociadas. La técnica resulta de gran utilidad y eficacia en aquellos pacientes con hiperhidrosis primaria que no hayan respondido al tratamiento conservador.

Palabras clave: hiperhidrosis palmar, axilar, plantar y/o cráneo-facial, cadena simpática ganglionar torácica, toxina botulínica, simpatectomía torácica endoscópica.

Introduction

Hyperhidrosis is defined as excessive sweating in certain areas of the body. The disorder can be divided into primary

and secondary hyperhidrosis. Primary hyperhidrosis, also known as idiopathic or essential hyperhidrosis, is characterized by increased symmetric and bilateral sweating in specific body areas such as the axillae (axillary hyperhidrosis), the palms of the hands (palmar hyperhidrosis), the soles of the feet (plantar hyperhidrosis), or the craniofacial region (craniofacial hyperhidrosis).¹ The disorder normally presents in young healthy subjects, and leads to physical and psychosocial problems that have a very negative impact on their quality of life. It is necessary to distinguish between the primary form and secondary

Correspondence:
Carlos E. García Franco
Departamento de Cirugía Torácica
Clínica Universitaria de Navarra
Avenida de Pío XII, 36
31008 Pamplona, Spain
cegarcial@unav.es

Table 1. Characteristics Required to Establish Diagnosis of Primary Hyperhidrosis^a

Bilateral and symmetric event
Impaired activities of daily living
Occurs at least once a week
Onset before 25 years
Family history
Absence of sweating during sleep

^aAt least 2 items in the list are necessary for the diagnosis.

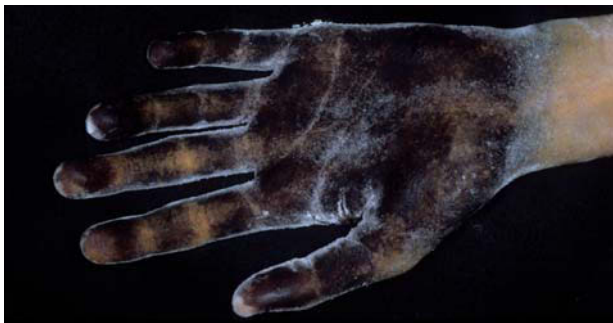

Figure 1. Minor starch-iodine test of the palm before treatment.

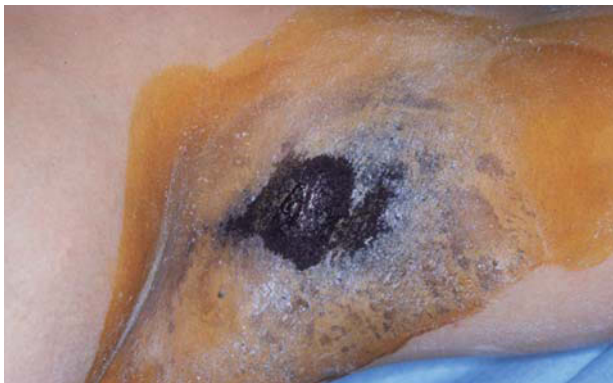

Figure 2. Minor starch-iodine test of the axilla before treatment.

hyperhidrosis, which is usually associated with other diseases such as infection, malignancy, neurologic and endocrine disorders, and medication-induced disorders.

Its incidence ranges between 1%-3% of the population, depending on the geographical area under study.^{2,3} This disorder is apparently inherited as an autosomal dominant genetic trait, with variable penetrance, but other etiologies cannot be excluded. Onset normally occurs during childhood or adolescence, but it sometimes appears in adults.

It is a benign disorder of unknown etiology and seems to be caused by overactivity of the sympathetic nervous

system in response to increased body temperature and specific emotional stimuli.³

Diagnosis

In order to establish the diagnosis of primary hyperhidrosis at least 2 of the characteristics listed in Table 1 should be present for a minimum of 6 months.

Normally, tests are not performed in daily clinical practice to quantify sweat production. Nevertheless, the following techniques can be used with this aim: a) the Minor starch-iodine test^{1,3}; b) dynamic sudometry^{2,4}; and c) the thermoregulatory sweat test.³

Treatment

Medical

1. Aluminum salts^{1,3}
2. Iontophoresis^{2,3}
3. Anticholinergic drugs: oxybutynin (5-15 mg/d) and tolterodine (4 mg/d)³
4. α -2-agonists: clonidine (0.6-1.2 mg/d)⁵

Botulinum Toxin

This is effective in treating axillary hyperhidrosis, with response rates of more than 90% seen after 4 weeks of treatment.¹ Outcomes are somewhat worse in the case of palmar hyperhidrosis, and the toxin is of little use in plantar or craniofacial hyperhidrosis.

It is injected intradermally in the affected areas. For treatment of the axillary region, 50 U diluted in 0.9% saline are injected into each axilla. Multiple injections are distributed evenly (1-2 cm apart) in the affected areas.

A Minor starch-iodine test is first performed to delineate the area where there is increased sweating (Figure 1 and Figure 2). Once treatment is finished the test is performed again to assess the therapeutic effect (Figure 3 and Figure 4). In the palmar area, 100 U are injected into each hand.

Sweat reduction is noticeable between 2 and 4 days, and should be obvious 2 weeks after injection. Subsequent injections are required every 4-17 months.³

Surgery

The thoracic autonomic nervous system consists of 10-12 paravertebral ganglia, within the endothoracic fascia, below the pleura. The sympathetic ganglia are linked by interganglionic branches, forming a white cord called the sympathetic chain. Surgery aims to treat primary

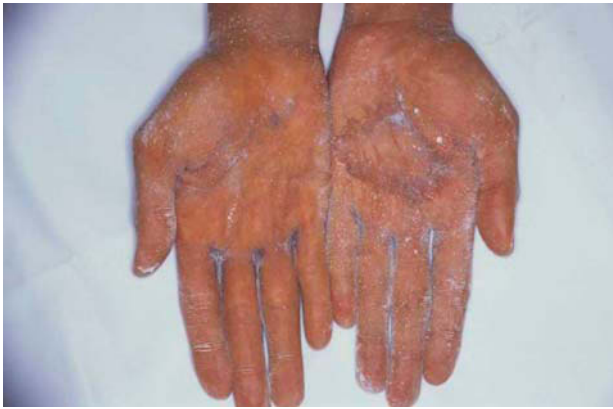

Figure 3. Minor starch-iodine test of the palms after treatment.

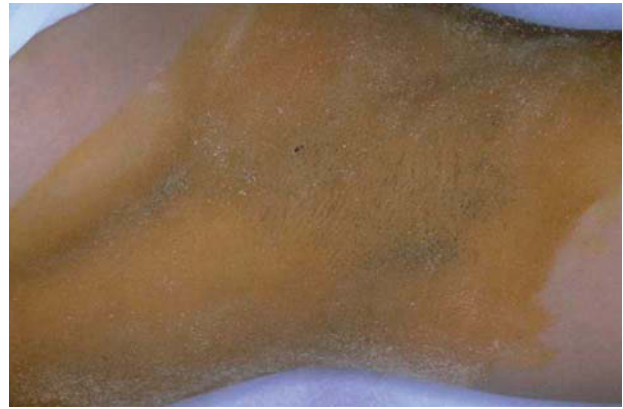

Figure 4. Minor starch-iodine test of the axilla after treatment.

hyperhidrosis by interrupting conduction in the sympathetic chain by resection (sympathectomy), electrocautery (sympathicolysis), or compression with metal clips.

The first interventions were reported in the literature during the 1920s, and were carried out by thoracotomy.⁶ Obviously, this approach was associated at that time with high morbidity and so did not become widely used.

The first sympathectomies were performed in the 1940s by conventional thoracoscopy, but the technique did not gain acceptance.⁷ At the end of the 1980s, the introduction of video-assisted thoracoscopic surgery and the development of minimally invasive surgery contributed to the technique called endoscopic thoracic sympathectomy becoming widespread.

The surgical technique consists of interrupting the sympathetic thoracic chain after having penetrated the chest cavity with 1 or 2 small incisions. A video camera (preferably 5 mm or 3 mm) and the surgical instrument are introduced through these holes to perform the intervention (Figure 5). This technique is bilateral, and involves collapsing the lung on the side of the operation in order to access the sympathetic chain on that side. This chain runs parallel to the spinal column, over the costotransverse joints, and approaches the midline as it descends. The sympathetic chain is interrupted with an electric scalpel, ultrasonic scalpel, or clips. Once this is done, the temperature of the patient's hand increases and is measured using a sensor located on the thenar eminence. This is done to verify that the chain has been correctly resected.

No consensus has been reached regarding the exact area where the sympathetic chain should be interrupted. In palmar hyperhidrosis, the chain is usually interrupted at T2-T4.⁸ The resection of several ganglia has been associated with an increase in compensatory sweating, and so most authors suggest interrupting the chain at T2-T3.⁹⁻¹¹ Others prefer to resect at T3-T4^{2,12,13} for the same reason. Sympathicolysis is sometimes even performed at T2 alone to relieve palmar hyperhidrosis.¹⁴

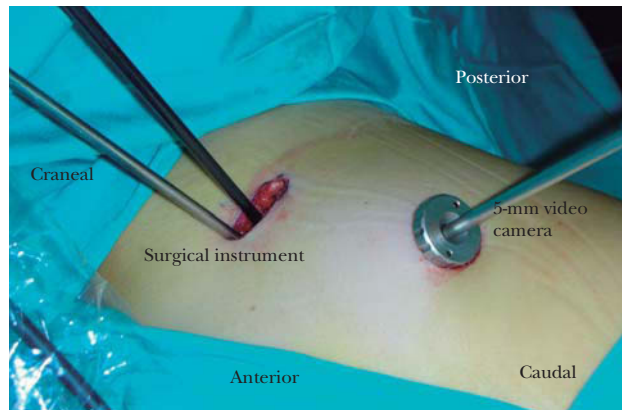


Figure 5. Left surgical field of video-assisted thoracoscopic surgery.

The area affected by excess sweating also has to be taken into account when interrupting the chain. In the case of palmar and axillary hyperhidrosis, it is usual to perform more extensive dissection (T2-T4 or T3-T5) than in cases of palmar hyperhidrosis only (T2-T3 or T3-T4).^{2,9,11} Some authors advocate cutting the chain at T2 in the case of facial hyperhidrosis, at T3 in palmar hyperhidrosis, and at T4 in axillary hyperhidrosis.^{13,14} Some authors suggest that resection at T2 seems to involve a greater probability of compensatory sweating.¹⁵ Other groups have reported the same problem regarding resection at T2-T3 compared to resection at T3-T4.¹³ In short, there is no consensus regarding the most appropriate site to interrupt the sympathetic chain. We choose one or more ganglia between T2 and T5 for resection depending on the area affected by hyperhidrosis: T2 for craniofacial hyperhidrosis, T3-T4 for palmar, and T3-T5 for combined palmar and axillary hyperhidrosis.

At the end of the intervention, air in the pleural cavity should be evacuated using a small-caliber drainage catheter,

Table 2. Summary of Therapeutic Intervention

<i>Palmar</i>	<i>Axillary</i>	<i>Plantar</i>	<i>Facial</i>
Initial treatment	Initial treatment	Initial treatment	Initial treatment
1. Aluminum salts	1. Aluminum salts	1. Aluminum salts	1. Aluminum salts
2. Iontophoresis	2. Anticholinergic drugs	2. Iontophoresis	2. alfa-2-agonistas
3. Anticholinergic drugs		3. Anticholinergic drugs	
If 1, 2, or 3 fail	If 1 or 2 fail		
Botulinum toxin	Botulinum toxin		
Efficacy 65-70%	Efficacy 94%		
If toxin fails:	If toxin fails and palmar hyperhidrosis is present:	If 1, 2 or 3 fail and palmar hyperhidrosis is present:	If 1 or 2 fail and palmar hyperhidrosis is present:
1. Sympathectomy	1. Sympathectomy	1. Sympathectomy	1. Sympathectomy
Efficacy >95%			

which can be removed in the recovery room once satisfactory lung expansion has been verified by chest X-ray.

Intraoperative and perioperative complications are few and unimportant. In a multicenter study, the endoscopic thoracic sympathectomy Cooperative Group, which is affiliated with the Spanish Society of Pulmonology and Thoracic Surgery,² has reported the following complications: pneumothorax in 3.6% of patients, only half of whom required drainage; prolonged pain (more than 15 days) in 1.4%; and transitory Horner syndrome in 1.3%.

The efficacy of the technique in treating palmar hyperhidrosis is around 95%. Failure or recurrence after surgery have been observed in less than 5% of patients treated for palmar hyperhidrosis,^{16,17} and this is usually due to incorrectly locating the sympathetic ganglia, to insufficient excision of ganglia, or to erroneous surgical indication. Efficacy is around 75% for axillary hyperhidrosis alone and craniofacial hyperhidrosis alone. For plantar hyperhidrosis alone, this technique has an efficacy of around 30%.

It should be emphasized that endoscopic thoracic sympathectomy is basically indicated in cases of severe hyperhidrosis of the palmar area or this area in combination with other areas and where conservative treatment has failed. The failure of this technique seems to be associated with cases of axillary, plantar, or craniofacial hyperhidrosis without palmar involvement.

The main adverse effect of this technique is so-called compensatory sweating. This involves sweating in areas that previously did not sweat or increased sweating in areas where sweating was previously normal. It tends to affect the torso and the proximal part of the legs and occurs in more than half the operated patients, but is only incapacitating or very severe in 4%-7% of patients. In these cases, treatment is complex and represents the greatest cause of dissatisfaction among operated patients. The

pathophysiology of this effect is unknown. It is associated with the extent of sympathectomy and at what level the ganglia are treated. It normally presents during first 6 months after surgery and can spontaneously disappear or persist. Treatment includes the local application of topical antiperspirants, botulinum toxin, oral anticholinergic drugs, anxiolytic drugs, and psychological support. Some authors report using titanium clips to block the nodal sympathetic chain. Thus, should very severe compensatory hyperhidrosis occur, the patient could have the clips removed, leaving the sympathetic chain functional again. This would eliminate the effects of the technique in the palms or axillae, but would also eliminate compensatory sweating. It should be noted that reintervention does not always lead to favorable outcomes and that the success rate is 60% among operated patients.¹⁷

An alternative surgical technique is currently being specifically developed and implemented for the treatment of plantar hyperhidrosis, which is difficult to control using conventional thoracic sympathectomy.¹⁸ This procedure is called laparoscopic lumbar sympathectomy.¹⁹ It consists of bilateral resection of sympathetic chain ganglia at a lower lumbar level using a retroperitoneal approach. Although we lack sufficient statistical data to confirm its efficacy, the results appear encouraging. Cases of severe axillary hyperhidrosis resistant to conservative treatment can be treated by suction-curettage of the subcutaneous tissue in the axillary area.²⁰ The outcomes are quite good, with a high level of patient satisfaction after the procedure.

Table 2 shows a summary of the therapeutic procedures described in this work.

Conflicts of Interest

The authors declare no conflicts of interest.

References

1. Hornberg J, Grimes K, Naumann M, Glaser DA, Lowe NJ, Naver H, et al. Recognition, diagnosis and treatment of primary focal hyperhidrosis. *J Am Acad Dermatol.* 2004; 51:274-86.
2. Grimalt R, Callejas MA. Hiperhidrosis: diagnóstico y tratamientos actuales. Madrid: Médica Panamericana; 2004.
3. Eisenach JH, Atkinson JL, Fealey RD. Hyperhidrosis: evolving therapies for a well-established phenomenon. *Mayo Clinic Proc.* 2005;80:657-66.
4. Braune C, Erbguth F, Birklein F. Dose thresholds and duration of local anhidrotic effect of botulinum toxin injections: measured by sudometry. *Br J Dermatol.* 2001;144:111-7.
5. Torch EM. Remission of facial and scalp hyperhidrosis with clonidine hydrochloride and topical aluminium chloride. *South Med J.* 2000;93:264.
6. White JC, Smithwick RH, Allen AW. A new muscle splitting incision for resection of the upper thoracic sympathetic ganglia. *Surg Gynecol Obstet.* 1933;56:651-7.
7. Kux E. Thorakoskopische eingriffe am Nervensystem. Stuttgart: Georg Thieme Verlag; 1954.
8. Dumont P, Denoyer A, Robin P. Long term results of thoracoscopic sympathectomy for hyperhidrosis. *Ann Thorac Surg.* 2004;78:1801-7.
9. Moya J, Ramos R, Morera R, Villalonga R, Perna V, Macia I, et al. Thoracic sympathectomy for primary hyperhidrosis: a review of 918 procedures. *Surg Endosc.* 2006;20: 598-602.
10. Loscertales J, Arroyo Tristán A, Congregado Loscertales M, Jiménez Merchán R, Girón Arjona JC, Arenas Linares C, et al. Tratamiento de la hiperhidrosis palmar por simpatectomía torácica. Resultados inmediatos y calidad de vida postoperatoria. *Arch Bronconeumol.* 2004;40:67-71.
11. Drott C, Göthberg G, Claes G. Endoscopic transthoracic sympathectomy: an efficient and safe method for treatment of hyperhidrosis. *J Am Acad Dermatol.* 1995;33:78-81.
12. Gossot D, Galetta D, Pascal A, Debrosse D, Caliandro R, Girard P, et al. Long-term results of endoscopic thoracic sympathectomy for upper limb hyperhidrosis. *Ann Thor Surg.* 2003;75:1075-9.
13. Atkinson JL, Fealey RD. Sympathectomy instead of sympathectomy for palmar hyperhidrosis: minimizing postoperative compensatory hyperhidrosis. *Mayo Clin Proc.* 2003;78:167-72.
14. Dewey TM, Herbert MA, Hill SL, Prince SL, Mack MJ, et al. One year follow up after thoracoscopic sympathectomy for hyperhidrosis: outcomes and consequences. *Ann Thorac Surg.* 2006;81:1227-33.
15. Kim KT, Lee SA. Thoracoscopic T3-sympathectomy for palmar hyperhidrosis. Presented at the 3rd International symposium on Thoracoscopic Sympathectomy, Kanazawa, Japan. May 13-14, 1999.
16. Reisfeld R, Nguyen R, Pnini A. Endoscopic thoracic sympathectomy for treatment of essential hyperhidrosis syndrome: experience with 650 patients. *Surg Laparosc Endosc Percutan Tech.* 2000;10:5-10.
17. Reisfeld R, Nguyen R, Pnini A. Endoscopic thoracic sympathectomy for hyperhidrosis: experience with both cauterization and clamping methods. *Surg Laparosc Endosc Percutan Tech.* 2002;12:255-67.
18. Neumayer C, Panhofer P, Zacherl J, Bischof G. Effect of endoscopic thoracic sympathetic block on plantar hyperhidrosis. *Arch Surg.* 2005;140:676-80.
19. Rieger R, Pedevilla S. Retroperitoneoscopic lumbar sympathectomy for the treatment of plantar hyperhidrosis: technique and preliminary findings. *Surg Endosc.* 2007;21: 129-35.
20. Bechara FG, Sand M, Sand D, Altmeyer P, Hoffmann K. Suction-curettage as a surgical treatment of focal axillary hyperhidrosis: recommendation for an aggressive approach. *Plast Reconstr Surg.* 2007;119:1390-1.