

CASES FOR DIAGNOSIS

Long-Standing Cutaneous Lesion on the Forearm

I. Castiñeiras,^a M. M. Vereas,^a T. Yebra-Pimentel,^b and E. Fonseca^a

^aDepartamento de Dermatología and ^bDepartamento de Anatomía Patológica, Hospital Juan Canalejo, A Coruña, Spain

Patient History

A 74-year-old woman with a history of hypertension and hypercholesterolemia consulted for a cutaneous lesion on the right forearm that appeared 3 years earlier and had grown considerably in the last few months.

Physical Examination

The physical examination revealed an oval, well-delimited, erythematous tumor plaque of diameter 3 cm, lumpy surface, and hard consistency on the outer side of the right forearm (Figure 1). No enlarged axillary lymph nodes were palpated.

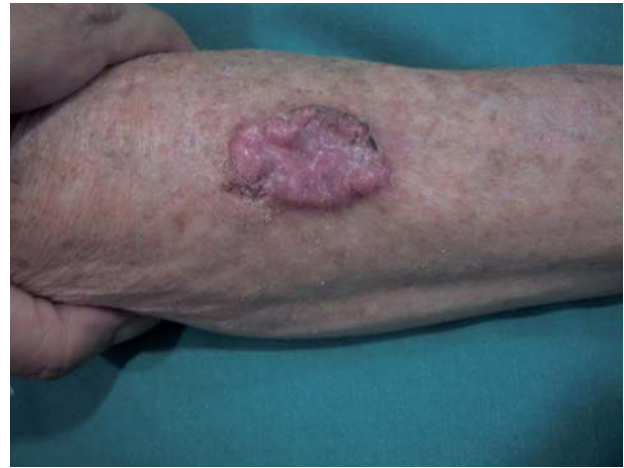

Figure 1.

Additional Examinations

A complete laboratory workup and chest and abdominal computed tomography scans ruled out enlarged regional lymph nodes and dissemination of the disease. An excisional biopsy confirmed the diagnosis.

Histopathology

The mass was composed of basaloid cell nests, with ill-defined intercellular limits, that showed nuclei with noticeable pleomorphism, atypia, and frequent mitoses (Figure 2). The nests often contained small tubules or ducts that were occasionally delimited only by spindle-like cells, and in others, also showed malpighian differentiation of the tumor cells around these tubules. Immunohistochemistry for carcinoembryonic antigen showed staining in the ductal structures and the surrounding cells.

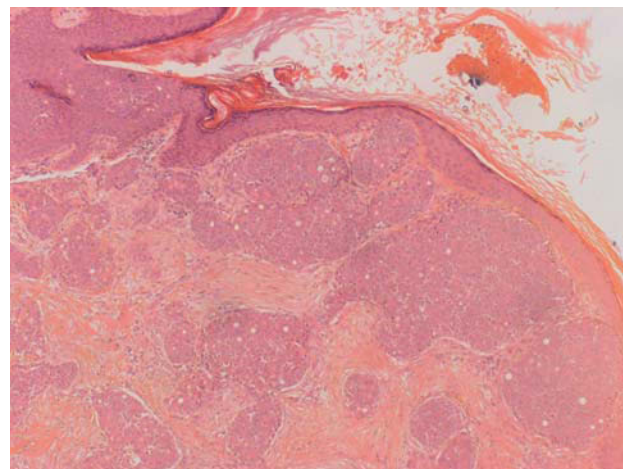


Figure 2. Hematoxylin-eosin, ×20.

What is your diagnosis?

Correspondence:
Iria Castiñeiras Mato
Servicio de Dermatología
Hospital Juan Canalejo
As Xubias, 84
15006 A Coruña, Spain
ireiscas@yahoo.es

Diagnosis

Eccrine porocarcinoma

Course and Treatment

The lesion was excised with 1-cm margins. At the time of writing, the patient had remained asymptomatic, with no evidence of local recurrence or dissemination in the 3 years of follow-up.

Comment

Eccrine porocarcinoma is a rare, but potentially aggressive, malignant skin adnexal tumor that originates in the acrosyringium, the intraepidermal ductal portion of the eccrine sweat glands. It accounts for 0.005% to 0.01% of all skin tumors.¹

The condition is more common in the elderly and found mainly on the legs, but may appear on other areas such as the trunk, arms, head, or neck. The tumor has a variable appearance and usually presents as an ulcerated verrucous plaque or asymptomatic polypoid tumor. Occasionally, there is a long history of an earlier nodule, which suggests the possibility of malignant transformation from a previous benign lesion. The malignant transformation of an eccrine poroma can manifest as ulceration, pain, bleeding, or sudden growth of the lesion. A peculiar form of presentation is porocarcinoma with epidermotropic cutaneous metastases, which manifest as multiple flesh-colored or erythematous violaceous papules or nodules that may be associated with lymphedema if there is lymphatic involvement.^{2,3}

The clinical differential diagnosis includes, among other entities, epidermoid carcinoma, amelanotic melanoma, cutaneous lymphomas, Merkel cell carcinoma, dermatofibrosarcoma protuberans, and other skin adnexal tumors.

Histologically, eccrine porocarcinoma is characterized by well-circumscribed nests and islets of atypical basaloid cells within the epidermis. The extent of dermal involvement is variable and characterized by irregular nests of neoplastic cells that show pronounced atypia and mitotic activity. The epithelial component shows areas with ductal differentiation features that range from ducts of variable

maturity to focal intracytoplasmic lumens. Lymphatic or vascular invasion, a high number of mitoses, or a tumor depth greater than 7 mm are considered indicators of poor prognosis.⁴ Immunohistochemistry reveals neoplastic cells that are positive for carcinoembryonic antigen, cytokeratin, and epithelial membrane antigens; S-100 staining is negative.

Eccrine porocarcinoma is a tumor that is clinically and histologically hard to diagnose, and this sometimes delays treatment and increases the probability that the disease will spread.

Treatment consists of tumor excision with wide margins and cures 80% of cases. However, in 20% of patients, local recurrence occurs months or even years after complete excision. About 20% of tumors produce regional lymph node metastases a few months after excision of the primary tumor; distant metastasis occurs in 10% of patients. Metastatic eccrine porocarcinoma is extremely resistant to adjuvant chemotherapy and radiotherapy, and therefore, patients with metastatic disease have a poor prognosis and high mortality.^{5,6}

Conflicts of Interest

The authors declare no conflicts of interest.

References

1. Bleier BG, Newman JG, Quon H, Feldman MD, Kent KK, Weinstein GS. Eccrine porocarcinoma of the nose: case report and review of world literature. *Arch Otolaryngol Head Neck Surg.* 2006;132:215-8.
2. Girishkumar H, Kamineni S, Hwang RR, Levy J, Sadler R. Eccrine porocarcinoma. *Dermatol Surg.* 1997;23:583-4.
3. Lozano Orella JA, Valcayo Peñalba A, San Juan CC, Vives Nadal R, Castro Morrondo J, Tuñon Alvarez T. Eccrine porocarcinoma. Report of nine cases. *Dermatol Surg.* 1997;23:925-8.
4. Robson A, Greene J, Ansari N, Kim B, Seed PT, McKee PH, et al. Eccrine porocarcinoma (malignant eccrine poroma): a clinicopathologic study of 69 cases. *Am J Surg Pathol.* 2001;25:710-20.
5. Huet P, Dandurand M, Pignodel C, Guillot B. Metastasizing eccrine porocarcinoma: report of a case and review of the literature. *J Am Acad Dermatol.* 1996;35:860-4.
6. Barzi AS, Ruggeri S, Recchia F, Bertoldi I. Malignant metastatic eccrine poroma. Proposal for a new therapeutic protocol. *Dermatol Surg.* 1997;23:267-72.