

CASE REPORTS

Congenital Dermatofibrosarcoma Protuberans: A Case Report

C Muniesa,^a N Curc3, ^a X Pagerols, ^a M Garc3a-Font, ^a X Tarroch, ^b and P Vives^a

^aServicio de Dermatología, Hospital Mútua de Terrassa, Barcelona, Spain

^bServicio de Anatomía Patológica, Hospital Mútua de Terrassa, Barcelona, Spain

Abstract. Dermatofibrosarcoma protuberans is a rare low-grade fibrohistiocytic tumor with onset normally at ages between 20 and 50 years. It presents as a violaceous plaque or macule with an appearance suggestive of vascular lesion, on which nodular lesions appear later. Histological diagnosis is based on the presence of a spindle-cell tumor arranged in small bundles in a characteristic cartwheel pattern. The local recurrence rate is high but metastases are rare. The treatment is surgical resection with wide margins. The tumor rarely affects children under 16 years of age and it is even less common at birth—only 27 congenital cases have been described in the literature. We describe the case of a 10-year-old boy with dermatofibrosarcoma protuberans present since birth and currently without signs of recurrence.

Key words: dermatofibrosarcoma protuberans, congenital dermatofibrosarcoma protuberans.

DERMATOFIBROSARCOMA PROTUBERANS CONGÉNITO: DESCRIPCIÓN DE UN CASO

Resumen. El dermatofibrosarcoma *protuberans* es un tumor fibrohistiocitario de bajo grado poco común y que suele aparecer en adultos entre los 20 y 50 años de edad. Inicialmente se presenta como una mácula o placa violácea de aspecto vascular sobre la que aparecen posteriormente lesiones nodulares en la superficie. El diagnóstico es histológico y se trata de un tumor de células fusiformes que se disponen en fascículos cortos adoptando un patrón arremolinado característico. Es un tumor con una elevada tasa de recurrencias locales, aunque son raras las metástasis. El tratamiento es quirúrgico con amplios márgenes. Este tumor excepcionalmente afecta a niños menores de 16 años y todavía más raros son los casos congénitos, con sólo 27 casos descritos en la literatura. Se describe el caso de un niño de 10 años de edad con un dermatofibrosarcoma *protuberans* presente desde el nacimiento y sin signos de recurrencia en la actualidad.

Palabras clave: dermatofibrosarcoma protuberans, dermatofibrosarcoma protuberans congénito.

Introduction

Dermatofibrosarcoma protuberans (DFSP) is a low-grade fibrohistiocytic tumor characterized by a high rate of local recurrence. It usually presents between 20 and 50 years of age and is rare in patients younger than 16 years. Even rarer are cases of congenital dermatofibrosarcoma and only 27 cases have been reported in the literature.^{1,2} We report the case of a 10-year-old boy with DFSP present since birth and no signs of recurrence to date.

Case Description

A 10-year-old boy from Morocco with no clinical history of interest consulted for a tumor on his left leg that was present from birth and had grown gradually. Physical examination showed an indurated plaque measuring 9 × 7.5 cm on the inner aspect of the left leg (Figure 1) with 2 peripheral atrophic areas revealing the underlying vascular network. In the center, there were 2 brownish-yellow tumor nodules measuring 1 cm in diameter and another, larger violaceous nodule (Figure 2). Palpation revealed the lesion to be firm and attached to the subcutaneous tissue. X-ray of the tibia and fibula and an ultrasound scan of the soft tissue were normal. A skin biopsy revealed an atrophic epidermis and a dense cellular infiltrate that extended deeply from the papillary dermis (Figure 3). The infiltrate was composed of spindle cells with an elongated nucleus arranged in short bundles in a storiform pattern (Figure 4). The immunohistochemical

Correspondence:

Cristina Muniesa
Servicio de Dermatología
Hospital Mútua de Terrassa
Pl. Doctor Robert, 5
08221 Terrassa, Barcelona, Spain
cristinamuniesa@hotmail.com

Accepted for publication November 8, 2006.

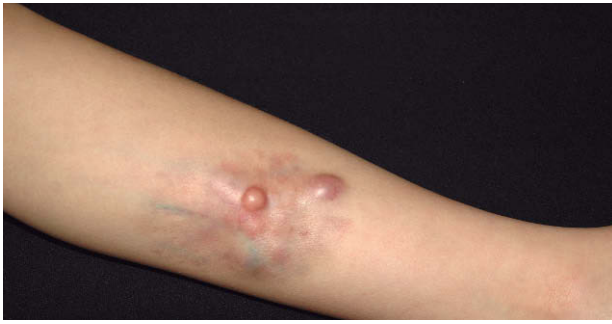

Figure 1. Indurated plaque on the inner aspect of the left leg.

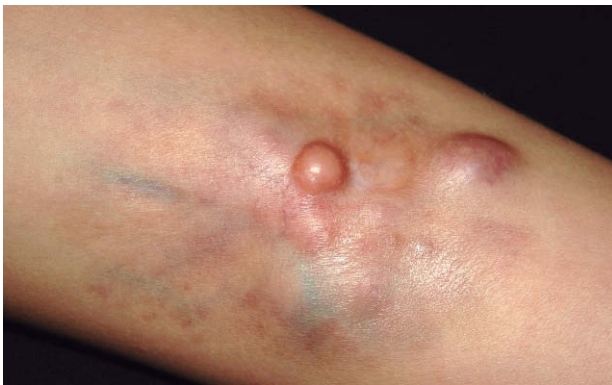

Figure 2. The plaque has a peripheral atrophic area that reveals the underlying veins. In the center, there are 2 brownish-yellow nodules measuring 1 cm in diameter and another, larger violaceous nodule.

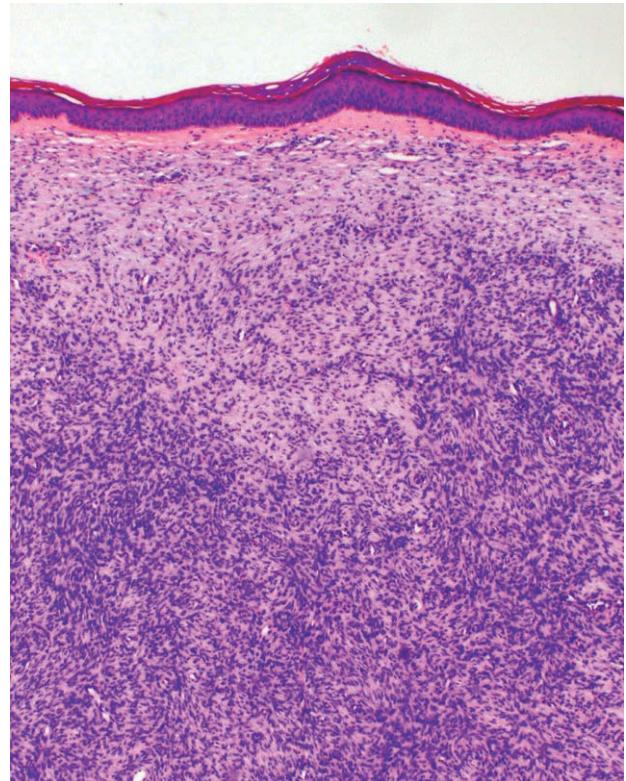


Figure 3. Histology reveals a spindle-cell infiltrate that extends deeply from the papillary dermis (hematoxylin-eosin, $\times 100$).

study showed that the tumor cells were positive for CD34 and tenascin (Figure 5). The combination of histologic and immunohistochemical findings led to a diagnosis of DFSP, which was congenital in this case, given that it was present at birth. After diagnosis, the child underwent wide resection of the tumor. For personal reasons, the procedure was carried out at another center and, to date, we have no reports of a relapse.

Discussion

DFSP is a low-grade fibrohistiocytic tumor that was first described in 1924 by Darier and Ferrand with the name “progressive and recurrent dermatofibroma.” One year later, Hoffman reported 3 new cases and proposed the term dermatofibrosarcoma *protuberans*. This tumor is uncommon and represents 0.1% of malignant tumors.³ It usually presents between 20 and 50 years of age and is rare in children aged less than 16 years (6% of all cases). The congenital form is even more uncommon, with only 27 cases reported in the literature.^{1,2} In general, there is a

greater prevalence in the white population and it is slightly more common in men, although congenital cases are more frequent in women. It is most often found on the trunk and proximal limbs—it is rare on the head and neck—and its clinical presentation is very varied.^{2,4,5} It usually presents as a violaceous or bluish erythematous plaque or macule that is vascular in appearance. It grows slowly over the years and small nodules appear on the plaque surface before becoming nodular or protuberant. The plaque is asymptomatic and indurated, although it can sometimes become ulcerated and painful. It occasionally persists as a nonprotuberant plaque, in which case it is known as atrophic DFSP. In these cases, it usually presents as a violaceous, depressed, and atrophic lesion similar to a scar, with no nodule. In clinical terms, it is often confused with sclerosing basal cell carcinoma, anetoderma, morphea, or a scar. Atrophic DFSP is particularly frequent in congenital cases and during infancy.⁶

Diagnosis of DFSP is based on histology.^{7,8} The tumor cells are spindle-shaped with an elongated nucleus and are arranged in short bundles in a characteristic windmill or storiform pattern. There are few atypical cells and a very small number of mitotic figures. The pattern is one of infiltrative growth that generally extends to the deep

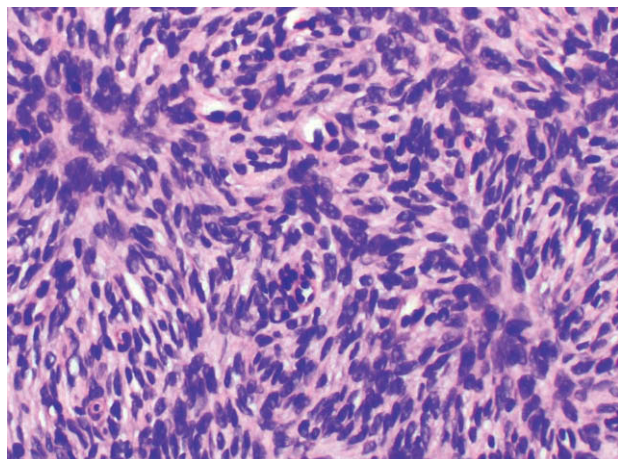


Figura 4. The spindle cells of the infiltrate are arranged in short bundles and assume a windmill pattern (hematoxylin-eosin, $\times 200$)

dermis and subcutaneous cellular tissue. The Bednar tumor is a histological variant of DFSP with melanin-containing dendritic cells between the spindle cells.⁹ Another subtype is the myxoid tumor, with areas of interstitial mucin between the spindle cells.¹⁰ In the immunohistochemical study, it is very important to highlight the positivity of tumor cells with the antibody for CD34, a surface antigen expressed in hematopoietic stem cells, the endothelia, and in the skin (around follicular structures, sebaceous glands, and sweat glands). This antigen may also be present in neoplasms, as is the case with DFSP, and is extremely helpful when differentiating between this and other fibrohistiocytic tumors. Tenascin is a stromal marker of connective tissue that is usually positive in DFSP cells, and this positivity characteristically extends to the subcutaneous cellular tissue. Vimentin is also positive and the other markers (factor XIIIa, S-100, actin, and desmin) are negative. In cytogenetic terms, DFSP is characterized by the reciprocal translocation $t(17;22)(q22;q13)$ that generates a fusion between the gene encoding type 1 collagen on chromosome 17q and the gene for the B chain of platelet-derived growth factor located on chromosome 22q.^{1,3,11}

Clinical diagnosis of DFSP in infants or young people may be awkward because, in the early stages, the tumor often looks like a vascular malformation. The remaining differential diagnoses must be made with fibrohistiocytic tumors such as dermatofibroma, leiomyoma, neurofibroma, dermatomyofibroma, and, for infants, with infantile myofibromatosis and fibrous hamartoma of infancy.^{1,2,7} Dermatofibroma is a more nodular lesion that is limited to the dermis. If it does invade the subcutaneous cellular tissue, it does so via interlobular septa and, unlike DFSP, an immunohistochemical study shows that it is CD34-negative and factor XIIIa-positive. Leiomyoma is

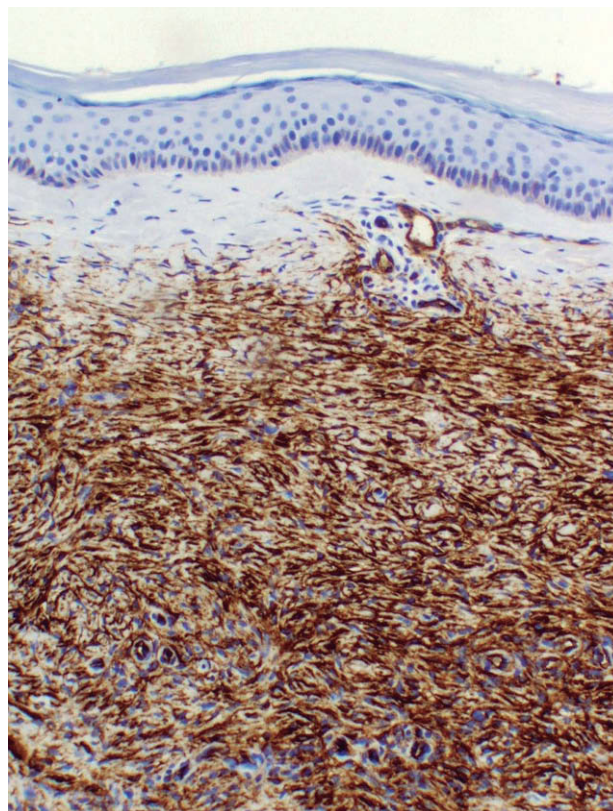


Figura 5. Immunohistochemistry with an antibody against CD34 reveals CD34-positive tumor cells ($\times 100$).

composed of spindle cells with cigar-shaped nuclei that are arranged parallel to the epidermis. If an immunohistochemical study is performed, it shows leiomyoma to be positive for desmin and caldesmon, both of which are negative in DFSP. Neurofibroma has smaller, wavy nuclei and is positive for S-100, an antibody that is consistently negative in DFSP. Dermatomyofibroma is an unusual tumor that presents as an asymptomatic slow-growing plaque. It is common on the neck and shoulders of young adults, particularly women. Histology shows the tumor to have a plaque-like appearance composed of bundles of monomorphic spindle cells arranged parallel to the epidermis. The cells have an eosinophilic cytoplasm and an elongated vesicular nucleus with 1 or 2 nucleoli and express smooth-muscle actin and vimentin. Infantile myofibromatosis is characterized by the appearance of nodular or tumor lesions that are firm and elastic and found mainly on the trunk, shoulders, and thighs. Solitary forms can affect the skin, bone, and viscera. Histology shows the spindle cells to have an eosinophilic cytoplasm and vesicular nuclei arranged in short interlaced bundles. The cellular aggregates are separated by fine bands of collagen and vascular spaces can often be observed in the center of the tumor. Immunohistochemistry shows the

cells to be positive for vimentin and actin. Fibrous hamartoma of infancy is almost completely restricted to prepubertal patients; its characteristic organoid pattern is made up of fibrous collagenous trabeculae, primitive mesenchymal cells, and mature adipose tissue, and it is easy to differentiate it from DFSP by optical microscopy.

Treatment involves wide resection of the tumor with a 2-3 cm margin including the superficial fascia. Radiotherapy is reserved for adjuvant therapy in the case of incomplete resections or large tumors. DFSP is a tumor characterized by marked local invasion and a high rate of local recurrences (between 20% and 50%), especially within the first 3 years after surgery. Mohs micrographic surgery has reduced the rate of recurrence to less than 2% and is considered the treatment of choice.^{1,9} Recent studies show that magnetic resonance imaging may be very helpful as a preoperative instrument for determining the extension and size of the tumor in order to plan surgery and prevent local recurrences.¹ It can also help in postoperative follow-up to detect and monitor tumor recurrence. Clinical check-ups are recommended every 3 to 6 months during the first 3 years following surgery and every year thereafter. Metastasis of DFSP is extremely rare—it has been reported in 16% of patients—and indicates a poor prognosis.^{1,7} The lungs are the most common site of metastasis, by hematogenous spread, followed by metastases in regional lymph nodes, brain, bone, and heart.

Our most noteworthy conclusion is that, when faced with a child presenting plaques or cutaneous nodules—even congenital ones—with no clear clinical diagnosis, it is advisable to perform a biopsy. Furthermore, given the potential for aggressive local invasion and the high rate of recurrence in DFSP, diagnosis should be made early to facilitate suitable resection.

Conflicts of Interest

The authors declare no conflicts of interest.

References

1. Thornton SL, Reid J, Papay FA, Vidimos AT. Childhood dermatofibrosarcoma protuberans: role of preoperative imaging. *J Am Acad Dermatol.* 2005;53:76-83.
2. Weinstein JM, Drolet BA, Esterly NB, Rogers M, Bauer BS, Wagner AM, et al. Congenital dermatofibrosarcoma protuberans: variability in presentation. *Arch Dermatol.* 2003;139:207-11.
3. Checketts SR, Hamilton TK, Baughman RD. Congenital and childhood dermatofibrosarcoma protuberans: a case report and review of the literature. *J Am Acad Dermatol.* 2000;42:907-13.
4. Kahn TA, Liranzo MO, Vidimos AT, Papay FA, Bergfeld WF. Pathological case of the month. Congenital dermatofibrosarcoma protuberans. *Arch Pediatr Adolesc Med.* 1996; 150:549-50.
5. Annessi G, Cimitan A, Girolomoni G, Giannetti A. Congenital dermatofibrosarcoma protuberans. *Pediatr Dermatol.* 1993;10:40-2.
6. Martin L, Piette F, Blanc P, Mortier L, Avril MF, Delaunay MM, et al. French Group for Cutaneous Oncology. Clinical variants of the preprotuberant stage of dermatofibrosarcoma protuberans. *Br J Dermatol.* 2005;153:932-6.
7. Marini M, Saporano A, Magarinos G, de Baldrich A, Lynch P, Remolino L. Congenital atrophic dermatofibrosarcoma protuberans. *Int J Dermatol.* 2001;40:448-50.
8. McKee PH, Fletcher CD. Dermatofibrosarcoma protuberans presenting in infancy and childhood. *J Cutan Pathol.* 1991;18:241-6.
9. Marcus JR, Few JW, Senger C, Reynolds M. Dermatofibrosarcoma protuberans and the Bednar tumor: treatment in the pediatric population. *J Pediatr Surg.* 1998;33:1811-4.
10. Gu W, Ogose A, Kawashima H, Umezu H, Kudo N, Hotta T, et al. Congenital dermatofibrosarcoma protuberans with fibrosarcomatous and myxoid change. *J Clin Pathol.* 2005;58:984-6.
11. Llombart B, Sanmartín O, López-Guerrero JA, Monteagudo C, Calabuig S, Botella R, et al. Análisis del gen de fusión COL1A1-PDGFB en un caso de dermatofibrosarcoma protuberans con componente de fibrosarcoma. *Actas Dermosifiliogr.* 2006;97:337-41.