

## CASE REPORTS

# Folliculotropic Mycosis Fungoides. Study of Four Cases

S Gómez-Diez,<sup>a</sup> C Maldonado,<sup>a</sup> A Fueyo,<sup>a</sup> F Vázquez-López,<sup>a</sup> MF Fresno,<sup>b</sup> and N Pérez-Oliva<sup>a</sup>

<sup>a</sup>Servicio de Dermatología and <sup>b</sup>Servicio de Anatomía Patológica, Hospital Universitario Central de Asturias, Universidad de Oviedo, Asturias, Spain

**Abstract.** Folliculotropic mycosis fungoides is a variant of mycosis fungoides characterized by the presence of folliculotropic infiltrates, often with sparing of the epidermis, and preferential involvement of the head and neck. We report our experience with 4 cases of folliculotropic mycosis fungoides followed in our department in the last years. There are four patients (3 men and 1 woman) aged 45 to 68 years. Clinically the lesions presented as cysts, comedones, follicular papules and plaques with follicular plugging. The histopathological study showed a peri and intrafollicular infiltrate with partial or total sparing of the epidermis. This infiltrate was mainly composed of atypical lymphocytes. Some cystic formations were also observed. Three cases showed mucin deposits and 1 showed syringotropism. The immunohistochemical analysis was positive for CD3, CD5 and CD4. All patients received different treatments based on the stage of their disease. One of them died of septic shock and the rest showed partial responses and frequent relapses.

**Key words:** mycosis fungoides, folliculotropic, mucin.

## MICOSIS FUNGOIDE FOLICULAR. ESTUDIO DE CUATRO CASOS

**Resumen.** La micosis fungoide folicular (MFF) es una variante de micosis fungoide (MF) caracterizada por la presencia de infiltrados foliculares, a menudo respetando la epidermis, y con afectación preferente de cabeza y cuello. Presentamos nuestra experiencia con 4 casos de MFF vistos en nuestro Servicio en los últimos años. Se trata de 4 pacientes (tres varones y una mujer) con edades comprendidas entre los 45 y 68 años. Clínicamente las lesiones se presentaron en forma de quistes, comedones, pápulas foliculares y placas con acentuación folicular. El estudio histopatológico mostró un infiltrado de distribución peri e intrafollicular con la epidermis parcial o totalmente respetada. Este infiltrado estaba formado principalmente por linfocitos atípicos. Se apreciaban también algunas formaciones quísticas. En tres casos se observaron depósitos de mucina y en uno sirringotropismo. El análisis inmunohistoquímico fue positivo para los marcadores CD3, CD5 y CD4. Todos los pacientes recibieron diferentes tratamientos en función del estadio de su enfermedad. Uno de ellos falleció de shock séptico y el resto presentó respuestas parciales y recidivas frecuentes.

**Palabras clave:** micosis fungoide, folicular, mucina.

## Introduction

Follicular or folliculotropic mycosis fungoides (FMF) is a variant of mycosis fungoides (MF). It is characterized by follicular infiltrates, often with sparing of the epidermis, and preferential involvement of the head and neck.<sup>1</sup> In the current World Health Organization–European Organization for Research and Treatment of Cancer

(WHO-EORTC) consensus classification of cutaneous lymphomas, FMF included both the so-called MF-associated follicular mucinosis and pilotropic or follicular MF without the presence of mucin, as no differences in its clinical presentation or prognosis were observed.<sup>1</sup>

FMF is more common in men. Clinically, the lesions present as cysts, comedones, follicular hyperkeratosis, follicular papules, plaques with follicular plugging, and sometimes, tumors.<sup>2-15</sup> These lesions are often accompanied by alopecia.<sup>1,6,9-14</sup> Most patients experience moderate-to-severe pruritus<sup>10</sup> and, in some cases, follicular mucinosis is also present.<sup>6,10,13</sup>

FMF is believed to have a worse prognosis<sup>1,16,17</sup> and behaves in a similar or identical way to the tumor stage of classic MF.<sup>1,10</sup>

Correspondence:

Santiago Gómez Díez  
Cardenal Cienfuegos n.º 2, Esc. 3, 2.ªA  
33007 Oviedo, Asturias, Spain  
E-mail: sangodi@telefonica.net

Manuscript accepted for publication October 26, 2006.

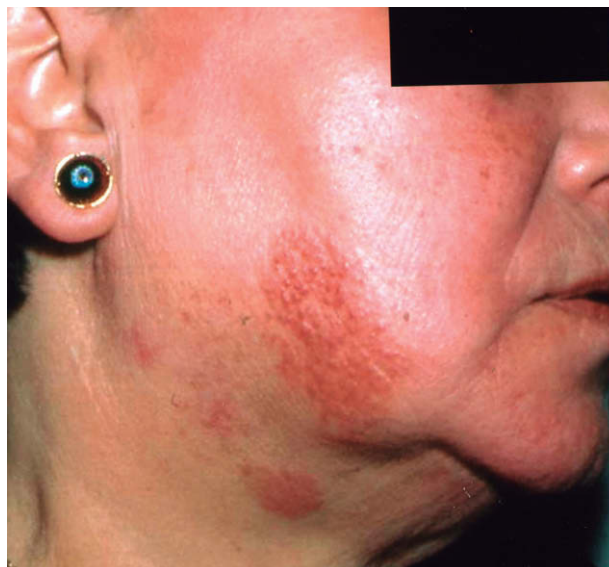We describe 4 cases of FMF attended in our dermatology department during the last few years.

## Case Descriptions

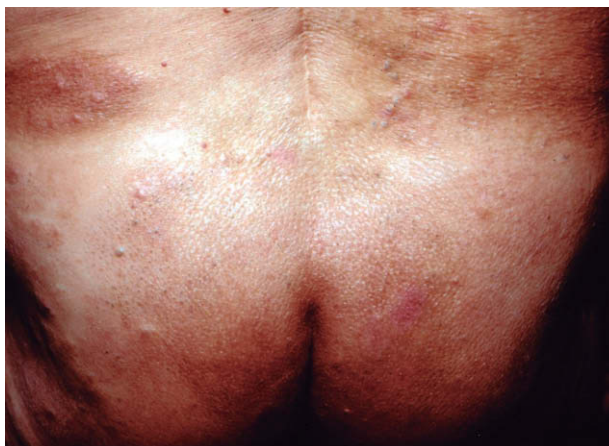**Case 1:** A 68-year-old woman presented with pink plaques that had first appeared around 25 years earlier. The plaques showed no infiltrate, many had follicular plugging, and they were spread over the trunk, proximal limbs, and face (Figure 1). During the last 2 years, comedo-type lesions had appeared on the head and neck. Further examination did not disclose extracutaneous involvement and the patient was diagnosed with stage IB (T2N0M0) MF. She underwent treatment with topical corticosteroids, topical carmustine and mechlorethamine, and psoralen-UV-A (PUVA). Complete or partial remission was achieved, but with subsequent relapses.

**Case 2:** A 65-year-old man presented with lesions that first appeared 9 years previously as erythematous cutaneous plaques at waist-height that later spread over the rest of the body. When the patient first came to our department 3 years ago, examination revealed pink infiltrated plaques with follicular plugging, follicular papules, and comedo-type lesions on the face, trunk, and limbs (Figure 2). A tumor was observed on the upper lip. General examination revealed small enlarged mobile lymph nodes in the groin—histologic examination of the nodes revealed dermatopathic lymphadenitis. Analysis of extension did not reveal involvement of internal organs. Following a diagnosis of stage IIB (T3N1M0) MF, treatment with total skin electron beam irradiation was prescribed and a complete response was obtained. A year later some plaques had returned and the patient is currently receiving oral bexarotene.

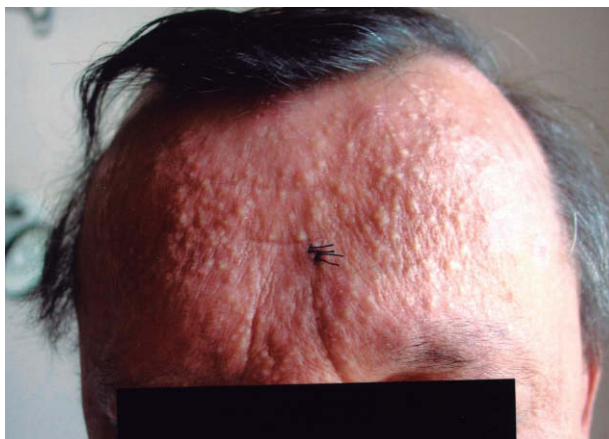**Case 3:** A 45-year-old man presented with skin lesions that first appeared 6 years previously in the form of microcysts on the face and forehead (Figure 3), plaques on the trunk, and alopecia of the scalp and eyebrows. These lesions worsened and in recent years some tumors developed on the scalp. The most notable observation in the laboratory workup was the presence of 33% eosinophils. Computed tomography of the trunk, abdomen, and pelvis revealed multiple pulmonary nodules. These were examined by the pulmonology department and were related to his lymphoma, although this was not confirmed by histologic or cytologic testing. The pulmonary lesions progressed alongside the cutaneous lesions. The patient was diagnosed with stage IVB (T3N0M1) MF and was prescribed chemotherapy (6 cycles with CHOP) followed by total skin electron beam irradiation, which led to partial resolution of the lesions. He currently has disseminated cutaneous tumors and multiple pulmonary nodules and is treated with methotrexate at 50 mg/wk.



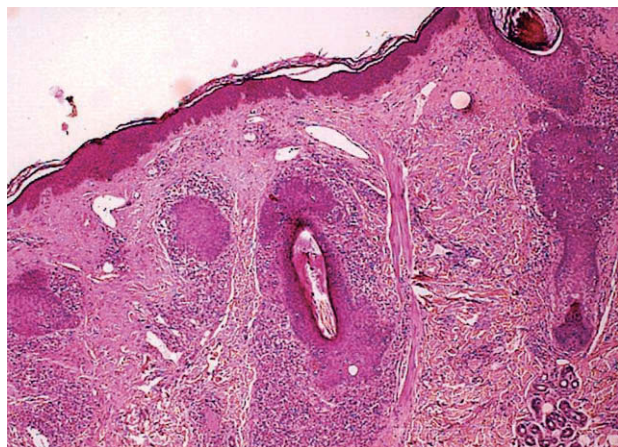**Figure 1.** Pink plaque with follicular plugging on the face.



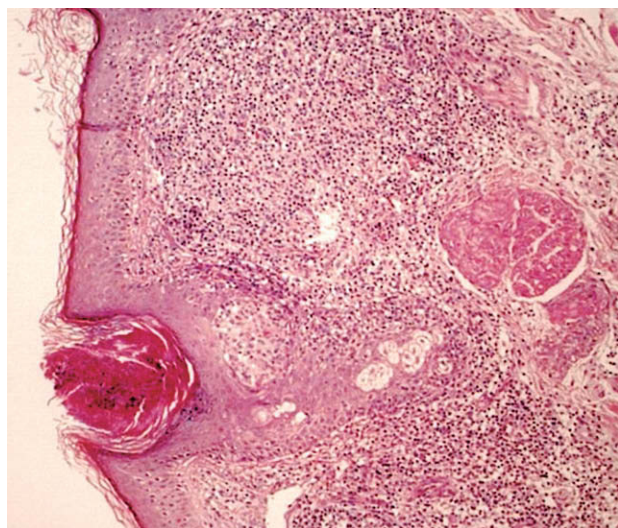
**Figure 2.** Pink plaques and cystic lesions that look like comedones.



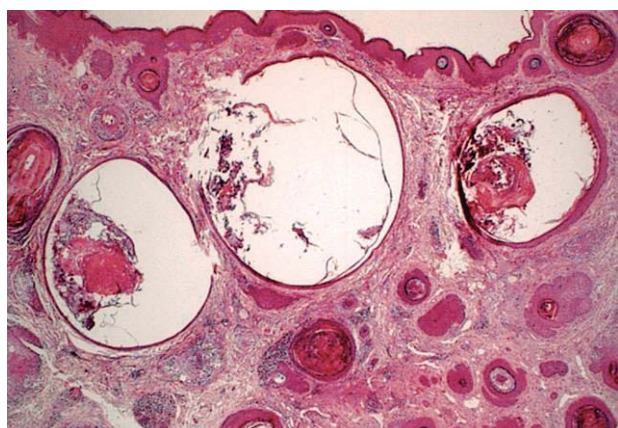
**Figure 3.** Multiple cysts on the forehead.



**Figure 4.** Infiltrates with a perifollicular and intrafollicular distribution and sparing of the epidermis (hematoxylin-eosin  $\times 50$ ).



**Figure 5.** Perifollicular infiltrate with Pautrier microabscesses on the epithelium of the follicle (hematoxylin-eosin  $\times 200$ ).



**Figure 6.** Cystic structures in the dermis (hematoxylin-eosin  $\times 50$ ).

Case 4: A 68-year-old male presented with a one-and-a-half year history of follicular papules and generalized plaques, some of which had progressed to tumors. Palpation revealed enlarged submandibular, axillary, and inguinal lymph nodes. Histologic examination revealed partial obliteration of the node structure and specific infiltration due to MF. Laboratory workup showed high levels of lactate dehydrogenase (444 U/L). The patient was diagnosed with stage IVA (T3N3M0) MF and was prescribed 4 cycles of chemotherapy with CHOP. The skin lesions improved but the patient died of septic shock.

The different skin biopsies revealed common findings within a wide range of observations, with varying degrees of severity. These involved perifollicular and intrafollicular infiltration with partial or complete sparing of the epidermis (Figure 4). The infiltrate was composed mainly of small and medium-sized atypical cerebriform lymphocytes that formed small nests in some cases (Pautrier microabscesses) (Figure 5). A smaller number of eosinophils, plasma cells, and cells with a histiocytic appearance were also observed. Sometimes the affected hair follicles exhibited dilation of their lumen leading to cystic formations covered with squamous epithelia. In case 4, “clean” cysts, with no surrounding inflammatory infiltrate, were also observed alongside this type of cyst (Figure 6). In some of the follicles in cases 2, 3, and 4, an Alcian blue-positive lacunar structure with clear basophilic content was observed (follicular mucinosis). In case number 4, there was also infiltration of atypical lymphocytes around the eccrine sweat glands (syringotropism).

The immunohistochemical analysis was carried out on paraffin sections using the EnVision system with an automated TechMate staining apparatus (Dako, Glostrup, Denmark). A pan B marker panel (CD20 and CD79a) and T cell markers (CD3, CD5, CD8, and CD4) were used, as well as the activation antigen CD30 and proliferation marker Ki67. The analysis was positive for CD3, CD5, and CD4 and negative for CD30 and CD20, indicating a memory T helper phenotype.

## Discussion

The term follicular mycosis fungoides was first used by Kim<sup>18</sup> in 1985 to highlight the difficulty in diagnosing 2 cases of MF with infiltrates limited to the hair follicle and perifollicular dermis. At present, the WHO-EORTC consensus classification of cutaneous lymphoma recognizes FMF as an unusual clinical variant of MF in which the neoplastic lymphocytes surround and infiltrate the epithelium of the hair follicle while sparing the epidermis.<sup>1</sup>

Little is known about the etiology of FMF, although it has been suggested that the epithelium of the hair follicle might express higher levels of skin-selective homing re-

ceptors and adhesion molecules than the epidermis, leading to preferential tropism of the neoplastic lymphocytes towards the follicle.<sup>8</sup> Consistent with this possibility, Hodak et al<sup>9</sup> found exclusive expression of ICAM-1 in the membrane of the follicular epithelium in FMF lesions; however, classic MF lesions expressed ICAM-1 throughout the epidermis. Furthermore, the mechanical obstruction of the hair follicle brought about by infiltration can also lead to the formation of cysts.<sup>3,19</sup>

From a clinical viewpoint, the morphology of the lesions is quite characteristic—they generally appear as follicular papules, plaques with follicular plugging, or cysts and comedones.<sup>2-15</sup> In some cases, tumors<sup>10</sup> or pseudotumors<sup>20</sup> can appear. Patients with FMF can also display concomitant classic or conventional MF lesions.<sup>2,4,9</sup>

In all our patients, MF in the form of plaques and, sometimes, tumors presented alongside characteristic FMF lesions. The latter, which were predominant, involved microcysts (which sometimes looked like comedones), follicular papules (which sometimes came together in plaques), plaques with follicular plugging, and alopecia of the scalp and eyebrows. Particularly noteworthy was case 1, in which the only manifestations during the last 2 years were comedo-type lesions on the face and neck that looked like acne or an acneiform eruption but for which histological analysis revealed findings typical of FMF.

The histopathology of FMF is characterized by a perivascular and periadnexal dermal infiltrate, with variable infiltration of the follicular epithelium by atypical cerebriform lymphocytes of different sizes.<sup>1,10,21</sup> It is sometimes accompanied by mucinosis<sup>1,10,13,21</sup> and the epidermis is generally spared.<sup>10</sup> In some cases, in addition to folliculotropism, syringotropism,<sup>9,10,13,22</sup> and even squamous syringometaplasia<sup>22</sup> can be observed. In 3 of our patients (cases 2, 3, and 4), the characteristic folliculotropic infiltrate was accompanied by the presence of follicular mucinosis and, in case 4, an atypical lymphocytic infiltrate was observed around the eccrine sweat glands (syringotropism).

In most cases, the neoplastic T lymphocytes are CD3+, CD4+, and CD8-, as in classic MF.<sup>1</sup> A small number of disperse CD30+ blast cells are also frequently found.<sup>1,10</sup> The presence of a considerable number of CD30+ or CD30- blast cells (> 15%) has been associated with a worse prognosis.<sup>10</sup>

The clinical differential diagnosis is particularly important in cases where the lesions appear on healthy skin without the typical lesions of MF. This should be made with entities such as follicular lichen planus, Favre-Racouchot disease, acne, and epidermal cysts produced by nitrogen mustards or other topical products.<sup>23</sup>

One of the main characteristics of FMF is its prognostic behavior. Van Doorn et al<sup>24</sup> found progression of the disease at 10 years in 89% of 32 patients with MF associated with follicular mucinosis compared with 32% of

277 patients with MF and no follicular mucinosis. Bonta et al<sup>17</sup> reviewed prognosis in a report of rapidly progressive MF that presented with follicular mucinosis and found that 7% of cases of FMF progressed quickly to lymph node involvement compared with less than 3% for the classic form of MF. A study by van Doorn et al<sup>10</sup> involving 51 patients with MFF revealed a survival rate of 68% at 5 years and 26% at 10 years. When the same authors compared 49 patients with FMF limited to the skin with 122 patients with MF in generalized plaques and 36 with tumoral MF, they found that the patients with FMF had fewer complete remissions after the initial treatment, and that both mean survival and disease-related survival in the FMF patients was similar to (at 5 years) or even worse than (at 10 years) those with tumor-stage MF and no associated follicular mucinosis.

In the patients we have had the opportunity to study over the years, we can confirm the worse prognosis of this form of MF. Case 1 can be considered an exception to the norm, as it involves a patient with a stable condition that developed over a very long period (25 years), indicating that progression to more severe forms is not inevitable.

As for treatment, the deep perifollicular and intrafollicular location of the infiltrates means that therapy targeting the skin, such as PUVA and topical nitrogen mustards, are less efficacious.<sup>1</sup> As a result, total skin electron beam irradiation has been considered effective, although complete remission occurs in only a few cases. A good alternative can be found in PUVA combined with retinoids or interferon, whereas persistent tumors can be treated with local radiotherapy.<sup>1,10</sup> Chemotherapy should be restricted to those patients with extracutaneous involvement.<sup>10</sup> There have been isolated reports of cases that have responded well to isotretinoin<sup>25,26</sup> and bexarotene.<sup>27</sup>

In the cases we describe here, it is difficult to draw conclusions about the treatment, as the patients were in different stages of the disease. However, we do feel that it is interesting to highlight the favorable response to topical chemotherapy and PUVA shown by our first case, probably due to the fact that it involved superficial lesions that had little or no infiltration. In this sense, the experience of Hodak et al<sup>9</sup> was also positive, as they found that some of their patients with FMF benefited from phototherapy.

#### Conflicts of Interest

The authors declare no conflicts of interest.

## References

1. Willenze R, Jaffe ES, Burg G, Cerroni L, Berti E, Swerdlow SH, et al. WHO-EORTC classification for cutaneous lymphomas. *Blood*. 2005;105:3768-85.
2. Radeff B, Mérot Y, Saurat J. Acquired epidermal cysts and mycosis fungoides. A possible pitfall in clinical staging. *Am J Dermatopathol*. 1988;10:424-9.

3. Oliwiecki S, Ashworth J. Mycosis fungoides with a widespread follicular eruption, comedones and cysts. *Br J Dermatol.* 1992;127:54-6.
4. Lacour JP, Castanet J, Perrin C, Ortonne JP. Follicular mycosis fungoides. A clinical and histologic variant of cutaneous T-cell lymphoma: report of two cases. *J Am Acad Dermatol.* 1993;29:330-4.
5. Goldenhersh MA, Zlotogorski A, Rosenmann E. Follicular mycosis fungoides. *Am J Dermatopathol.* 1994;16:52-5.
6. Dauden Tello E, Valks R, Vargas-Díez E, Porras Luque JJ, Fernández-Peñas P, Aragües Montañes M. Mucinosis follicular y micosis fungoide. Estudio de cinco casos y revisión de la literatura. *Actas Dermosifiliogr.* 1996;87:450-8.
7. Miralles J, Pujol RM, Sole J, Casanovas JM, Moragas JM. Micosis fungoide foliculotropa. *Actas Dermosifiliogr.* 1996; 87:467-70.
8. Pereyo NG, Requena L, Galloway J, Sangüeza OP. Follicular mycosis fungoides: A clinicopathologic study. *J Am Acad Dermatol.* 1997;36:563-8.
9. Hodak E, Feinmesser M, Segal T, Yosipovitch G, Lapidoth M, Maron L, et al. Follicular cutaneous T-cell lymphoma: a clinicopathological study of nine cases. *Br J Dermatol.* 1999; 141:315-22.
10. van Doorn R, Scheffer E, Willemze R. Follicular mycosis fungoides, a distinct disease entity with or without associated follicular mucinosis. A clinicopathologic and follow-up study of 51 patients. *Arch Dermatol.* 2002;138:191-8.
11. Monopoli A, Annessi G, Lombardo GA, Baliva G, Girolomoni G. Purely follicular mycosis fungoides without mucinosis: Report of two cases with review of the literature. *J Am Acad Dermatol.* 2003;48:448-52.
12. Palencia Pérez S, Segurado Rodríguez A, Rodríguez Peralto JL, Vanaclocha Sebastián F, Iglesias Díez L. Micosis fungoide folicular cutánea y ganglionar. *Actas Dermosifiliogr.* 2003;94:24-7.
13. Ruiz-Genao D, Ballesteros M, Fraga J, García-Díez A, Fernández-Herrera J. Micosis fungoide folicular, comedoniana y quística. *Actas Dermosifiliogr.* 2005;96:102-5.
14. Sánchez-Sambucetes P, Ingelmo J, Alonso T, Rodríguez-Prieto M. Erupción de pápulas foliculares y comedones localizados en el abdomen y en el labio superior. *Actas Dermosifiliogr.* 2006;97:71-2.
15. Merlet S, Dandurand M, Elmajaoui S, Joujoux JM, Ligeron C, Michel B, et al. Mycosis fungoide tumoral et pilotrope sans mucine: évolution vers une érythrodermie pustuleuse. *Ann Dermatol Venereol.* 2006;133:149-52.
16. Klemke CD, Dippel E, Assaf C, Hummel M, Stein H, Goerdts S, et al. Follicular mycosis fungoides. *Br J Dermatol.* 1999;141:137-40.
17. Bonta MD, Tannous ZS, Demierre MF, González E, Harris NL, Duncan LM. Rapidly progressing mycosis fungoides presenting as follicular mucinosis. *J Am Acad Dermatol.* 2000;43:635-40.
18. Kim SY. Follicular mycosis fungoides. *Am J Dermatopathol.* 1985;7:300-1.
19. Kim LA, Barr RJ, Gottschalk HL. Mycosis fungoides with underlying epidermoid cysts. *Arch Dermatol.* 1979;115:622.
20. Kossard S, Weller P. Pseudotumorous folliculotropic mycosis fungoides. *Am J Dermatopathol.* 2005;27:224-7.
21. Flaig MJ, Cerroni L, Shuhmann K, Bertsch HP, Kind P, Kaudewitz P, et al. Follicular mycosis fungoides. A histopathologic analysis of nine cases. *J Cutan Pathol.* 2001; 28:525-30.
22. Jacobs MA, Kocher W, Murphy GF. Combined folliculotropic/syringotropic cutaneous T-cell lymphoma without epidermal involvement: report of 2 cases and pathogenic implications. *Hum Pathol.* 2003;34:1216-20.
23. Peris K, Chimenti S, Sacerdoti G, Muscardin L, Fazio M. Pilotropic mycosis fungoides. *Dermatology.* 1999;199:192-4.
24. van Doorn R, van Haselen CW, van Voorst Vader PC, Geerts ML, Heule F, de Rie M, et al. Mycosis fungoides. Disease Evolution and Prognosis of 309 Dutch Patients. *Arch Dermatol.* 2000;136:504-10.
25. Vergier B, Beylot-Barry M, Beylot C, de Mascarel A, Delaunay M, de Muret A, et al. Pilotropic cutaneous T-cell lymphoma without mucinosis: A variant of mycosis fungoides? *Arch Dermatol.* 1996;132:683-7.
26. Leverkus M, Rose C, Bröcker EB, Goebeler M. Follicular cutaneous T-cell lymphoma: beneficial effect of isotretinoin for persisting cysts and comedones. *Br J Dermatol.* 2005; 152:193-4.
27. Shistik G, Scalf LA, Fenske N, Glass LF. Follicular mycosis fungoides: successful treatment with oral bexarotene. *J Drugs Dermatol.* 2004;3:301-4.