

ORIGINAL ARTICLES

Pulsed Dye Laser Treatment of Acne. Study of Clinical Efficacy and Mechanism of Action

A Harto, I García-Morales, P Beldar, and P Jaén

Unidad de Dermatología, Hospital Universitario Ramón y Cajal, Madrid, Spain

Abstract. *Introduction.* Acne vulgaris is a multifactorial disease of the pilosebaceous unit characterized by the development of inflammatory (papules, pustules, cysts) and/or non inflammatory lesions (open and closed comedones) that may progress to scars. The increase of bacterial resistances, adverse effects and teratogenicity of retinoids and lack of response to usual therapies have led to investigate new therapeutic alternatives for acne.

Material and method. We studied 36 patients with mild to moderate acne vulgaris. We performed treatment every 4 weeks using pulsed dye laser therapy with a wavelength of 585 nm and pulse duration of 350 microseconds.

Results. At twelve weeks of treatment a decrease of 27% of non inflammatory lesions and of 57% of active lesions was observed. Treatment was well tolerated and considered positive, in terms of healing, in 25 patients.

Conclusions. Pulse dye laser therapy mainly improves inflammatory lesions of acne with few adverse effects.

Key words: acne vulgaris, phototherapy, laser.

LÁSER DE COLORANTE PULSADO EN EL TRATAMIENTO DEL ACNÉ. ESTUDIO DE LA EFICACIA CLÍNICA Y MECANISMO DE ACCIÓN

Resumen. *Introducción.* El acné vulgar es una enfermedad multifactorial de la unidad pilosebácea caracterizada por la aparición de lesiones inflamatorias (pápulas, pústulas, quistes) y/o no inflamatorias (comedones cerrados y abiertos) que pueden evolucionar al desarrollo de cicatrices. El aumento de las resistencias bacterianas, los efectos adversos y teratogenicidad de los retinoides y la falta de respuesta a tratamientos habituales llevan a la necesidad de investigar nuevas opciones terapéuticas para el acné.

Material y métodos. Estudiamos a 36 pacientes con acné vulgar de grado leve a moderado. Realizamos tratamiento cada 4 semanas utilizando un láser de colorante pulsado de 585 nm de longitud de onda y 350 microseg de duración de pulso.

Resultados. A las doce semanas de tratamiento se observa descenso del 27% de lesiones no inflamatorias y de un 57% de lesiones activas. El tratamiento fue bien tolerado y considerado como positivo, en cuanto a curación, en 25 pacientes.

Conclusiones. El láser de colorante pulsado mejora principalmente las lesiones inflamatorias del acné con pocos efectos adversos.

Palabras clave: acné vulgar, fototerapia, láser.

Introduction

Acne vulgaris is characterized by the development of inflammatory and noninflammatory skin lesions that may lead to scarring.

The first step in the development of acne is the formation of microcomedones, which are caused by abnormal keratinization of the infundibulum. The microcomedones then expand to form comedones. Elevated numbers of corneocytes are associated with increased levels of the cell proliferation marker Ki-67. In vitro experiments have shown that the proinflammatory cytokine interleukin 1 α (IL-1 α) also plays a role.

In terms of the role of *Propionibacterium acnes* in the pathogenesis of acne, it has been shown to stimulate production of proinflammatory mediators (IL-1 α , tumor necrosis factor- α [TNF- α], and granulocyte-macrophage colony stimulating factor [GM-CSF]) in keratinocytes, an

Correspondence: Antonio Harto Castañeros.
Departamento de Dermatología. Hospital Ramón y Cajal.
Ctra. de Colmenar Viejo, km 9, 100. 28034 Madrid. Spain
E-mail: antonlonarto@hotmail.com
renegmorales@gmail.com

Manuscript accepted for publication February 8, 2007.

action which increases comedo formation by stimulating hyperkeratinization.^{1,2} Recently, *P. acnes* has been shown to have a mitogenic effect on T cells, which contribute to the inflammation associated with acne through release of inflammatory cytokines. For this to happen, though, the follicular wall has to rupture to bring *P. acnes* into contact with the macrophages.¹

The pathogenesis of acne may be blocked by photochemical, thermal, or even photoimmunological mechanisms. Interventions can be based on 2 fundamental approaches: selective photothermolysis and generalized water heating.

The search for suitable light sources for treating acne should take into account the possible chromophores which might absorb the light, namely, *P. acnes*, the sebaceous glands, and hypervascularization associated with inflammation.³

We studied the efficacy and tolerability of a pulsed dye laser in patients with mild-to-moderate acne vulgaris.

Materials and Methods

Patients

In this prospective study conducted between April and July, 2004, we recruited 36 patients with mild-to-moderate acne vulgaris who had at least 10 inflammatory lesions. Of these 36 patients, only the 30 who completed the 12 weeks of follow-up were included in the analysis. The other 6 patients either withdrew from the study or were lost to follow-up after the first treatment.

The patients were residents of the health care district corresponding to the Hospital Universitario Ramón y Cajal, Madrid, Spain. All agreed voluntarily to receive treatment and, in all cases, signed informed consent was obtained. The age of the patients ranged from 14 to 35 years (mean age, 20 years), and the group included 17 women and 13 men.

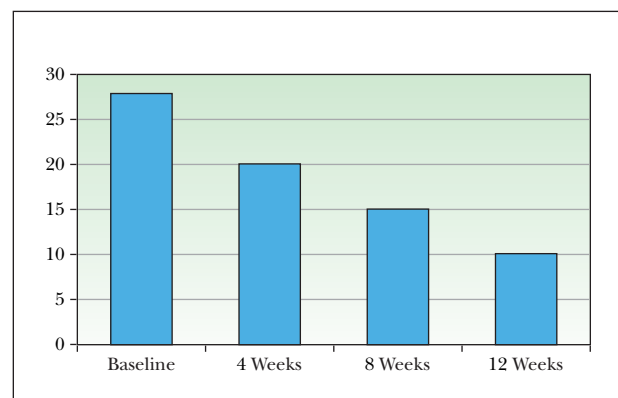


Figure 1. Noninflammatory skin lesions.

Study Course

The total number of inflammatory lesions (papules, pustules, and cysts) and noninflammatory lesions (closed and open comedones) was determined before each treatment. Photographs were taken with an Olympus C5050 digital camera.

The coherent light source was a pulsed dye laser operating at a wavelength of 585 nm with a pulse duration of 350 μ s (NLite EUPhotonics, Llanelli, UK). A subpurpuric fluence of 2.5 J/cm² was applied. Patients were treated once every 4 weeks until 3 sessions had been completed. Outcomes were assessed 12 weeks after the first treatment. Improvement in acne severity and adverse reactions to the treatment were analyzed. Lesions were assessed at baseline and 4, 8, and 12 weeks after the first treatment.

Statistical Analysis

All data were processed with Microsoft® Excel from the Office 2000 software suite. Variables were compared with nonparametric tests, specifically the Wilcoxon signed-rank test ($P < .001$).

Results

In total, 30 patients completed the study. These patients received 12 sessions of treatment. The mean age was 20 years, with a range of 14 to 35 years. The sex distribution was as follows: 13 women and 17 men.

The baseline noninflammatory lesion count (closed and open comedones) was 1215. A reduction of 27%—882 inactive lesions in total—was reported after completing the 12 sessions (Figure 1).

The total number of inflammatory lesions (papules, pustules, constant red spots) at baseline in the study group was 1375. After completing 12 sessions of treatment, 591 active lesions were reported, a reduction of 57% (Figure 2).

According to the subjective patient satisfaction with the treatment outcome, 25 of the 30 patients considered the treatment positive as they saw an improvement, even though the lesions did not heal completely. Of the 5 remaining patients, 4 reported no improvement in their acne and 1 reported deterioration (Figures 3 to 5).

Treatment of acne vulgaris with a pulsed dye laser seems to have a greater effect on the inflammatory component of the acne given that the greatest decrease is seen in the number of active lesions. In our study, the overall decrease in the number of acne lesions compared to baseline before starting therapy was statistically significant ($P < .001$) (Table).

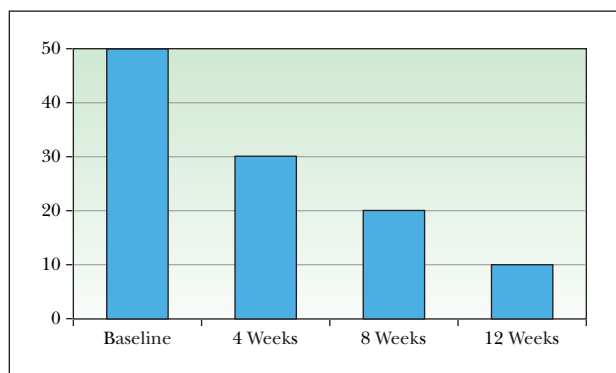


Figure 2. Inflammatory skin lesions.

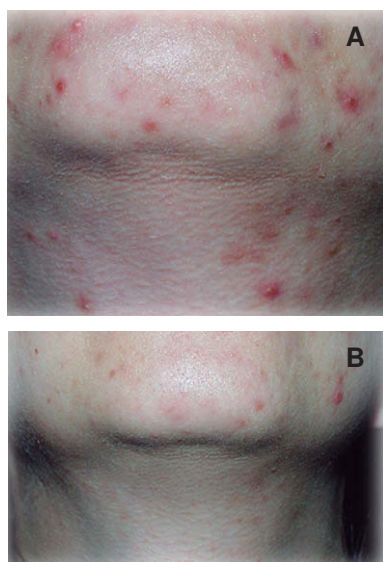


Figure 3. A. Patient with inflammatory lesions on the central part of the chin. B. Decrease after 12 weeks of treatment.

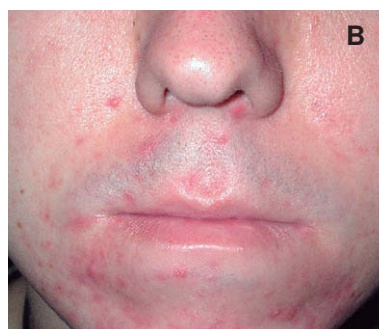
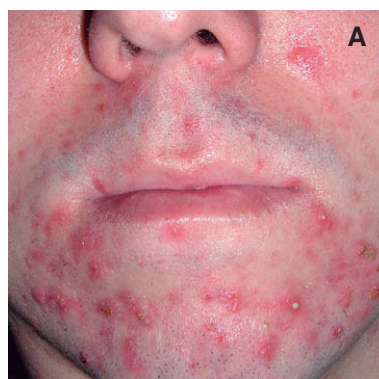
Figure 4. A. Patient with multiple pustules, papules, and scabs. B. Healing at the end of 12 weeks of phototherapy.

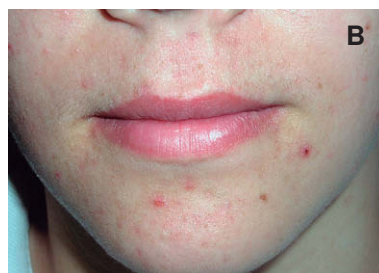
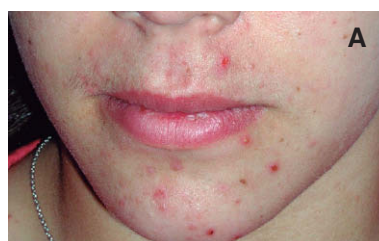
Figure 5. A. Patient with excoriated lesions and isolated pustules. B. Improvement after 12 weeks of laser therapy.

Discussion

Phototherapy can be used alone or as adjuvant therapy in the treatment of acne because it blocks the pathogenic process via photochemical, thermal, and even photoimmunological mechanisms.⁴ Knowledge of the optical properties of the skin is essential. In particular, the idea of “optical penetration depth”—that is, how deeply the light penetrates before its intensity is attenuated by 37%—is important. At this level, the light intensity decays exponentially on propagation through the skin.

Currently, more than 20 different light sources are available for treating acne. The main potential targets are the infundibulum, the sebaceous glands, *P. acnes*, and the inflammatory response.

Generally, low-energy light sources are used, with sufficient light fluence to treat active acne while minimizing

discomfort and potential undesired effects for the patient. In studies with pulsed dye lasers, intense pulsed light, and potassium–titanyl–phosphate lasers with low energy fluence, it has been possible to achieve these goals.

Photoimmunological blockade of acne progression was observed recently in studies done in vivo showing that laser light induced the release of anti-inflammatory molecules.

P. acnes is one of the therapeutic targets in the treatment of acne. These gram-positive anaerobic bacilli induce the production of proinflammatory mediators (IL-1 α , TNF- α , and GM-CSF) in keratinocytes. They also have a

Table 1. Nonparametric Statistical Test: Wilcoxon Signed Rank Test ($P < .001$)^a

Activity		Baseline	4 Weeks	8 Weeks	12 Weeks
Noninflammatory skin lesions	Mean	42.50	35.80	32.97	30.23
	Median	27.50	20.00	15.00	10.00
	Minimum	8	6	5	2
	Maximum	250	230	240	210
	25th percentile	15.00	12.00	10.00	6.00
	75th percentile	51.75	31.25	30.00	27.25
Inflammatory skin lesions	Mean	49.17	32.70	25.03	20.97
	Median	50.00	30.00	20.00	11.00
	Minimum	10	7	4	2
	Maximum	120	125	150	160
	25th percentile	28.75	18.00	10.00	7.00
	75th percentile	62.00	36.25	25.00	20.00

^aData are shown as the number of lesions per patient.

mitogenic effect on T cells, which are activated and release cytokines, thereby altering the inflammatory process and stimulating the comedo formation associated with acne.

These bacteria synthesize endogenous porphyrins (coproporphyrin III, protoporphyrin, and uroporphyrin), which can be photoactivated by different light sources via a photodynamic reaction to induce production of singlet oxygen and free radicals. These agents damage the lipids of the cell wall of *P acnes*, leading to destruction of the bacterium.¹⁻³

The porphyrins have 2 main absorption bands: the Soret band (400-420 nm), where the porphyrins absorb intensely—with a peak absorption at 415 nm—and Q bands (450-700 nm), where absorption is weak.^{3,5,6}

The wavelength is one of the most important considerations when choosing a light source for acne treatment. Blue light (415 nm) is the most effective visible wavelength, but this light does not penetrate the skin very deeply. Red light (660 nm) is able to penetrate further but porphyrin has a low excitation coefficient at this wavelength. Nevertheless, red light has anti-inflammatory properties because it induces macrophages to release cytokines.⁶

Photoinactivation of *P acnes* is directly dependent on the concentration of porphyrins. Administration of exogenous porphyrins such as aminolevulinic acid leads to protoporphyrin IX production via the heme pathway in the pilosebaceous unit, and in this way enhances photoinactivation of *P acnes*. In addition, exogenous administration of porphyrins leads to greater production of endogenous porphyrins by *P acnes* and, as a result, the concentration of protoporphyrin IX is higher.⁷ Porphyrin accumulates to a greater extent in sebaceous glands than in

hair follicles. Irradiation at an optimum wavelength leads to the destruction of sebaceous glands and damage to hair follicles and the epidermis. As a result, there are fewer pilosebaceous units, but their structure remains intact.⁷

Many studies on the use of noncoherent light sources for the treatment of acne can be found in the scientific literature. Compliance with therapy is higher for red light sources than for blue ones. Unlike noncoherent light sources, lasers allow energy to be focused on the areas where it is really needed, with minimal energy dissipation.

Midinfrared lasers, whose chromophore is water, have been used for treating acne at 3 wavelengths, namely, 1320, 1450, and 1540 nm. Ross et al⁸ used a 1450 nm laser in patients with acne on their backs. The number of inflammatory lesions 12 weeks after finishing treatment decreased, but the improvement did not last long. In more recent studies in patients with facial acne, decreases of 75% in the number of active lesions were achieved 6 weeks after finishing treatment. This laser seems to act by directly heating the infundibulum to facilitate sebum excretion and so reduce keratinization of the follicles. In a study of 18 patients with active acne, a decrease of 83% in the number of lesions after 3 sessions of treatment with limited adverse reactions was reported by Friedman et al.⁹

A laser operating at 1540 nm was used by Boineau et al¹⁰ in a study involving 4 treatment sessions. A decrease of 78% was found in the number of lesions 12 weeks after finishing treatment and the patients reported that their skin felt less greasy.

Potassium-titanyl-phosphate laser light has also been used in rosacea and acne. This source acts by heating pigment and hemoglobin and by photodynamic reaction. Lee et al

treated 25 patients with multiple passes at a fluence of 6 to 21 J/cm². Active acne was eliminated in 60% to 70% of the patients after 6 treatment sessions, but recurrences were reported more often and more quickly than with other light sources.

With pulsed dye laser light, it is possible to target the inflammatory component of acne by using hemoglobin as a chromophore. Use of this type of laser also seems to induce release of anti-inflammatory molecules, since, among other factors, the emission of low-energy laser light stimulates cells and T cells in particular.¹¹ This laser source seems not only to eliminate bacteria directly but also through stimulation of the immune system. On the other hand, the low fluence also induces the production of procollagen secondary to heating of the perivascular dermis, a process that may help reduce scarring associated with acne.^{7,12} This source also appears to reduce comedo formation and maturation of the follicular wall. Moreover, few adverse reactions have been associated with use of pulsed dye laser light.

Seaton et al,¹³ with laser light at 585 nm and a fluence of 1.5 to 3 J/cm², achieved a reduction of 53% in the active acne lesion count in 41 patients.

The most recent studies of the molecular mechanisms implicated in treating acne with laser light have reported an increase in the levels of transforming growth factor β 1 (TGF- β 1) 24 hours after application of pulsed dye laser light at 585 nm (with a NliteV laser). TGF- β 1 is known to be a potent inducer of collagen synthesis and plays a central role in initiating wound healing. It is also an essential immunosuppressive cytokine that promotes the termination of inflammatory processes. In addition, it is the most potent known inhibitor of keratinocyte proliferation.¹⁴

Conclusions

Phototherapy is an appropriate alternative for treating acne patients who have not responded to previous treatments or in whom systemic treatment is contraindicated.

The use of coherent light sources allows the energy to be focussed where it is required, with minimal adverse reactions. Using a pulsed dye laser as a light source should induce photoinactivation of *P acnes* through porphyrin activation. This light source also reduces the inflammatory component of acne, stimulates the immune response, and flattens the acne scars.

In this study, the acne of our patients showed a clinical improvement, with a reduction in both the noninflammatory and inflammatory components of the 30 patients treated, although the biggest improvements were seen for inflammatory lesions. The subjective degree of satisfaction was almost 85% for the patient group. The treatment was well tolerated and few adverse reactions were reported.

Conflicts of Interest

The authors declare no conflicts of interest.

References

1. Parrar M, Ingham E. Acne: Inflammation. *Clin Dermatol.* 2004;22:380-4.
2. Bojard R, Holland K. Acne and Propionibacterium acnes. *Clin Dermatol.* 2004;22:375-9.
3. Bhardwaj S, Rohrer T, Arndt K. Lasers and light therapy for acne vulgaris. *Semin Cutan Med Surg.* 2005;24:107-12.
4. Ross V. Optical treatments for acne. *Dermatol Ther.* 2005; 18:253-66.
5. Mariwalla K, Rohrer T. Use of lasers and light-based therapies for treatment of acne vulgaris. *Lasers Surg Med.* 2005; 37:333-42.
6. Elman M, Lebzelter J. Light therapy in the treatment of acne vulgaris. *Dermatol Surg.* 2004;30:139-46.
7. Charakida A, Seaton E, Charakida M. Phototherapy in the treatment of acne vulgaris. What is its role? *Am J Clin Dermatol.* 2004;5:211-6.
8. Ross E, Blair M, Saleh B. Laser treatment of acne through selective dermal heating. *Lasers Surg Med.* 2002;14 Suppl:23.
9. Friedman P, Jih M, Kimyai-Asadi A. Treatment of inflammatory facial acne vulgaris with the 1450-nm diode laser: a pilot study. *Dermatol Surg.* 2004;30:147-51.
10. Boineau D, Angel S, Auffret N. Treatment of active acne with an erbium glass (1.54 micron) laser. *Lasers Surg Med.* 2004;16 Suppl:55.
11. Wiegell S, Wulf H. Photodynamic therapy of acne vulgaris using 5-aminolevulinic acid versus methyl aminolevulinate. *J Am Acad Dermatol.* 2006;54:647-51.
12. Ortiz A, van Vliet M, lask G. A review of lasers and light sources in the treatment of acne vulgaris. *J Cosmet Laser Ther.* 2005;7:69-75.
13. Seaton ED, Charakida A, Mouser PE. Pulsed-dye laser treatment for inflammatory acne vulgaris: randomised controlled trial. *Lancet.* 2003;362:1347-52.
14. Seaton ED, Mouser PE, Charakida A. Investigation of the mechanism of action of nonablative pulsed-dye laser therapy in photorejuvenation and inflammatory acne vulgaris. *Br J Dermatol.* 2006;155:748-55.