

## CASE REPORTS

# Primary Cutaneous Aspergillosis in a Leukemic Child

A Torrelo,<sup>a</sup> A Hernández-Martín,<sup>a</sup> C Scaglione,<sup>b</sup> L Madero,<sup>b</sup> I Colmenero,<sup>c</sup> and A Zambrano<sup>a</sup>

Departments of <sup>a</sup>Dermatología, <sup>b</sup>Oncología, and <sup>c</sup>Anatomía Patológica, Hospital del Niño Jesús, Madrid, Spain

**Abstract.** Primary cutaneous aspergillosis is a rare cutaneous disease that usually affects immunodepressed patients of any age. The most common associated disorders in children are leukemias and lymphomas although it can also occur in neonates and preterms due to their intrinsic immunological immaturity. We report the case of a 4-year-old boy diagnosed of acute lymphoblastic leukemia that, during chemotherapy, developed an ulceronecrotic inflammatory cutaneous lesion in the venopuncture area of the left forearm, and whose microbiological culture was positive for *Aspergillus flavus*.

**Key words:** primary cutaneous aspergillosis, immunodepression, leukemia.

## ASPERGILOSIS CUTÁNEA PRIMARIA EN UN NIÑO CON LEUCEMIA

**Resumen.** La aspergilosis cutánea primaria es una enfermedad cutánea infrecuente que suele presentarse en individuos inmunodeprimidos de cualquier edad. En los niños, las patologías asociadas con mayor frecuencia son las leucemias y los linfomas, aunque también puede ocurrir en neonatos y prematuros debido a su inmadurez inmunológica intrínseca. Presentamos el caso de un varón de 4 años diagnosticado de leucemia linfoblástica aguda que durante el tratamiento quimioterápico presentó una lesión cutánea inflamatoria ulceronecrotica en la zona de venopunción del antebrazo izquierdo, y cuyo cultivo microbiológico fue positivo para *Aspergillus flavus*.

**Palabras clave:** aspergilosis cutánea primaria, inmunodepresión, leucemia.

## Introduction

Fungi of the genus *Aspergillus* are ubiquitous and grow mainly in soil, water, and decomposing vegetation. They are opportunistic pathogens usually found in immunocompromised individuals, and are the second most common after *Candida*,<sup>1</sup> but occasionally they attack an immunocompetent host.<sup>2,3</sup> The most frequently involved microorganisms are *Aspergillus fumigatus* and *Aspergillus flavus*; other strains implicated in human aspergillosis are *Aspergillus niger*, *Aspergillus sydowi*, *Aspergillus terreus*, *Aspergillus ustus*, *Aspergillus versicolor*, *Aspergillus amstelodami*, *Aspergillus oryzae*, *Aspergillus restrictus*, and *Aspergillus chevalieri*.<sup>1</sup> We present a case of primary cutaneous aspergillosis without systemic involvement in an

immunosuppressed child who responded favorably to treatment with liposomal amphotericin B.

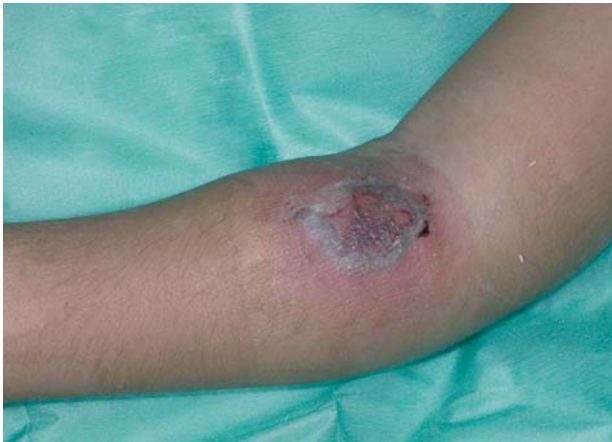## Case Description

The patient is a 4-year-old boy referred to us because of an indurated lesion on the left forearm. The patient had been diagnosed a month earlier with pre-B acute lymphoblastic leukemia from the findings of a medullogram showing 90% infiltration by CD34+, CD22+, CD20+, CD19+, and TdT- blasts. The patient started treatment with prednisone, but the response was poor. Subsequently he received vincristine and daunorubicin, to which he responded well, and the medullogram showed aplasia without blasts. The patient continued induction treatment with prednisone and cytostatic agents according to the Berlin-Frankfurt-Münster 2000 protocol for acute lymphoblastic leukemia until day 33.

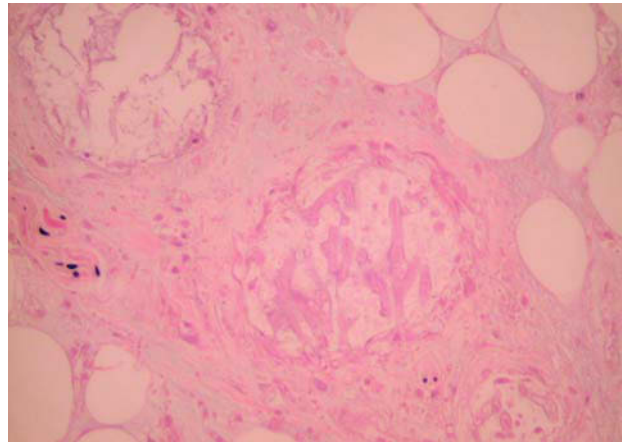
On day 30 the patient developed a lesion on the left forearm that consisted of a violaceous nodule 6 cm in diameter with necrotic bullae (Figure 1). This lesion was located in the venipuncture area for accessing peripheral veins. A cutaneous biopsy performed at the time showed

Correspondence:  
Antonio Torrelo  
Servicio de Dermatología  
Hospital del Niño Jesús  
Avda. Menéndez Pelayo, 65  
28009 Madrid, Spain  
atorrelo@aevd.es

Manuscript accepted for publication, September 15, 2006.



**Figure 1.** Ulcer with violaceous border and large blackish central scab.



**Figure 2.** Branching fungal hyphae with a tendency to vascular invasion. (Grocott methenamine silver stain,  $\times 100$ ).

an inflammatory and necrotic reaction in which abundant septate fungal hyphae were observed branching at sharp angles, with a tendency to invasion of the arterioles (Figure 2). *Aspergillus flavus* was detected growing in a culture of the lesion.

At that point, the blood counts showed 1000 leucocytes/mm<sup>3</sup> and 320 neutrophils/mm<sup>3</sup>. An x-ray of the thorax was considered to be normal. Abdominal and hepatic ultrasound showed no changes. Lumbar puncture was unremarkable. Computerized tomography of the cranium, paranasal sinuses, thorax, and abdomen revealed no abnormal findings. The echocardiogram was normal. Galactomannan levels and serology for *Aspergillus* were negative.

The patient was treated with liposomal amphotericin B (3.5 mg/kg/day). After a few days, the nodule had developed a large central necrotic scab that was surgically debrided. The histological study of the scab showed numerous fungal fibers branching at sharp angles.

The patient improved markedly coinciding with an increase in the number of neutrophils up to 1100/mm<sup>3</sup>. Complete healing of the resulting ulcer was achieved. At present the patient is in complete remission, and is undergoing the second consolidation cycle prior to a bone marrow transplant while receiving prophylactic treatment with voriconazole (200 mg/day).

## Discussion

Cutaneous aspergillosis may occur as either a primary or secondary infection. The former requires direct inoculation of the fungus into the skin, generally associated with a lesion or local injury. Secondary cutaneous aspergillosis develops through hematogenous dissemination to the skin from a distant focus. It is estimated that between 4% and 11% of patients with systemic aspergillosis develop secondary

involvement of the skin.<sup>4,5</sup> There is a third pathway of infection by which *Aspergillus* reaches the skin or mucosa from an adjacent cavity, such as the paranasal or maxillary sinuses; this form is known as contiguous spread aspergillosis.<sup>1</sup> In general, 0.27% of leukemia patients develop cutaneous aspergillosis in some form.<sup>4</sup>

Primary cutaneous aspergillosis (PCA) is a rare form of presentation. Its incidence is not known, and although around 50 cases may be found in the literature, it is probable that there are many more that have not been reported. *Aspergillus* infection is associated with prolonged neutropenia, immunosuppressive therapy and corticosteroids, broad-spectrum antibiotics, and underlying malignancy, especially hematologic. It has also been described in children with AIDS, premature infants, and patients with intravenous catheters.<sup>4-9</sup> Nosocomial infection usually originates in areas close to hospital construction or renovation projects, the hospital's ventilation system, or contaminated packages of gauze or catheters.<sup>10,11</sup>

In children, PCA may be observed in 3 situations. The most common of these is its appearance in immunosuppressed children.<sup>8</sup> The lesions usually develop at the site of catheterization or at points of contact with dressings or gauze. The microorganisms most often involved are *A flavus* and *A fumigatus*.<sup>6</sup> The most usual situation is the presence of leukemia or lymphoma, although there may be other underlying forms of immunosuppression. PCA may also affect newborns and premature infants, in whom it is believed that the immature immune system of the preterm infant, along with defective skin barrier function, are predisposing factors.<sup>11</sup> The most common type is *A fumigatus*, followed by *A flavus*. Finally, PCA may occur in immunocompetent children. This is a rare situation associated with trauma or catheter insertion.<sup>2,3</sup> In cases of PCA in immunocompetent individuals, the most common microorganism is *A terreus*, followed by *A fumigatus*.

The diagnosis is confirmed by histopathology, which shows the presence of septate fungal hyphae branching at sharp angles. However, given that the features of *Fusarium* and *Pseudoallescheria* are very similar to those of *Aspergillus*, it is necessary to culture the cutaneous lesion.<sup>7</sup> The presence of aspergillosis in other organs should be ruled out by chest radiograph, lumbar puncture, cranial computed tomography scan, echocardiography, abdominal ultrasound, and a fundus examination of the eyes.<sup>11,12</sup> These tests and examinations are fundamental in order to differentiate between PCA and secondary cutaneous aspergillosis which has spread from an occult focus. The angioinvasive tendency of *Aspergillus* may also lead to systemic hematogenous dissemination originating in PCA.<sup>4,8</sup>

The prognosis of PCA depends on the state of the patient's immune system, the neutrophil count, and early diagnosis and treatment. Recovery from neutropenia is a crucial factor determining response to treatment.<sup>13,14</sup> Disseminated aspergillosis may be fatal in 40% of affected children.<sup>8</sup> Treatment includes debridement of the cutaneous lesions and systemic treatment with amphotericin B or liposomal amphotericin B, alone or in conjunction with itraconazole.<sup>4</sup> The new antifungal agent voriconazole is highly active against different strains of *Aspergillus*,<sup>15</sup> and has even been effective in cases of aspergillosis in which amphotericin B had failed to produce results.<sup>16</sup> The combination of voriconazole and caspofungin may be even more effective than amphotericin B.<sup>17</sup> When using voriconazole, the possibility of photosensitization should be taken into account, especially during the months of more intense sunlight.<sup>18</sup>

#### Conflict of interest

We declare that we have no conflicts of interest.

## References

- Galimberti R, Kowalczyk A, Hidalgo Parra I, González Ramos M, Flores V. Cutaneous aspergillosis: a report of six cases. *Br J Dermatol*. 1998;139:522-6.
- Mowad CM, Nguyen TV, Jaworsky C, Honig PJ. Primary cutaneous aspergillosis in an immunocompetent child. *J Am Acad Dermatol*. 1995;33:136-7.
- Ajith C, Dogra S, Radotra B, Chakrabarti A, Kumar B. Primary cutaneous aspergillosis in an immunocompetent individual. *J Eur Acad Dermatol Venereol*. 2006;20:738-9.
- D'Antonio D, Pagano L, Girmenia C, Parruti G, Mele L, Candoni A, et al. Cutaneous aspergillosis in patients with haematological malignancies. *Eur J Clin Microbiol Infect Dis*. 2000;19:362-5.
- Romero LS, Hunt SJ. Hickman catheter-associated primary cutaneous aspergillosis in a patient with the acquired immunodeficiency syndrome. *Int J Dermatol*. 1995;34:551-3.
- Gerson SL, Talbot GH, Hurwitz S, Strom BL, Lusk EJ, Cassileth PA. Prolonged granulocytopenia: the major risk factor for invasive pulmonary aspergillosis in patients with acute leukemia. *Ann Intern Med*. 1984;100:345-51.
- Murakawa GJ, Harvell JD, Lubitz P, Schnoll S, Lee S, Berger T. Cutaneous aspergillosis and acquired immunodeficiency syndrome. *Arch Dermatol*. 2000;136:365-9.
- Grossman ME, Fithian EC, Behrens C, Bissinger J, Fracaro M, Neu HC. Primary cutaneous aspergillosis in six leukemic children. *J Am Acad Dermatol*. 1985;12:313-8.
- Richards KA, Mancini AJ. A painful erythematous forearm nodule in a girl with Hodgkin disease. Diagnosis: primary cutaneous aspergillosis. *Arch Dermatol*. 2000;136:1165-70.
- Roth JG, Troy JL, Esterly NB. Multiple cutaneous ulcers in a premature neonate. *Pediatr Dermatol*. 1991;8:253-5.
- Woodruff CA, Hebert AA. Neonatal primary cutaneous aspergillosis: case report and review of the literature. *Pediatr Dermatol*. 2002;19:439-44.
- Rowen JL, Correa AG, Sokol DM, Hawkins HK, Levy ML, Edwards MS. Invasive aspergillosis in neonates: report of five cases and literature review. *Pediatr Infect Dis J*. 1992;11:576-82.
- Hunt SJ, Nagi C, Gross KG, Wong DS, Mathews WC. Primary cutaneous aspergillosis near central venous catheters in patients with the acquired immunodeficiency syndrome. *Arch Dermatol*. 1992;128:1229-32.
- Aoun M, Van der Auwera P, Gerain J, Klasterky J. Aspergillosis in the immunocompromised: focus on treatment. *Recent Results Cancer Res*. 1993;132:127-36.
- García-Martos P, García-Agudo L, Gutiérrez-Calzada J, Ruiz-Aragón J, Saldarriaga A, Marín P. Actividad *in vitro* de anfotericina B, itraconazol y voriconazol frente a 20 especies de *Aspergillus* empleando el método de microdilución Sensititre. *Enferm Infecc Microbiol Clin*. 2005;23:15-8.
- Wieland T, Liebold A, Jagiello M, Retzl G, Birnbaum DE. Superiority of voriconazole over amphotericin B in the treatment of invasive aspergillosis after heart transplantation. *J Heart Lung Transplant*. 2005;24:102-4.
- Schuster F, Moelter C, Schmid I, Graubner UB, Kammer B, Belohradsky BH, et al. Successful antifungal combination therapy with voriconazole and caspofungin. *Pediatr Blood Cancer*. 2005;44:682-5.
- Auffret N, Janssen F, Chevalier P, Guillemain R, Amrein C, Le Beller C. Voriconazole photosensitivity: 7 cases. *Ann Dermatol Venereol*. 2006;133:330-2.