

LETTERS TO THE EDITOR

Multiple Terminal Hair Cysts in Perianal Region

L Pérez-Pérez, J Álvarez, MM Pereiro-Ferreirós, C Peteiro, and J Toribio

Servicio de Dermatología, Complejo Hospitalario Universitario, Facultad de Medicina, Santiago de Compostela, La Coruña, Spain

To the Editor:

In 1982 Mehregan and Medenica¹ described a rare variant of infundibular cyst they called a “pigmented follicular cyst,” characterized histopathologically by a wall with epidermoid keratinization and numerous thick, internally pigmented hair shafts. In 1990 Ribera et al² described the multiple variant of this type of cyst. The solitary variant has been reported in a few cases,³ but the multiple variant is rare.^{4,5}

We describe a 63-year-old man with no relevant history who consulted for asymptomatic perianal lesions from 1 year earlier. The number and size of the lesions had remained stable since onset. No topical treatments had been applied, and no rubbing or trauma had occurred in the area. The perianal region presented several yellowish, raised, circumscribed lesions of 1 to 3 mm in diameter with a smooth surface (Figure 1). A histopathological study of the lesions showed a cystic cavity located in the mid-dermis, connected to the epidermis by a pore, the wall of which was composed of keratinized stratified squamous epithelium that formed a granular layer. The cyst lumen showed orthokeratotic, laminar, amorphous, basophilic keratin and various hair shafts cut obliquely and cross-sectionally, with melanin granules and eosinophilic medulla (Figure 2). No skin appendages were observed in relation to the cyst wall. Based on the histological findings, the patient was diagnosed with “multiple terminal hair follicle cysts.” Although the entity we describe is of interest because of its infrequent occurrence, it is also remarkable in that the lesions lack pigmentation, are numerous, and have an atypical location.

Cutaneous cysts are classified according to the type of epithelium that lines the

cyst wall, the type of keratinization, the presence of vellus or terminal hair shafts, and the relationship with adjacent skin appendages.⁶

The most common cutaneous cysts are those originating in the pilosebaceous unit, with infundibular or epidermoid cysts and trichilemmal cysts being the most common.

Hair shafts inside cutaneous cystic lesions are a rare finding, and terminal hair shafts in infundibular cysts are rarer still.⁷ Hair shafts can be observed in dermoid cysts, hybrid cysts,⁷ steatocystomas/eruptive vellus cysts,⁸ comedones, and pigmented follicular cysts.

Terminal hair cysts are more common in men and present as single grayish, brown, blackish, or bluish lesions measuring 0.4 to 1.5 cm.^{1,9} These cysts are located on the head and neck and less often, on the axillae, abdomen, pubis, vulva, and legs.^{1,5} Histopathologically, they are characterized by the presence of terminal hair shafts and epidermoid keratinization.

Other cutaneous cysts, such as eruptive vellus cysts, hybrid cysts, apocrine hidrocystoma, and “pigmented epidermal cysts,” can also present clinical hyperpigmentation.

Terminal hair cysts are probably underdiagnosed or, on occasions, confused with other cutaneous lesions with a similar clinical appearance (nevocellular nevi, hidrocystomas, histiocytomas, granulomas, epithelial cysts, blue nevi, etc).

We believe that cutaneous cystic lesions represent a dynamic clinical and histopathological continuum and that terminal hair cysts should be considered as a separate entity within that continuum for the time being. Cutaneous cysts should not be classified

as static entities, because the increasingly numerous descriptions of hybrid cysts^{7,10} have merely shown that overlapping histological findings for the various types of cutaneous cystic lesions are far from unusual.

References

1. Mehregan AH, Medenica M. Pigmented follicular cysts. *J Cutan Pathol.* 1982;9:423-7.
2. Ribera M, Ferrándiz C, Andreu J, Lorenzo JC. Multiple pigmented terminal hair cysts. *J Am Acad Dermatol.* 1990;23:1183.

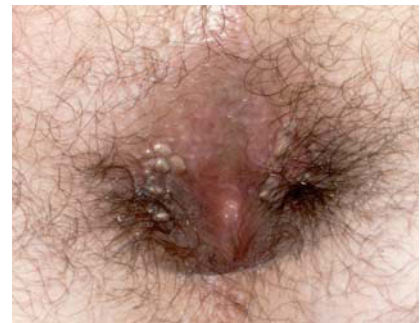

Figure 1. Visual appearance of the perianal lesions.

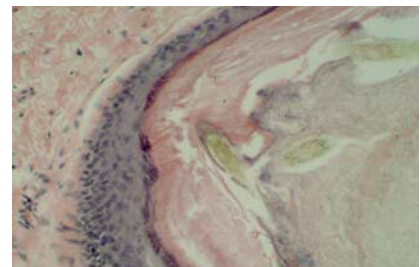


Figure 2. Cyst wall with epidermoid keratinization; the interior shows various pigmented terminal hair shafts (hematoxylin-eosin, ×250).

3. Del Río E, Vázquez Veiga H, Martín de Hijas C, Sánchez Yus E, Requena L. Quiste follicular pigmentado. *Actas Dermosifiliogr.* 1993;84:485-7.
4. Erkek E, Bozdogan Ö. Pigmented terminal hair cysts within an intradermal melanocytic naevus. *J EADV.* 2003;17:94-6.
5. Chuang YH, Hong HS, Kuo TT. Multiple pigmented follicular cysts of the vulva successfully treated with CO₂ laser: case report and literature review. *Dermatol Surg.* 2004;30:1261-4.
6. Sánchez-Yus E. Quistes cutáneos. Concepto, terminología y clasificación. *Monogr Dermatol.* 1993;6:85-8.
7. Requena L, Sánchez Yus E. Follicular hybrid cysts. An expanded spectrum. *Am J Dermatopathol.* 1991;13:228-33.
8. García Hernández MJ, Moreno-Giménez JC, Sánchez-Yus E, Camacho F. Esteatocistoma múltiple con pelosvellosos. Un caso congénito limitado a las axilas. *Actas Dermosifiliogr.* 1997;88:289-91.
9. Requena Caballero L, Sánchez Yus E. Pigmented follicular cyst. *J Am Acad Dermatol.* 1989;21:1073-5.
10. Takeda H, Miura A, Katagata Y, Mitsuhashi Y, Kondo S. Irbid cyst: case report and review of 15 cases in Japan. *J EADV.* 2003;17:83-6.

Leser-Trélat Sign Associated with Sézary Syndrome and Transitional Cell Carcinoma of the Bladder

C Martínez-Morán, C Sanz-Muñoz, and A Miranda-Romero

Servicio de Dermatología, Facultad de Medicina, Hospital Clínico Universitario de Valladolid, Valladolid, Spain

To the Editor:

Leser-Trélat sign is characterized by the sudden onset and rapid growth in number and size of multiple seborrheic keratoses, in relation to an underlying neoplasm.^{1,2} It is sometimes accompanied by pruritus and often associated with acanthosis nigricans.³

We describe a 63-year-old man diagnosed with plaque-stage mycosis fungoides who, during phototherapy, developed severe erythema and generalized skin thickening (Figure 1) accompanied by severe pruritus. Based on the skin biopsies, computed tomography scan, and bone marrow

aspirate culture, he was diagnosed with Sézary syndrome. At that time, more than 100 hyperpigmented, keratotic papules of 1 to 2 cm and soft to touch

were observed on the trunk (Figure 1), even though these papules had not been present 1 month earlier. A biopsy of 1 lesion on the trunk showed seborrheic keratosis. A parallel study by the urology department showed transitional cell carcinoma of the bladder. Chemotherapy and bladder instillations with bleomycin were started, with the seborrheic keratoses disappearing completely (Figure 2) within 2 months. Based on all this history, the patient was diagnosed with Leser-Trélat sign that could have been related to either or both neoplasms.

Because seborrheic keratoses and malignant tumors are 2 common diseases in elderly patients, some authors question the existence of this sign because they cannot rule out that coexistence of both is incidental. However, although seborrheic keratoses are a common condition in certain age groups, onset is not sudden.

Various hypotheses have been proposed for the pathogenesis of Leser-Trélat sign; all of them consider that the tumor might secrete a growth factor that stimulates the formation of these lesions^{1,4-6} and could explain the

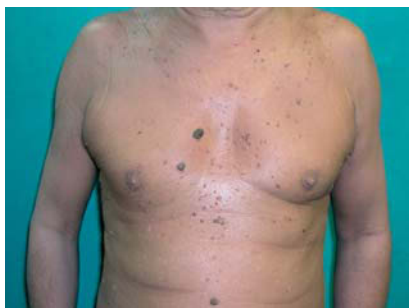

Figure 1. Numerous grayish papules on the thorax and abdomen with erythroderma and cutaneous thickening.

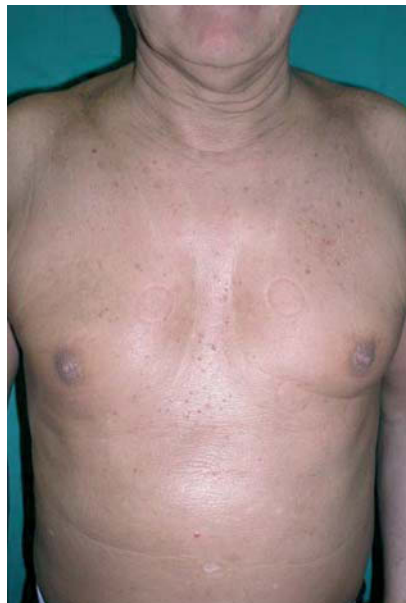

Figure 2. Patient's skin after treatment of both neoplasms. The erythema and cutaneous thickening seen in the previous images and seborrheic keratoses have disappeared.