




ACADEMIA ESPAÑOLA  
DE DERMATOLOGÍA  
Y VENEREOLÓGIA

# ACTAS Dermo-Sifiliográficas

Full English text available at  
[www.actasdermo.org](http://www.actasdermo.org)



## CASE AND RESEARCH LETTER

### Demodicosis in Bone Marrow Transplant Recipients: An Underdiagnosed Skin Disease

To the Editor,

*Demodex folliculorum* (DF) mites are inhabitants of the human pilosebaceous unit that have a predilection for the face due to high sebum concentration in this area. When cutaneous diseases are clinically characterized by a large number of DF mites we talk about demodicosis, which may be found more frequently in immunocompromised patients.<sup>1</sup> We present a case series of 4 patients with hematological diseases that developed demodicosis after receiving a bone marrow transplant (BMT).

Four patients from our hospital with leukemia developed a pruritic and acneiform rash after BMT and chemotherapy between 2021 and 2022. Table 1 illustrates their clinical information. All patients had a similar presentation (were under 30 and had a previous diagnosis of leukemia which required BMT and chemotherapy. None of them had any past medical history of acne, demodicosis, or rosacea. In all cases a pruritic micropustular rash was suddenly found on the face which progressed toward the neck and chest 7–19 days after BMT (Fig. 1). No associated systemic symptoms were reported. Dermoscopy of the pustular skin lesions revealed the presence of spikes, and a parasitological skin test performed by direct microscopic examination revealed the presence of a high DF density in all patients (Fig. 2a). Bacterial cultures and polymerase chain reaction (PCR) skin test for human herpes simplex 1 and 2 and varicella zoster virus tested negative in all 4 patients. In patient #3, demodicosis was also confirmed by histopathological examination, which revealed the presence of an inflammatory infiltrate around the hair follicles and the presence of an inflammatory lesion formed by giant cells and granulomas surrounding an infundibulum (Fig. 2b–d). Patients were received topical ivermectin showing complete remission of the lesions 2 weeks into treatment. No new flares of skin lesions have been detected at the 6-month follow-up.

DF is a saprophytic mite of the human pilosebaceous unit, first described in 1841 by Henle and Berger. It is commonly found on the face, especially the forehead, cheeks, eyelids, nasolabial folds, and nose due to the high density of sebaceous glands found in these areas. Rates of coloniza-

tion in the general population usually range from 20% up to 80%. DF may be also found in the ear canals and other areas of the body and has been involved in many dermatological disorders, such as rosacea, pustular folliculitis, or follicular pityriasis.<sup>2</sup>

The presence of follicular spines caused by the protrusion of mites and keratin from the follicle is referred to as pityriasis folliculorum. When demodicosis occurs and large quantities of mites are present in the epithelium of the skin, pruriginous follicular papules and visible inflammatory lesions may occur. Clinical presentation can vary from scales and erythema over the forehead and nose to a symmetrical papulopustular eruption of malar distribution over existing diseased skin.<sup>3</sup>

Demodex proliferation can be impacted by multiple factors, such as hypothyroidism, pregnancy, diabetes, immunosuppressive therapies, *Staphylococcus epidermidis* infection, and genetic background. In immunocompromised patients, a pruritic exanthema on extended areas such as the trunk and upper extremities can be found. Moreover, the presence of pustules and a lack of improvement after topical corticosteroids should also be indicative of the presence of DF. A few cases of demodicosis in patients with lymphoma or leukemia have been reported in the literature, especially when patients are recovering from an allogenic bone marrow transplant.<sup>4</sup> Accurate diagnosis in these patients is critical as the clinical presentation of the disorder can be similar to acute graft-versus-host disease of the skin.

For diagnosis, the presence of *Demodex* mites can be confirmed through examination using light microscopy of skin scrapes or confocal laser scanning *in vivo* microscopy. Moreover, a skin biopsy can be indicative of the presence of demodicosis when follicular spongiosis and a perifollicular lymphoid infiltrate are found as was observed in our patients.

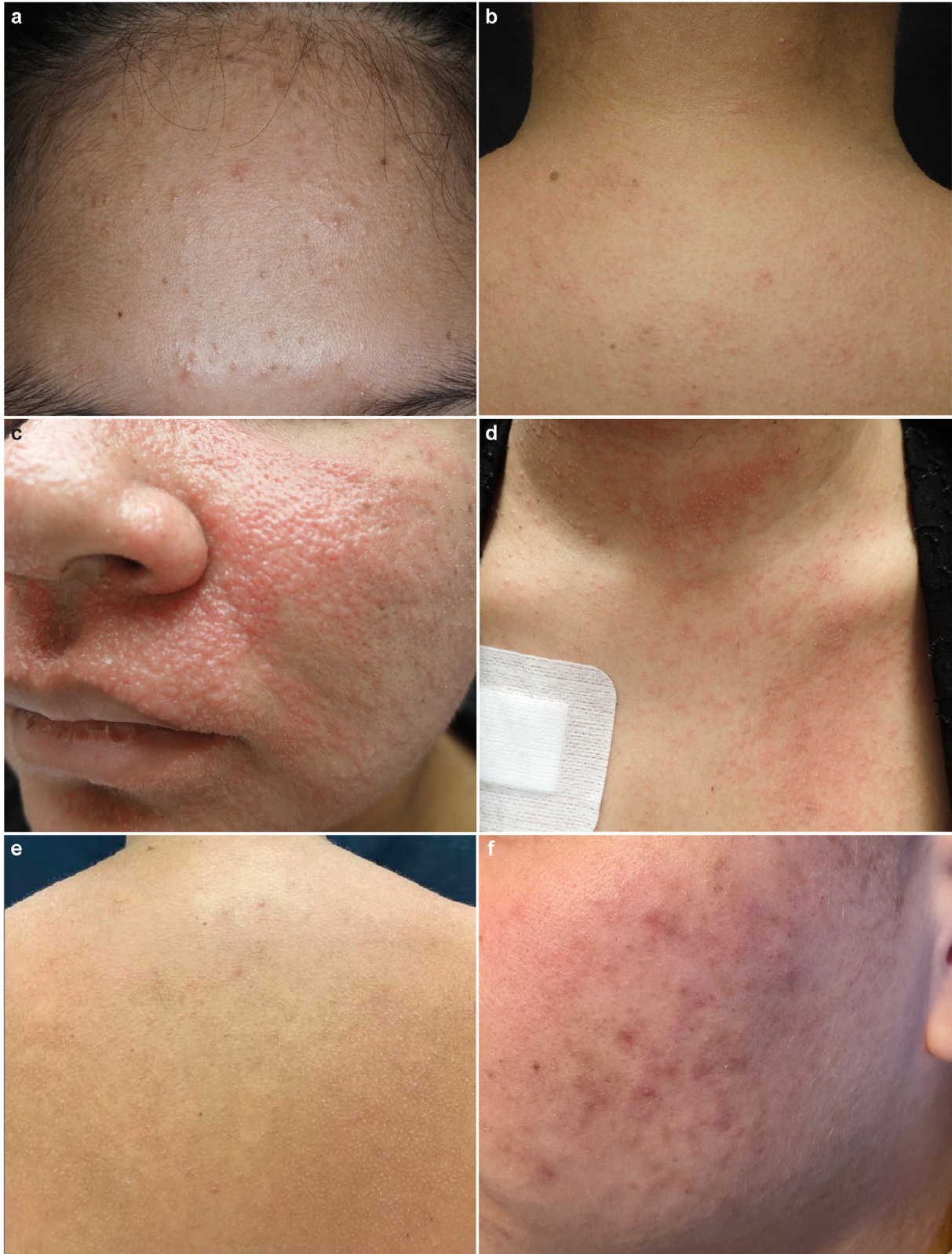Many treatment options, such as permethrin, oral ivermectin or metronidazole have demonstrated the efficacy profile of Demodex infestation. However, topical ivermectin seems to be beneficial in immunosuppressed patients with extended and symptomatic skin eruptions.<sup>5</sup>

Our patients developed a perioral eruption which extended to the rest of the face, arms, back and pre-sternal region. In addition to parasitological examination by pustular lesions scrapping, skin biopsy and detection of DF by direct microscopy allowed us to establish the correct diagnosis. Moreover, complete remission of the skin eruption was

<https://doi.org/10.1016/j.ad.2023.08.026>

0001-7310/© 2025 AEDV. Published by Elsevier España, S.L.U. This is an open access article under the CC BY-NC-ND license (<http://creativecommons.org/licenses/by-nc-nd/4.0/>).

Please cite this article as: I. Oteiza Rius, M.P. Gil Sánchez, N. Rodríguez Garijo et al., Demodicosis in Bone Marrow Transplant Recipients: An Underdiagnosed Skin Disease, ACTAS Dermo-Sifiliográficas, <https://doi.org/10.1016/j.ad.2023.08.026>

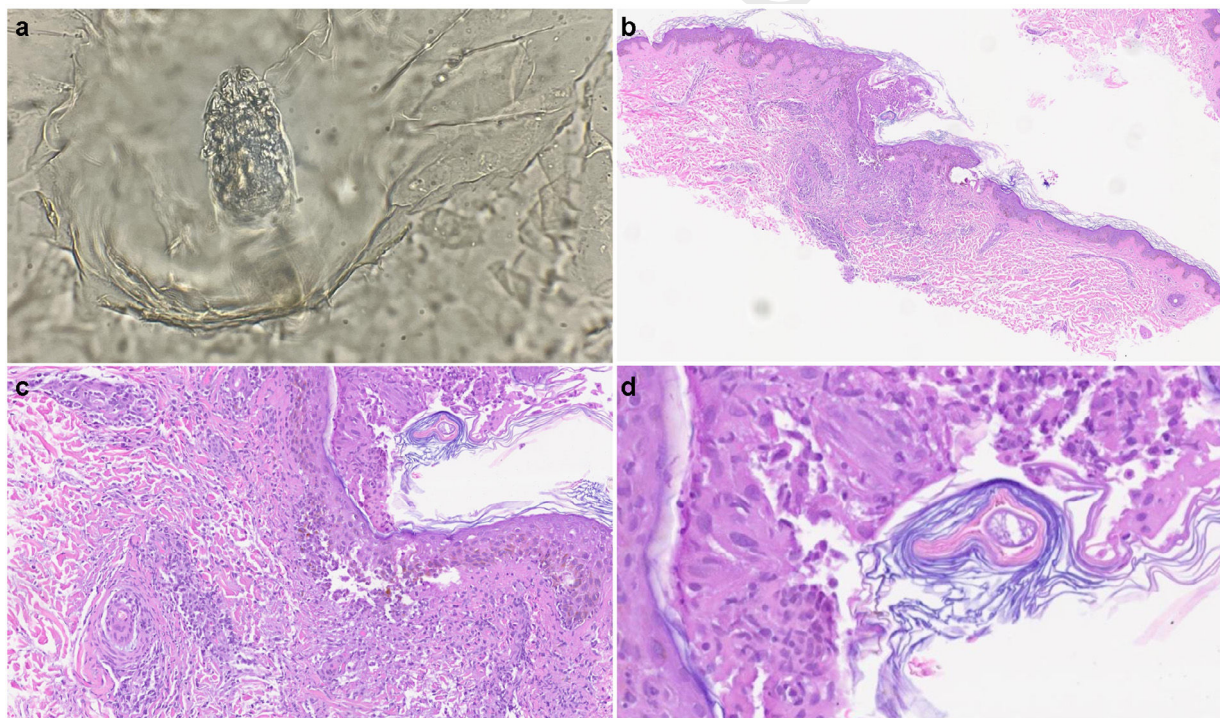


**Figure 1** Clinical presentation of demodicosis in patients #1 (a), #2 (b), #3 (c-e) and #4 (f). (a) Small pustular lesions over the forehead. (b) Maculopapular rash and pustules on the upper back. (c) Confluent maculopapular exanthema involving the perioral and malar regions. (d, e) Maculopapular rash and micropustules over chest and back. (f) Malar pustules and erythema.

**Table 1** Clinical characteristics of patients with demodicosis after receiving a bone marrow transplant (BMT).

Case	Sex/age (year)	Hematological condition	IT	Time from BMT to DM	Diagnostic test	Clinical presentation	Localization
1	Female/19	ALL B	Tacrolimus	7 days	PT and DS	Micropustules and erythema	Face and chest
2	Female/20	ALL B	Prednisone	14 days	PT and DS	Erythema and micropustules	Nose, perioral region, chest, and upper back
3	Female/27	AML	Tacrolimus	19 days	PT, DS, and skin biopsy	Maculopapular exanthema	Face, chest, upper back, and arms
4	Male/22	ALL B	Tacrolimus	15 days	PT and DS	Micropustular exanthema	Face, arms, and chest

**Abbreviations:** ALL: acute lymphoblastic leukemia; AML: acute myeloblastic leukemia; BMT: bone marrow transplant; IT: immunosuppression therapy; DM: demodicosis; DS: dermoscopy; PT: parasitological test.



**Figure 2** Parasitological test and histopathological images of skin lesions. (a) Parasitological skin test showing DF. (b, c) At lower power, dermatopathology images show a pronounced *perifollicular lymphocytic infiltrate* around hair follicles (hematoxylin-eosin staining, original magnification (b)  $\times 40$  and (c)  $\times 100$ ). (d) High power image showing a tubular structure consistent with DF (hematoxylin-eosin staining, original magnification  $\times 400$ ).

seen after topical ivermectin, which reaffirmed our diagnosis. No side effects were reported after treatment in these patients.

In conclusion, physicians should remember that demodicosis should be taken into consideration when acute pustular and pruritic skin eruptions involving face and upper regions of the body appear after a bone marrow transplant. Of note, the transition from the asymptomatic colonization of DF to clinical demodicosis is a more common finding in immunosuppressed patients.<sup>3</sup> Therefore, an easy and useful technique as parasitological examination should be included in the study protocol of pustular lesions in this group of patients.

### Conflict of interests

The authors state that they have no conflict of interests.

### References

- Cotliar J, Frankfurt O. Demodex folliculitis mimicking acute graft vs host disease. *JAMA Dermatol.* 2013;149:1407–9, <http://dx.doi.org/10.1001/jamadermatol.2013.5891>.
- Elston C, Elston D. Demodex mites. *Clin Dermatol.* 2014;32:739–43, <http://dx.doi.org/10.1016/j.clindermatol.2014.02.012>.

- 114 3. Anwar Rather P, Hassan I. Human demodex mite: the ver-  
115 satile mite of dermatological importance. Indian J Dermatol.  
116 2014;51:60–6, <http://dx.doi.org/10.4103/0019-5154.123498>.  
117 4. Forton F, De Maertelaer V. Which factors influence  
118 Demodex proliferation? A retrospective pilot study high-  
119 lighting a possible role of subtle immune variations and  
120 sebaceous gland status. J Dermatol. 2021;48:1210–20,  
121 <http://dx.doi.org/10.1111/1346-8138.15910>.  
122 5. Kubanov A, Gallyamova Y, Kravchenko A. Clinical  
123 picture, diagnosis, and treatment of rosacea by com-  
124 plicated demodex mites. Dermatol Rep. 2019;11:12–8,  
125 <http://dx.doi.org/10.4081/dr.2019.7675>.

I. Oteiza Rius\*, M.P. Gil Sánchez, N. Rodríguez Garijo,  
A. Spain

Q2

*Departamento de Dermatología de la Clínica Universidad  
de Navarra, Navarre, Spain*

\*Corresponding author.

E-mail address: [ioteiza@unav.es](mailto:ioteiza@unav.es) (I. Oteiza Rius).

126

127

UNCORRECTED PROOF