




ACADEMIA ESPAÑOLA
DE DERMATOLOGÍA
Y VENEREOLOGÍA

ACTAS Dermo-Sifiliográficas

Full English text available at
www.actasdermo.org



CASE AND RESEARCH LETTER

Flow Cytometric Analysis of Skin Blister Fluid Cells: A Promising Tool in the Differential Diagnosis of Acute Cutaneous Graft-versus-host Disease and Stevens–Johnson Syndrome/Toxic Epidermal Necrolysis

Análisis por citometría de flujo de las células del líquido de las ampollas cutáneas: una herramienta prometedora para la diferenciación de la enfermedad del injerto contra el huésped aguda y el síndrome de Stevens-Johnson/necrólisis epidérmica tóxica

To the Editor,

Acute graft-versus-host disease (GvHD) is a life-threatening complication following allogeneic hematopoietic stem cell, or solid organ transplantation.¹ Discriminating grade IV cutaneous GvHD from Stevens–Johnson syndrome/toxic epidermal necrolysis (SJS/TEN) is challenging due to the similar clinical and histopathological features shared by both entities.² However, distinguishing between the two diagnoses is important because the management of these conditions is not the same.^{1,3}

We report the case of a 61-year-old woman with myelodysplastic syndrome with excess blasts type 2 who underwent allogeneic stem cell transplantation. One day prior to the transplant, GvHD prophylaxis was initiated with cyclosporine A. The patient received multiple drugs at admission, including antibiotics, such as beta-lactams, trimethoprim/sulfamethoxazole, and vancomycin. One month later, an extensive maculopapular rash with skin detachment and a positive Nikolsky's sign appeared on the trunk, scalp (including the retroauricular region), palms, and soles (Fig. 1). Additionally, oral, genital, and ocular mucous membranes were affected as well. There were no signs of GI or hepatic involvement. Clinical diagnosis of GvHD vs SJS/TEN was considered. The skin biopsy confirmed the presence of a completely necrotic epidermis detached from the dermis, which was consistent with both

diagnoses. The patient was, therefore, admitted to the ICU, suspected drugs were withdrawn, and treatment with prednisone (1 mg/kg/12 h) and immunoglobulin (1 mg/kg/day) was initiated. However, skin lesions fail to improve after 48 h.

Currently, there are no established biomarkers that can reliably diagnose GvHD. According to a pilot study, a composite biomarker panel including elafin, regenerating islet-derived 3- α , and soluble interleukin-2 receptor- α can be useful to differentiate acute GvHD from non-GvHD patients at onset with specificity and sensitivity rates of 100% and 55.6%, respectively.⁴ Nevertheless, these biomarkers are not widely available, which is why this analysis could not be conducted.

Flow cytometric analysis of skin blister fluid cells (BFC) was performed, and the results became available in <1 h. The CD8+/CD4+ ratio among the CD3+ T cells found in our analysis was 2.1, and natural killer (NK) cells (CD3-CD56+ lymphocytes) accounted for up to 65.5% of the entire lymphocyte population (Fig. 2). In our centre, this evaluation is always conducted in available BFC of SJS/TEN cases following the protocols established by the PIELenRed consortium, a Spanish interdisciplinary platform for the investigation of severe cutaneous adverse drug reactions.⁵ The mean CD8+/CD4+ ratio in 10 SJS/TEN samples analyzed was 5.5 (range, 2.3–12.4), and the mean percentage of NK cells, 11.5% (range, 3–18%). As far as we know, no studies have ever compared the amount of CD8+, CD4+ and NK cells in blister fluids of GvHD and SJS/TEN. Nevertheless, according to Naik et al., the CD8+/CD4+ ratio in the histopathological analysis of grade IV GvHD skin biopsies was lower vs SJS/TEN (1.78 vs 7.33).⁶ Furthermore, Wegner et al. reported an increased number of NK cells in GvHD skin samples vs SJS/TEN.⁷ Therefore, immunohistochemical studies in skin biopsies and flow cytometric analyses of blister fluid may have parallel results. In fact, the findings of our case support the diagnosis of GvHD.

Finally, taking the patient's past medical history, clinical signs, and flow cytometric data into consideration, the diagnosis of GvHD was considered more likely, and targeted treatment was initiated with ruxolitinib and photopheresis, with rapid improvement of skin lesions. Unfortunately, the patient developed infectious and haemorrhagic complications leading her death on day +57.

One of the most important reasons for performing flow cytometric analysis of BFC instead of just a conventional

<https://doi.org/10.1016/j.ad.2023.04.048>

0001-7310/© 2024 AEDV. Published by Elsevier España, S.L.U. This is an open access article under the CC BY-NC-ND license (<http://creativecommons.org/licenses/by-nc-nd/4.0/>).

Please cite this article as: R. de Moraes Souza, T. Bellón, E. Fiz Benito et al., Flow Cytometric Analysis of Skin Blister Fluid Cells: A Promising Tool in the Differential Diagnosis of Acute Cutaneous Graft-versus-host Disease and Stevens–Johnson Syndrome/Toxic Epidermal Necrolysis, ACTAS Dermo-Sifiliográficas, <https://doi.org/10.1016/j.ad.2023.04.048>

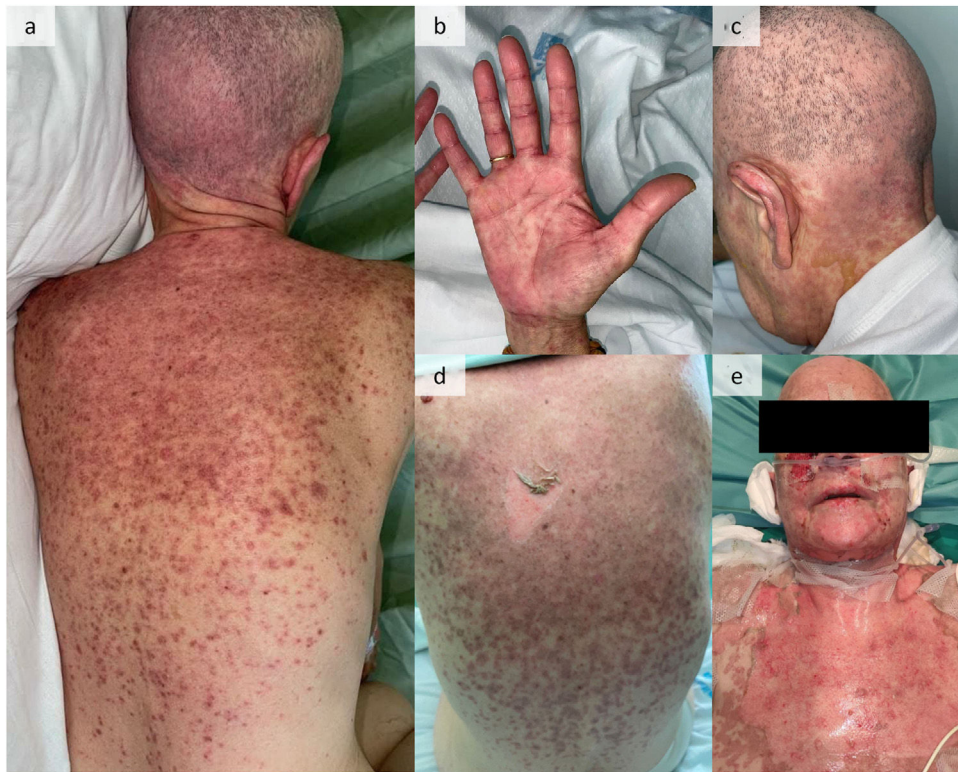

Figure 1 Clinical features. (a–c) Maculopapular rash with trunk, palmoplantar region, scalp, and retroauricular area involvement. (d) Positive Nikolsky’s sign. (e) Epidermal detachment.

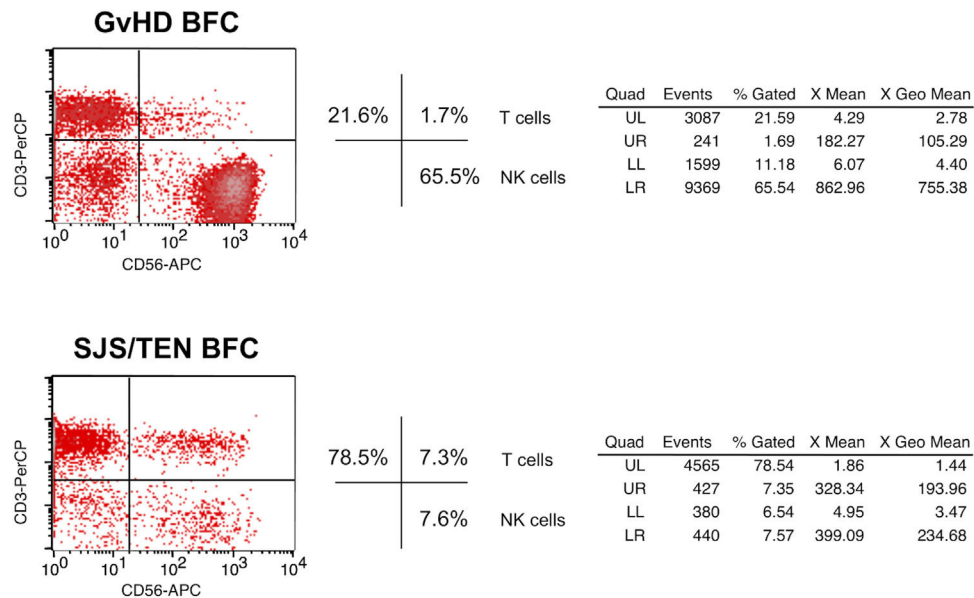


Figure 2 Dot plots representing the percentage of cell types found in the skin blister fluid by flow cytometric analysis. The LR square (CD3– CD56+) illustrates the NK cells. The first diagram shows our patient’s data, with 65.5% of NK cells. The diagram below is an example of an SJS/TEN case, with only 7.6% of NK cells. GvHD, graft-versus-host disease; BFC, blister fluid cells; SJS/TEN, Stevens–Johnson syndrome/toxic epidermal necrolysis; NK cells, natural killer cells; UL, upper-left; UR, upper-right; LL, lower-left; LR, lower-right.

biopsy is to help in the differential diagnosis of two entities whose histopathological findings often overlap, causing a diagnostic dilemma.^{2,6,7} In addition, we should emphasize that the results of this test can be obtained very quickly: in <1 h in our centre. This can be crucial for decision-making and to start treatment fast.

Although the flow cytometric analysis of BFC is not a currently validated technique, results can likely be parallel to those found in immunohistochemical studies. In the future, this test may be a fast and useful tool to differentiate grade IV GvHD from SJS/TEN, which warrants further investigation.

Funding

This study was supported by a grant from Instituto de Salud Carlos III, Madrid, Spain (Spanish Ministry of Economy and Competitiveness) FIS PI18/00718 (co-funded by FEDER) to TB.

Conflict of interest

The authors declare that they have no conflict of interest.

References

1. Strong Rodrigues K, Oliveira-Ribeiro C, de Abreu Fiuza Gomes S, Knobler R. Cutaneous graft-versus-host disease: diagnosis and treatment. *Am J Clin Dermatol*. 2018;19:33–50, <http://dx.doi.org/10.1007/s40257-017-0306-9> [PMID: 28656563; PMCID: PMC5797560].
2. Klein B, Kolm I, Nair G, Nägeli MC. Toxic epidermal necrolysis-like acute cutaneous graft-versus-host disease in a stem cell recipient – a diagnostic dilemma. *J Eur Acad DermatolVenereol*. 2021;35:e585–7, <http://dx.doi.org/10.1111/jdv.17310> [Epub 28.05.21; PMID: 33914967].
3. Krajewski A, Maciejewska-Markiewicz D, Jakubczyk K, et al. Impact of multiple medical interventions on mortality, length of hospital stay and reepithelialization time in

toxic epidermal necrolysis, Steven–Johnsons syndrome, and TEN/SJS overlap – metanalysis and metaregression of observational studies. *Burns*. 2022;48:263–80, <http://dx.doi.org/10.1016/j.burns.2021.11.004> [Epub 18.11.21; PMID: 34903405].

4. Min SS, Mehra V, Clay J, et al. Composite biomarker panel for prediction of severity and diagnosis of acute GVHD with T-cell-depleted allogeneic stem cell transplants-single center pilot study. *J Clin Pathol*. 2017;70:886–90, <http://dx.doi.org/10.1136/jclinpath-2017-204399> [Epub 27.04.17; PMID: 28450387].
5. PIELenRed: una plataforma para la investigación de las reacciones cutáneas. *Reacciones Adversas a Medicamentos*. 2014;21:1–4. Available from: <https://seguridadmedicamento.sanidadmadrid.org/RAM/vol-21/1-Vol21n2julio2014.pdf> [accessed 26.12.22].
6. Naik H, Lockwood S, Saavedra A. A pilot study comparing histological and immunophenotypic patterns in stage 4 skin graft vs host disease from toxic epidermal necrolysis. *J Cutan Pathol*. 2017;44:857–60, <http://dx.doi.org/10.1111/cup.12986> [Epub 19.07.17; PMID: 28626936].
7. Wegner J, Weidenthaler-Barth B, Engelbert J, et al. Immunohistochemical markers for histopathological diagnosis and differentiation of acute cutaneous graft-versus-host disease. *Exp Dermatol*. 2021;30:1814–9, <http://dx.doi.org/10.1111/exd.14416> [Epub 05.07.21; PMID: 34223669].

R. de Moraes Souza^{a,*}, T. Bellón^b,
E. Fiz Benito^a, E. Sendagorta Cudós^a

^a *Dermatology Division, La Paz University Hospital (Hospital Universitario La Paz), Paseo de la Castellana, 261, CP 28046, Madrid, Spain*

^b *Drug Hypersensitivity Group, Hospital La Paz Institute for Health Research (Instituto de Investigación Sanitaria del Hospital Universitario La Paz – IdiPAZ), Calle de Pedro Rico, 6, CP 28029, Madrid, Spain*

* Corresponding author.

E-mail address: rafa.msouza1@gmail.com
(R. de Moraes Souza).