

## PRACTICAL DERMOSCOPY

### Pink Nodule on the Hand of a 12-Year-old Patient

#### Un nódulo rosado en la mano de una paciente de 12 años

#### Case presentation

A 12-year-old female, with Fitzpatrick phototype II, presented to the Dermatology outpatient clinic with a 4-month history of an asymptomatic pink nodule on the dorsum of her left hand. A 0.8 cm × 0.8 cm well-demarcated, smooth, exophytic nodule measuring was observed (Fig. 1).

Dermoscopy of the lesion (Fig. 2)

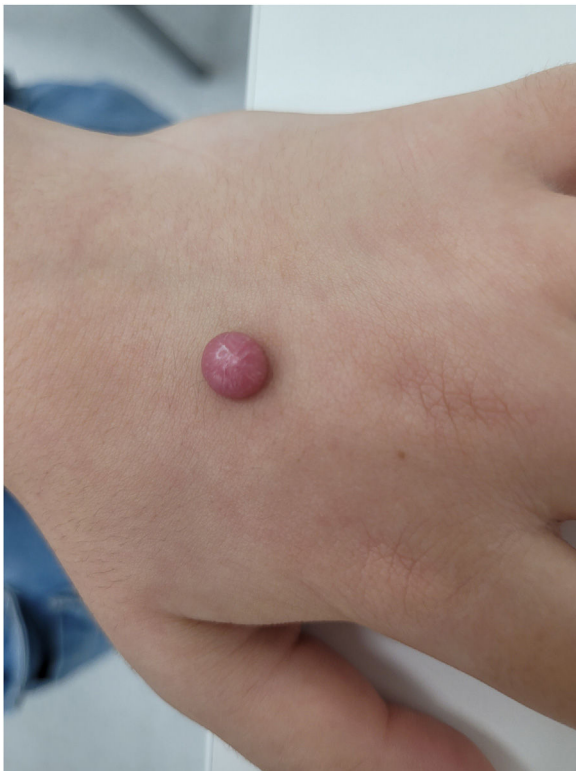

Figure 1 Solitary pink nodule on the dorsum of the left hand.

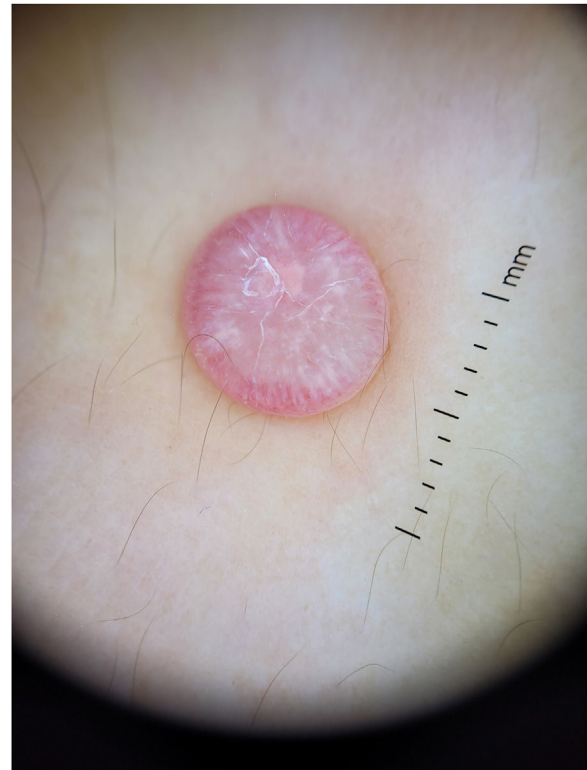


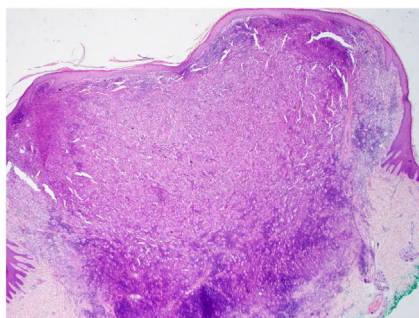
Figure 2 Contact polarized dermoscopic image of the lesion.

What is your diagnosis?

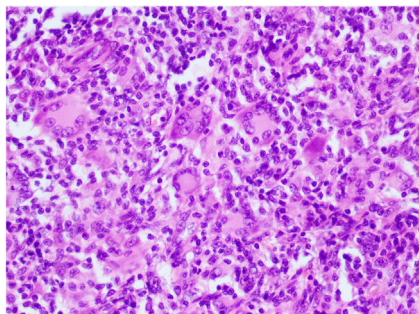
<https://doi.org/10.1016/j.ad.2024.02.032>

0001-7310/© 2024 AEDV. Published by Elsevier España, S.L.U. This is an open access article under the CC BY-NC-ND license (<http://creativecommons.org/licenses/by-nc-nd/4.0/>).

Please cite this article as: M. Valiuškytė, C. Gonçalves-Castro and A. Miroux-Catarino, Pink Nodule on the Hand of a 12-Year-old Patient, ACTAS Dermo-Sifiliográficas, <https://doi.org/10.1016/j.ad.2024.02.032>



**Figure 3** Large dermal nodule (hematoxylin–eosin, magnification 20×).



**Figure 4** The nodule is mainly composed of Touton-type multinucleated giant cells (hematoxylin–eosin, magnification 400×).

### Comment

The dermoscopy of the lesion revealed the presence of a “cloud” of a paler yellow area at the center, shiny white streaks radiating from the it, linear vessels in the periphery, hairpin vessels in the center, and a few scales. The lesion was excised under local anesthesia followed by the simple interrupted suture of the surgical wound. Differential diagnosis included Spitz nevus, solitary reticulohistiocytoma, dermatofibroma and juvenile xanthogranuloma (JXG). Histopathological examination revealed mainly the presence of Touton-type multinucleated giant cells, a few mononucleated histiocytes with large eosinophilic vacuolated cytoplasm, and abundant lymphoplasmacytic inflammatory infiltrate (Figs. 3 and 4). Immunohistochemistry was positive for CD68, S100, and negative for CD1a, Sox 10. These findings, along with clinical examination and dermoscopy, supported the diagnosis of JXG.

The most common form of non-Langerhans cell histiocytosis is JXG. Its clinical presentation are yellow, red, or brown papulonodular lesions, typically seen in individuals within the first two decades of life, often regressing spontaneously.<sup>1</sup> Dermoscopy proves to be valuable in distinguishing JXG from other skin lesions, considering its diverse clinical presentations across different stages of evolution.<sup>2,3</sup> Histopathologically the early stage of JXG is characterized by sheet-like proliferation of small monomorphous histiocytic cells. As it progresses to its developed stage-xanthomatized cells-Touton giant cells become more

prominent. During the transition stage, moderate fibrotic tissue reactions with an increased number of spindle-shaped cells are observed.<sup>2,3</sup> The typical dermoscopic “setting sun” pattern characterized by a yellowish background with subtle peripheral erythema is mostly seen during the early, developed stages of the disease. In the transition stage, “clouds” of paler yellow areas are more common, possibly representing the evolution of the yellow background in the “setting sun” appearance.<sup>2,3,5</sup> Due to dermal fibrosis at later stages, shiny white streaks or whitish areas with a stellate distribution may be observed.<sup>2,3</sup> In all stages of JXG, vascular findings are described, while linear vessels, which may radiate from the periphery to the center, are the most frequently observed. In some cases, dotted, comma-like, coiled, globular, arboriform, hairpin-like and even polymorphic vessels may be present.<sup>2–6</sup> Dermoscopic features such as pigment network, follicles, erosions, and scales have also been reported associated with this entity.<sup>3,4</sup>

### Conflict of interests

The authors state that they have no conflict of interests.

### References

1. Dehner LP. Juvenile xanthogranulomas in the first two decades of life: a clinicopathologic study of 174 cases with cutaneous and extracutaneous manifestations. *Am J Surg Pathol.* 2003;27:579–93, <http://dx.doi.org/10.1097/0000478-200305000-00003>.
2. Song M, Kim SH, Jung DS, Ko HC, Kwon KS, Kim MB. Structural correlations between dermoscopic and histopathological features of juvenile xanthogranuloma. *J Eur Acad Dermatol Venereol.* 2011;25:259–63, <http://dx.doi.org/10.1111/j.1468-3083.2010.03819.x>.
3. Xu J, Ma L. Dermoscopic patterns in juvenile xanthogranuloma based on the histological classification. *Front Med.* 2021;7:618946, <http://dx.doi.org/10.3389/fmed.2020.618946>.
4. Di Brizzi EV, Moscarella E, Scharf C, Argenziano G, Piccolo V. Dermoscopy of juvenile xanthogranuloma: a retrospective descriptive study on 35 pediatric patients. *J Eur Acad Dermatol Venereol.* 2022;36:e846–8, <http://dx.doi.org/10.1111/jdv.18316>.
5. Palmer A, Bowling J. Dermoscopic appearance of juvenile xanthogranuloma. *Dermatology.* 2007;215:256–9, <http://dx.doi.org/10.1159/000106586>.
6. Peruih-Bagolini L, Silva-Astorga M, Hernandez San Martin MJ, et al. Dermoscopy of juvenile xanthogranuloma. *Dermatology.* 2020;19:1–6, <http://dx.doi.org/10.1159/000510265>.

M. Valiūskytė<sup>a,\*</sup>, C. Gonçalves-Castro<sup>b</sup>, A. Miroux-Catarino<sup>b</sup>

<sup>a</sup> Department of Skin and Venereal Diseases, Hospital of Lithuanian University of Health Sciences Kauno Klinikos, Kaunas, Lithuania

<sup>b</sup> Dermatology Department, Hospital de Egas Moniz, Lisboa, Portugal

\* Corresponding author.

E-mail address: [m.valiuskyte@gmail.com](mailto:m.valiuskyte@gmail.com) (M. Valiūskytė).