

## CASES FOR DIAGNOSIS

### [Translated article] Patient With Relapsing Polychondritis and Cutaneous Nodules Being Followed by the Hematology Department for a Myelodysplastic Syndrome

Un paciente con una policondritis recidivante y nódulos cutáneos en seguimiento en hematología por un síndrome mielodisplásico

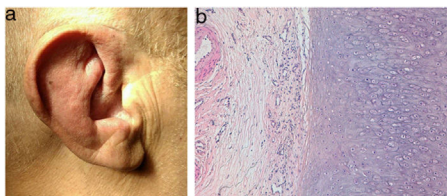
#### Clinical history and physical examination

A 71-year-old man presented with a 6-month history recurrent inflammation of the pinnae (Fig. 1A) that led to a diagnosis of relapsing polychondritis. Additionally, he showed erythematous nodular lesions on both his trunk and extremities.

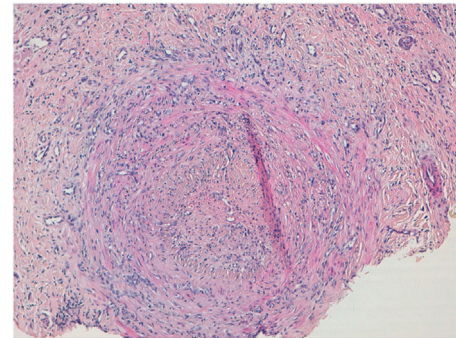
The patient reported a 21 kg weight loss over the past 12 months, without associated fever. Bilateral episcleritis, atrial fibrillation, recurrent epididymitis, and pancytopenia were some of the patient's concomitant medical problems.

#### Histopathology

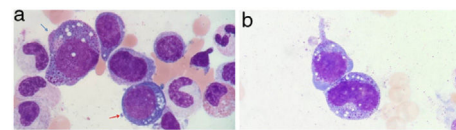
The histopathological examination of the auricular cartilage revealed the presence of lymphocytic infiltration in the perichondrium (Fig. 1B), and the biopsy of cutaneous nodular lesions showed medium-sized artery vasculitis (Fig. 2),



**Figure 1** A: Erythema and edema of the pinnae. B: Auricular cartilage biopsy with degenerated cartilage and chronic inflammation in the perichondrium. Hematoxylin-eosin,  $\times 100$ .



**Figure 2** Biopsy of nodular lesion on the leg with presence of medium-sized artery vasculitis and vascular occlusion with recanalization. Hematoxylin-eosin,  $\times 100$ .



**Figure 3** A: Vacuolization of the nucleus and cytoplasm of myeloid (blue arrow) and erythroid (red arrow) precursors in the bone marrow aspirate. May-Grunwald-Giemsa,  $\times 100$ . B: Vacuolization of the nucleus and cytoplasm of myeloid precursors in bone marrow aspirate. May-Grunwald-Giemsa,  $\times 100$ .

with a predominantly neutrophilic inflammatory infiltrate in the vascular wall, and vascular lumen occlusion.

#### Supplementary tests

Acute phase reactants were elevated, with ferritin levels of 6830 (normal range from 20 to 250) and CRP levels of 130 (normal range from 0 to 5).

A bone marrow aspirate was performed to study pancytopenia, which revealed the presence of multilineage dysplasia and prominent cytoplasmic and nuclear vacuolization of myeloid and erythroid precursors (Fig. 3A and 3B).

For the diagnostic confirmation of the suspected syndrome, the UBA1 gene analysis performed confirmed the c.122T>C, p.(Met41Thr) mutation.

#### What is the diagnosis?

DOI of original article:  
<https://doi.org/10.1016/j.ad.2022.07.023>

<https://doi.org/10.1016/j.ad.2024.01.006>

0001-7310/© 2022 AEDV. Published by Elsevier España, S.L.U. This is an open access article under the CC BY-NC-ND license (<http://creativecommons.org/licenses/by-nc-nd/4.0/>).

## Diagnosis

VEXAS syndrome (Vacuoles, E1 enzyme, X-linked, Autoinflammatory, Somatic).

## Treatment and evolution

The patient received off-label treatment with adalimumab but passed away 5 months after diagnosis.

## Comment

VEXAS syndrome is an adult-onset autoinflammatory condition first described by Beck et al. in December 2020.<sup>1</sup> It is due to a somatic mutation of the UBA1 gene that causes dysfunctional ubiquitination and consequent proteotoxic stress with activation of innate immunity. It has mainly been described in middle-aged men.<sup>2</sup>

Patients develop systemic signs and symptoms such as fever, fatigue, and weight loss, with skin lesions in up to 83% of the cases,<sup>2</sup> often in the form of erythematous-violaceous papules and nodules. The predominant histopathological pattern of such lesions is neutrophilic infiltration, with or without vasculitis. A total of 32% of the patients from Beck et al.'s series had previously been diagnosed with Sweet's syndrome, and 12% with polyarteritis nodosa.<sup>1</sup> However, cases have also been reported where skin biopsies confirmed the presence of perivascular lymphocytic infiltrates without neutrophils or vasculitis.<sup>3</sup> Other cutaneous findings associated with this entity include livedo racemosa and relapsing polychondritis in up to 64% of the patients.<sup>4</sup>

Hematological signs are characterized by cytopenias, myelodysplastic syndrome, and vacuolization of myeloid and erythroid precursors in bone marrow biopsies.<sup>1</sup> However, precursor vacuolization is not pathognomonic of this entity and can also occur in alcoholic patients, those with copper deficiency, or due to myeloid neoplasms.

Other clinical signs of the VEXAS syndrome include arthritis, serositis, episcleritis, scleritis, pericarditis, myocarditis, neutrophilic alveolitis, epididymitis, large-vessel vasculitis, venous thromboembolism, abdominal pain, and GI bleeding.<sup>2</sup> Elevated acute phase reactants are often seen too in the blood tests.

The disease often has an aggressive course. However, since this entity has been recently described, these data should be interpreted with caution, because milder cases may still go unnoticed, and genetic testing are only often performed in patients with more severe clinical signs. It has recently been observed that patients with the p.Met41Leu mutation in UBA1 gene may have a better prognosis.<sup>2</sup>

The proper management of this syndrome has not been standardized yet. A plethora of drugs has been suggested, including systemic corticosteroids, azathioprine, methotrexate, mycophenolate, cyclophosphamide, anti-IL-1, anti-IL-6, anti-TNF, rituximab, IV immunoglobulins, abatacept, and anti-JAK, with variable results.<sup>5</sup> Recently, allogeneic hematopoietic stem cell transplantation has been proposed as an option with promising and sustained results.<sup>6</sup>

VEXAS syndrome is a complex, recently described entity with a fatal course in most cases. Therefore, awareness of this condition is important to facilitate early diagnosis and

treatment. Targeted molecular therapy to restore ubiquitination in these patients may join the therapeutic arsenal in the coming future.

## Funding

None declared.

## Conflicts of interest

None declared.

## References

1. Beck DB, Ferrada MA, Sijora KA, Ombrello AK, et al. Somatic Mutations in UBA1 and Severe Adult-Onset Autoinflammatory Disease. *N Engl J Med*. 2020;383:2628–38.
2. Geogin-Lavialle S, Terrier B, Guedon AF, Heiblig M, et al. Further characterization of clinical and laboratory features in VEXAS syndrome: large-scale analysis of a multicentre case series of 116 French patients. *Br J Dermatol*. 2022;186:564–74, <http://dx.doi.org/10.1111/bjd.20805>.
3. Khosravi-Hafshejani T, O'Connor M, To F, Sreenivasan G, Shojania K, Au S. The spectrum of skin disease in VEXAS syndrome: a report of a novel clinicohistopathologic presentation. *J Eur Acad Dermatol Venerol*. 2022;36:35–7, <http://dx.doi.org/10.1111/jdv.17924>.
4. Zakine E, Schell B, Battistella M, Vignon-Pennamen MD, et al. UBA1 Variations in Neutrophilic Dermatitis Skin Lesions of Patients With VEXAS Syndrome. *JAMA Dermatol*. 2021;157:1349–54.
5. Kirino Y, Takase-Minegishi K, Tsuchida N, Hirahara L. Tocilizumab in VEXAS relapsing polychondritis: a single-center pilot study in Japan. *Ann Rheum Dis*. 2021;80:1501–2, <http://dx.doi.org/10.1136/annrheumdis-2021-220876>.
6. Diarra A, Duployez N, Fournier E, Preudhomme C, et al. Successful allogeneic hematopoietic stem cell transplantation in patients with VEXAS syndrome: a two center experience. *Blood Adv*. 2022;6:998–1003, <http://dx.doi.org/10.1182/bloodadvances.2021004749>.

C. Couselo-Rodríguez<sup>a,b,\*</sup>, M.Á. Viejo-Rodríguez<sup>c</sup>, L. Carballeira-Seoane<sup>d</sup>, C. Álvarez-Álvarez<sup>e</sup>, E. Cervates-Pérez<sup>f</sup>, M.Á. García-González<sup>g</sup>, Á. Flórez<sup>a,b</sup>

<sup>a</sup> Servicio de Dermatología, Complejo Hospitalario Universitario de Pontevedra, Pontevedra, Spain

<sup>b</sup> Grupo de Investigación DIPO, Instituto de Investigación Sanitaria Galicia Sur (IIS Galicia Sur), SERGAS-UVIGO, Spain

<sup>c</sup> Servicio de Medicina Interna, Complejo Hospitalario Universitario de Pontevedra, Pontevedra, Spain

<sup>d</sup> Servicio de Hematología, Complejo Hospitalario Universitario de Pontevedra, Pontevedra, Spain

<sup>e</sup> Servicio de Anatomía Patológica, Complejo Hospitalario Universitario de Pontevedra, Pontevedra, Spain

<sup>f</sup> Servicio de Reumatología, Complejo Hospitalario Universitario de Pontevedra, Pontevedra, Spain

<sup>g</sup> Fundación Pública Galega de Medicina Xenómica, Santiago de Compostela, Spain

\* Corresponding author.

E-mail address: [carmen.couselo.rodriguez@sergas.es](mailto:carmen.couselo.rodriguez@sergas.es) (C. Couselo-Rodríguez).