

CASE AND RESEARCH LETTER

A Case of Pyoderma Gangrenosum-Like Ulcers Progressing into Neutrophilic Panniculitis in a Patient With Myelodysplastic Syndrome

Un caso de úlceras similares al pioderma gangrenoso que posteriormente desarrollaron paniculitis neutrofílica en un paciente con síndrome mielodisplásico

To the Editor:

This is a rare case that presented with pyoderma gangrenosum-like cervical ulcers followed by painful subcutaneous nodules on the lower legs showing neutrophilic

panniculitis on the histopathological examination in a patient with myelodysplastic syndrome.

This is the case of a 51-year-old man hospitalized due to myelodysplastic syndrome who received chemotherapy with azacytidine without granulocyte colony-stimulating factor. He developed a skin ulcer and subcutaneous induration at the central venous catheter insertion site on the right neck (Fig. 1a). Although skin biopsy was not performed at this time, PG was suspected, and oral prednisolone (PSL) (60 mg/day) was started. The skin ulcer healed in 3 weeks. After a remission induction therapy, anthracycline was administered for 3 days and cytarabine for 7, PSL was down-titrated to 25 mg, and no recurrences of the cervical lesions were seen. However, new and painful subcutaneous indurations appeared on the extremities with high fever. The blood test showed elevated C-reactive protein levels (2.51 mg/dL) and decreased platelet count ($1.0 \times 10^4/\mu\text{L}$). The physical examination

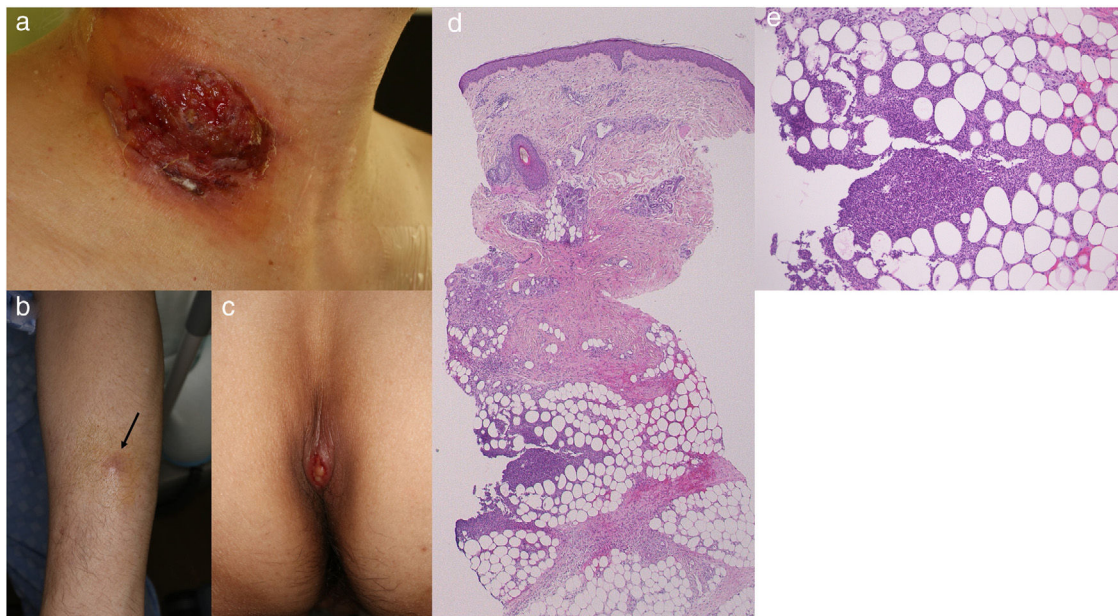


Figure 1 (a) Well-demarcated deep ulcer on the central vein catheter insertion site. (b) Painful erythematous nodules on the forearm (arrow). (c) Ulcerative lesion on the sacral area. (d) Histopathology examination showing lobular panniculitis (H-E, $\times 20$). (e) Higher magnification showing neutrophil infiltration inside the fat tissue (H-E, $\times 200$).

<https://doi.org/10.1016/j.ad.2023.02.034>

0001-7310/© 2023 AEDV. Published by Elsevier España, S.L.U. This is an open access article under the CC BY-NC-ND license (<http://creativecommons.org/licenses/by-nc-nd/4.0/>).

Please cite this article as: K. Irie and T. Yamamoto, A Case of Pyoderma Gangrenosum-Like Ulcers Progressing into Neutrophilic Panniculitis in a Patient With Myelodysplastic Syndrome, ACTAS Dermo-Sifiliográficas, <https://doi.org/10.1016/j.ad.2023.02.034>

revealed the presence of multiple tender subcutaneous erythematous indurations (about 0.5–2 cm in diameter), on the forearms and thighs, as well as sacral ulcer (Fig. 1b, c). Local samples for bacteriological and mycological tests tested negative, and the patient's response to antibiotics was poor. Skin biopsy of the subcutaneous induration on the left forearm showed hemorrhage, neutrophil and lymphocyte infiltration of the deep dermis, and neutrophilic lobular panniculitis, without any signs of vasculitis (Fig. 1d, e). The lesions on the extremities and sacral area improved without up-titration of the dose of PSL.

In the current case, deep ulcers at the central venous catheter insertion site on the right neck were considered a pathergy reaction, a characteristic feature of PG. There were no ulcerative lesions suggestive of PG on any part of the body other than the neck. After 2 months, painful subcutaneous erythematous nodules appeared on the extremities, and a skin biopsy revealed the presence of neutrophilic lobular panniculitis. Because neither septal panniculitis nor Miescher radial granuloma was seen, erythema nodosum was excluded. PG and neutrophilic panniculitis are both categorized as deep neutrophilic dermatoses,¹ suggesting a shared pathogenesis. Neutrophilic lobular panniculitis is observed in subcutaneous Sweet's syndrome. PG and Sweet's syndrome are the representative diseases of neutrophilic dermatosis, and both diseases often clinically present with similar features, which are difficult to differentiate, especially in patients with hematologic disorders.^{2–4} Such overlapped or atypical cases have been reported under the term 'neutrophilic dermatosis of myeloproliferative disorders', suggesting a linking of entities of both disorders in a continuous pathologic spectrum.⁵ Although the cervical ulcer was not biopsied in the present case, ulcerative neutrophilic panniculitis cannot be ruled out.

The VEXAS syndrome (vacuoles, E1 enzyme, X-linked, autoinflammatory, somatic) is an inflammatory disease due to somatic UBA1 variants presenting with myelodysplasia, and autoinflammatory symptoms including chondritis, vasculitis, and neutrophilic dermatosis.⁶ The VEXAS syndrome

was listed as a differential disease because of the common complication of neutrophilic dermatosis and myelodysplastic syndrome. However, it was ruled out in this case because the granulocyte progenitor cells did not contain cytoplasmic vacuoles in the bone marrow biopsy. The current case of myelodysplastic syndrome presented with different clinical phenotypes such as deep ulcer, and painful erythematous subcutaneous nodules at different points in time, both of which were due to activated neutrophils.

Conflict of interests

The authors declare that they have no conflict of interest.

References

1. Wallach D, Vignon-Pennamen MD. From acute febrile neutrophilic dermatosis to neutrophilic disease: forty years of clinical research. *J Am Acad Dermatol.* 2006;55:1066–71.
2. Pye RJ, Choudhury C. Bullous pyoderma as a presentation of acute leukemia. *Clin Exp Dermatol.* 1977;2:33–8.
3. Burton JL. Sweet's syndrome, pyoderma gangrenosum and acute leukaemia. *Br J Dermatol.* 1980;102:239.
4. Caughman W, Stern R, Haynes H. Neutrophilic dermatosis of myeloproliferative disorders. *J Am Acad Dermatol.* 1983;9:751–8.
5. Wallach D, Vignon-Pennamen MD. Pyoderma gangrenosum and Sweet syndrome: the prototypic neutrophilic dermatoses. *Br J Dermatol.* 2018;178:595–602.
6. Beck DB, Ferrada MA, Sikora KA, Ombrello AK, Collins JC, Pei W, et al. Somatic mutations in *UBA1* and severe adult-onset autoinflammatory disease. *N Engl J Med.* 2020;31:2628–38.

K. Irie*, T. Yamamoto

Department of Dermatology, Fukushima Medical University, Fukushima, Japan

* Corresponding author.

E-mail address: kinuko07@fmu.ac.jp (K. Irie).