

CASE FOR DIAGNOSIS

Hyperpigmented Verrucous Plaques in a Healthy Young Woman



Placas verrugosas hiperpigmentadas en una joven sana

Medical history

A 36-years-old female patient, previously healthy, reported hyperpigmented lesions in the intermammary region, armpits and face. Denied any local symptoms. Lesions had started five years ago and increased in extent over the years. She also complained of facial comedones and visible pores, without any previous treatment. There was a family history of similar lesions – father and paternal grandmother. She denied any systemic symptoms.

Physical examination

On physical examination, there were reticulated brown patches in the presternal area (Fig. 1), and similar small plaques in the inguinal region and the armpits bilaterally. Small slightly atrophic macules were visible on the dorsum of the hands. On the face, comedo-like lesions, dilated pores, and diffuse hyperpigmented plaques all over the face, especially on the forehead (Fig. 2), bilateral malar, perioral and supramandibular regions. She also presents pitted scars on the perioral region.

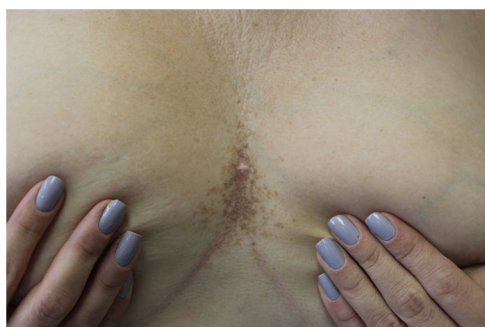

Figure 1

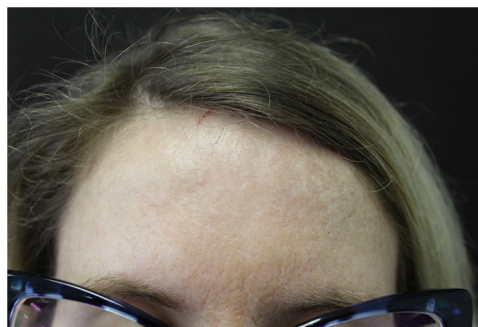

Figure 2

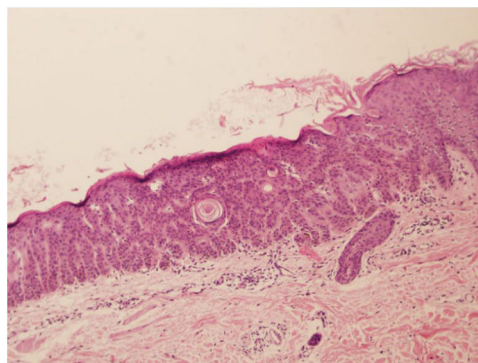


Figure 3

Histopathology

Histopathology evaluation of lesions in the presternal area presented digitiform epithelial proliferation and corneal pseudocysts (Fig. 3).

Additional tests

Laboratory tests showed no changes.

What is your diagnosis?

<https://doi.org/10.1016/j.ad.2022.07.039>

0001-7310/© 2023 AEDV. Published by Elsevier España, S.L.U. This is an open access article under the CC BY-NC-ND license (<http://creativecommons.org/licenses/by-nc-nd/4.0/>).

Diagnosis

Dowling-Degos disease.

Clinical course and treatment

The patient was counseled about the genetic nature of the disease; daily use of a topical retinoid was prescribed initially.

Comment

Dowling-Degos disease (DDD) is a rare autosomal dominant genodermatosis, with variable penetrance, that presents a mutation in the KTR5 gene.¹ The first signs of the disease usually occur in the third or fourth decades of life.² It is clinically characterized by follicular hyperpigmentation in flexor areas, such as the neck armpit, antecubital fossa, submammary region, and groin. Pigmentation of the dorsum of the hands may be present when there is an overlap of clinical features of Kitamura's reticulate acropigmentation.³ Additional findings include pitted perioral scars in patients with no prior history of acne, and hyperkeratotic comedo-like papules in the neck and armpits.¹ Some patients may report related pruritus.²

The disease is often associated with other dermatoses such as epidermal cysts, keratoacanthomas, hidradenitis suppurativa, seborrheic keratoses, which can be the main complaint in dermatological consultations.⁴

Histopathology shows moderate hyperkeratosis or orthokeratosis, thinned suprapapillary epithelium, elongation of the papillae with hyperpigmentation of the basal layer. Filiform proliferations of the epidermis usually involve the follicle with a follicular plug. A perivascular lymphohistiocytic infiltrate in the papillary dermis and corneal pseudocysts can also be observed.¹

Dermatoscopy of the hyperpigmented macules usually reveal a regular arrangement of brownish spots of variable size, characterized by a coarse grid of brown lines on a diffuse, light brown background. Therefore, these findings are not specific and are seen in many other conditions.⁵

DDD must be differentiated from acanthosis nigricans and Kitamura's reticulate acropigmentation. In acanthosis nigricans, the plaques have a velvet like rather than flattened or minimally lichenified texture, and there are no pitted perioral scars or comedo-like lesions. In Kitamura's reticulate

acropigmentation there are reticulate, slightly depressed, pigmented acropigmentation macules on acral areas, especially on the dorsum of the hands and feet; palmar pits or breaks in epidermal ridge pattern.⁶

Treatment has unsatisfactory results in most cases. Topical therapeutic options include retinoids, hydroquinone, corticosteroids and azelaic acid. Treatment with Er:YAG laser or isotretinoin is also described.

Conflict of interest

The authors declare they have no conflict of interest.

References

1. Hohmann CB, Köche B, Bonamigo RR, Dornelles ST, Cattani CAS. A case for diagnosis: Dowling-Degos disease and keratoacanthoma. *An Bras Dermatol*. 2010;85:241–3.
2. Zimmermann CC, Sforza D, Macedo PM, Azulay-Abulafia L, Alves MFGS, Carneiro SCS. Doença de Dowling-Degos: apresentação clínica e histopatológica clássica. *An Bras Dermatol*. 2011;86:979–82.
3. Wu YH, Lin YC. Generalized Dowling-Degos disease. *J Am Acad Dermatol*. 2007;57:327–34.
4. Fenske NA, Groover CE, Lober CW, Espinoza CG. Dowling-Degos disease, hidradenitis suppurativa, and multiple keratoacanthomas. A disorder that may be caused by a single underlying defect in pilosebaceous epithelial proliferation. *J Am Acad Dermatol*. 1991;24:888–92.
5. Dabas G, Mahajan R, Afra TP, De D, Handa S, Aggarwal D, et al. Dermoscopy of follicular Dowling-Degos disease. *Indian J Dermatol*. 2020;65:290–4.
6. You Chan K, Davis MDP, Schanbacher CF, Su DWP. Dowling-Degos disease (reticulate pigmented anomaly of the flexures): a clinical and histopathologic study of 6 cases. *J Am Acad Dermatol*. 1999;40:462–7.

L. Mombach Mota^{a,*}, M.A. Matico Utsumi Okada^a, R. Heck^{a,b}

^a *Sanitary Dermatology Outpatient Clinic, Health Department of Rio Grande do Sul State – SES/RS, Porto Alegre, Brazil*

^b *Dermatology Department, Hospital de Clínicas de Porto Alegre (HCPA), Porto Alegre, Brazil*

* Corresponding author.

E-mail address: laurambmota@gmail.com

(L. Mombach Mota).