




ACADEMIA ESPAÑOLA
DE DERMATOLOGÍA
Y VENEREOLOGÍA

ACTAS Dermo-Sifiliográficas

Full English text available at
www.actasdermo.org



BRIEF COMMUNICATION

[Translated article] Dactylitis Due to Subcutaneous Sarcoidosis as a Manifestation of Sarcoidosis



J. Marcoval*, C. Llobera-Ris, C. Moreno-Vílchez, C. Torrecilla-Vall-Llossera, J. Sánchez Sánchez, J. Molinero Caturla

Servicio de Dermatología, Hospital Universitari de Bellvitge, Universitat de Barcelona, IDIBELL, L'Hospitalet de Llobregat, Barcelona, Spain

KEYWORDS

Dactylitis;
Sarcoid dactylitis;
Sarcoidosis;
Subcutaneous sarcoidosis

Abstract Dactylitis, or sausage fingers or toes, refers to the swelling of 1 or more digits. Sarcoid dactylitis is an uncommon form that tends to be caused by granulomatous bone involvement in the underlying phalanges. Sarcoid dactylitis can, however, clinically resemble subcutaneous sarcoidosis with finger or toe involvement. We describe 5 patients with dactylitis due to subcutaneous sarcoidosis of the fingers. In all cases, the proximal phalanges were involved; sarcoid dactylitis, by contrast, tends to affect the medial and distal phalanges. Differential diagnosis is important, as dactylitis due to bone involvement tends to be much more persistent and is generally seen in chronic forms of sarcoidosis.

© 2022 AEDV. Published by Elsevier España, S.L.U. This is an open access article under the CC BY-NC-ND license (<http://creativecommons.org/licenses/by-nc-nd/4.0/>).

PALABRAS CLAVE

Dactilitis;
Dactilitis sarcoidea;
Sarcoidosis;
Sarcoidosis subcutánea

Dactilitis producida por sarcoidosis subcutánea como presentación de sarcoidosis

Resumen La dactilitis, o dedo en salchicha, se define como la inflamación de uno o varios dedos de las manos o de los pies. La dactilitis sarcoidea es una forma poco frecuente de dactilitis que suele ser debida a la afectación ósea granulomatosa a nivel de las falanges subyacentes. Sin embargo, una apariencia clínica similar puede deberse a la presencia de una sarcoidosis subcutánea en los dedos. Describimos 5 pacientes con dactilitis por una sarcoidosis subcutánea de los dedos. En nuestros pacientes las lesiones se localizaron en las falanges proximales, a diferencia de la dactilitis sarcoidea por afectación ósea, en la que suelen localizarse en las falanges medias y distales. Es importante el diagnóstico diferencial, puesto que la dactilitis por afectación ósea suele ser mucho más persistente y asociarse a formas crónicas de sarcoidosis.

© 2022 AEDV. Publicado por Elsevier España, S.L.U. Este es un artículo Open Access bajo la licencia CC BY-NC-ND (<http://creativecommons.org/licenses/by-nc-nd/4.0/>).

DOI of original article:

<https://doi.org/10.1016/j.ad.2022.03.013>

* Corresponding author.

E-mail address: jmarcoval@bellvitgehospital.cat (J. Marcoval).

<https://doi.org/10.1016/j.ad.2022.03.027>

0001-7310/© 2022 AEDV. Published by Elsevier España, S.L.U. This is an open access article under the CC BY-NC-ND license (<http://creativecommons.org/licenses/by-nc-nd/4.0/>).

Introduction and Objectives

Dactylitis or sausage finger is defined as inflammation of one or several fingers or toes.¹ Although any inflammatory process involving the digits could be considered dactylitis, the term is reserved for a few well-defined entities. It is considered one of the differential clinical features of spondyloarthropathies and, in particular, psoriatic arthritis. However, it can manifest during the course of diseases including gout, sarcoidosis, tuberculosis, and syphilis.^{1,2}

Sarcoid dactylitis is a rare manifestation of sarcoidosis. Most cases of sarcoid dactylitis are due to granulomatous involvement of the bone of the underlying phalanges.³ However, subcutaneous sarcoidosis of the digits can give rise to a similar clinical presentation. Below, we report cases of subcutaneous sarcoidosis of the digits with a clinical presentation resembling dactylitis due to underlying bone involvement.

Material and Methods

We reviewed diagnosed cases of subcutaneous sarcoidosis recorded in the database of specialized sarcoidosis consultations between 1988 and 2021 in a tertiary university hospital that provides care to approximately 1 000 000 people. Clinical histories of the patients were reviewed and clinical images were examined to detect cases that presented lesions on the fingers.

Results

We identified 5 patients with subcutaneous sarcoidosis of the fingers over a period of 33 years: 3 women and 2 men, aged 45–75 years (Table 1).

All patients consulted for their skin lesions. Four patients had lesions predominantly on the forearms, while in the remaining patient the lesions were limited to the fingers (Fig. 1). The time since lesion appearance ranged from 3 to 24 months. The lesions were not painful and persisted for 8–60 months in the 4 patients who were followed up until resolution (Table 1).

None of the patients had systemic symptoms at the time of diagnosis. In all cases biopsy of the lesions revealed sarcoid granulomatous infiltration in the subcutaneous cellular tissue (in the forearms in 3 cases and the fingers in 2 cases).

Extracutaneous lesions consisted of bilateral hilar adenopathies in 3 cases, as revealed by chest radiography. Conjunctival granulomas were detected in another case without intrathoracic involvement. The remaining patient developed dactylitis lesions during the course of atezolizumab treatment for disseminated endometrial carcinoma, but showed no signs of extracutaneous involvement. Angiotensin converting enzyme (ACE) levels were elevated in 3 of the 4 cases in which they were determined.

Discussion

Dactylitis can be acute, characterized by painful inflammation of the finger, or can manifest as a chronic form,

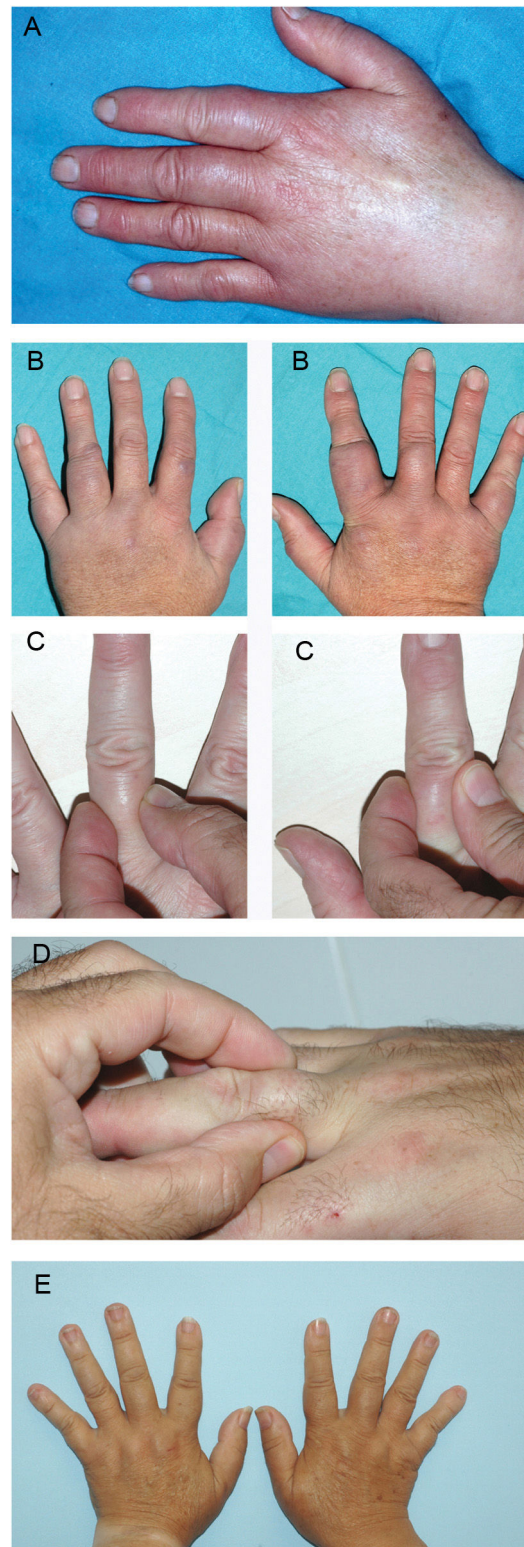


Figure 1 A, Case 1. Dactylitis in the proximal phalanges of the first, second, and third fingers of the left hand. B, Case 2. Dactylitis in the proximal phalanges of 3 fingers of each hand. C, Case 3. Dactylitis in the proximal phalanges of the left middle finger and the right index finger. D, Case 4. Dactylitis in the proximal phalanx of the right ring finger. E, Case 5. Dactylitis in the proximal phalanges of the index, middle, and ring fingers of each hand.

Table 1 General Characteristics of the Patients.

Case	Sex	Age	Time since onset, mo	Duration, mo	Dactylitis location	Other specific cutaneous sarcoidosis lesions	Radiological stage and extracutaneous involvement	ACE	Imaging studies	Treatment
1	F	70	12	60	Proximal phalanges 8 fingers	Subcutaneous, forearms Scar on elbow	1 Hilar and mediastinal adenopathies	-		Prednisone
2	M	63	24	36	Proximal phalanges 6 fingers	Subcutaneous, forearms and knees Papules on the knees Plaques on the trunk	1 Hilar lymphadenopathy Hepatosplenic	0.71 (kat/L ($n < 0.87$))	ECO: subcutaneous nodular lesions	Prednisone Hydroxychloroquine
3	F	75	12	18	Proximal phalanges 5 fingers	Subcutaneous, forearms and legs Papules on knees	0 Conjunctival	64 U/L ($n < 52$)	Forearm radiograph without bone lesions ECO: subcutaneous nodular lesions	No treatment
4	M	45	3	^a	Proximal phalanx Right ring finger	Subcutaneous, forearms	1 Hilar lymphadenopathy Choroidal granulomas	54 U/L ($n < 52$)	ECO: subcutaneous nodular lesions on fingers and forearms	^a
5	F	68	6	8	Proximal phalanges of fingers 2, 3, and 4 of each hand	-	No extracutaneous involvement detected ^b	107 U/L ($n < 52$)	Radiography of hands, no bone lesions ECO: subcutaneous nodular lesions on fingers	No treatment

Abbreviations: ACE, angiotensin-converting enzyme; ECO, echography; F, female; M, male.

^a Case 4: lost to follow-up due to change of address.

^b Case 5: subcutaneous sarcoidosis during treatment with atezolizumab.

which tends to be more persistent and less painful.² The distinct forms of dactylitis also differ in terms of the affected tissue and the type of involvement. The most frequent forms are dactylitis due to spondyloarthritis, especially psoriatic arthritis, which causes painful diffuse inflammation of the fingers and toes.^{1,2} Studies using ultrasound and nuclear magnetic resonance have established that this form is due to tenosynovitis of the flexors.^{1,2} Tenosynovitis that arises during the course of gout is also a common cause of dactylitis. Pyogenic (usually streptococcal) infection of the soft parts of the finger also manifests as acute dactylitis. Another less frequent form is tuberculous dactylitis, which is caused by tuberculous osteomyelitis of the short tubular bones of the hands or feet.^{1,2} Syphilitic dactylitis is a manifestation of congenital syphilis that is characterized by radiological findings similar to those of tuberculous dactylitis, although the involvement is usually bilateral and symmetrical.

Sarcoid dactylitis^{1,2} is an uncommon manifestation of sarcoidosis that is seen in 0.2% of patients. It is defined as the presence of swelling in the fingers or toes in patients with sarcoidosis, mainly affecting the middle and, less frequently, distal phalanges.^{3,4} Radiologically, sarcoid dactylitis is characterized by trabecular alterations with a honeycomb or lattice pattern, which may or may not be associated with cystic formations and periosteal reaction.⁵ Histologically, osseous lesions are characterized by noncaseating granulomas that invade the phalanges and surrounding soft tissue. This form of sarcoid dactylitis due to granulomatous bone involvement is very persistent, and is associated with lupus pernio and chronic forms of sarcoidosis.⁶

In addition to sarcoid dactylitis due to granulomatous involvement of the bone of the underlying phalanges, the term dactylitis has also been applied to patients with subcutaneous sarcoidosis affecting the fingers.^{7,8} These patients can exhibit a similar clinical presentation. However, in subcutaneous sarcoidosis the proximal phalanges are more frequently affected than the middle and distal phalanges,⁷ as in all our patients. Another significant difference is that subcutaneous sarcoidosis of the fingers appears at the onset of the systemic disease, and therefore its recognition can enable early diagnosis of systemic sarcoidosis, avoiding the need for invasive examinations.⁹⁻¹² Because it is a form of subcutaneous sarcoidosis, it could be assumed that it has similar prognostic significance regarding the course of systemic sarcoidosis. Some studies have proposed that subcutaneous sarcoidosis is associated with acute forms of sarcoidosis.⁹⁻¹² In agreement with those findings, none of our patients developed complications typical of chronic sarcoidosis, such as bone lesions or pulmonary fibrosis.

In 4 of our 5 patients, dactylitis was associated with subcutaneous sarcoid lesions in other locations. Therefore, when sarcoid dactylitis is suspected, the remaining extremities should be examined for subcutaneous nodular lesions, especially the forearms.¹³ As in the case described by Curcó et al.,⁷ we did not detect underlying bone lesions in any of our patients.

Treatment of sarcoid dactylitis due to underlying bone involvement usually requires high-dose oral corticosteroids combined with antimalarials and methotrexate, or even

the use of anti-TNF (tumor necrosis factor) drugs such as infliximab or adalimumab.^{3,14} In our patients, digital lesions did not require specific treatment. Two of our patients received systemic treatment, indicated for extracutaneous involvement: oral corticosteroids in one case and oral corticosteroids plus hydroxychloroquine in the other. The digital lesions remained partially controlled until complete resolution (after 60 and 36 months, respectively). In the remaining 2 patients for whom clinical follow-up data were available, the digital lesions remitted spontaneously without requiring any treatment, with a total lesion duration of 8 and 18 months, respectively.

Although the clinical appearance may be similar, sarcoid dactylitis due to granulomatous infiltration of the underlying phalanges must be distinguished from sarcoid dactylitis due to subcutaneous involvement, owing to the differences in clinical course and prognostic significance. Ultrasound can be a fundamental tool for differential diagnosis.¹⁵

Dactylitis due to subcutaneous sarcoidosis is usually present at the onset of systemic sarcoidosis, usually affects the proximal phalanges, and is often accompanied by subcutaneous sarcoidosis in other locations, especially the forearms. It is necessary to rule out the presence of underlying bony lesions in cases of persistent dactylitis involving the middle and distal phalanges.

Conflicts of Interest

The authors declare that they have no conflicts of interest.

References

- Olivieri I, Scarano E, Padula A, Giasi V, Priolo F. Dactylitis, a term for different digit diseases. *Scand J Rheumatol.* 2006;35:333-40.
- Torre Alonso JC. Dactylitis: evaluación, implicaciones pronósticas y abordaje terapéutico. *Reumatol Clin.* 2007;3 Suppl. 2:S7-9.
- García-Morales I, Sánchez García E, Crespo Cruz A, Escudero J. Dactylitis granulomatosa como manifestación inusual de la sarcoidosis. *Actas Dermosifiliogr.* 2021. Epub ahead of print.
- Mori T, Yamamoto T. Dactylitis in sarcoidosis. *J Dermatol.* 2017;44:e340-1.
- Alaya Z, Mzabi A. Lytic lesion involving the first phalanx: sarcoidosis should be suspected. *Pan Afr Med J.* 2017;26:210.
- Pitt P, Hamilton EB, Innes EH, Morley KD, Monk BE, Hughes GR. Sarcoid dactylitis. *Ann Rheum Dis.* 1983;42:634-9.
- Curco N, Pagerols X, Vives P. Subcutaneous sarcoidosis with dactylitis. *Clin Exp Dermatol.* 1995;20:434-5.
- González-Cantero Á, Sánchez-Moya AI, Martínez-Lorenzo E, Pérez-Hortet C, Schoendorff-Ortega C. Subcutaneous sarcoidosis with dactylitis. *J Cutan Med Surg.* 2018;22:506.
- Marcoval J, Maña J, Moreno A, Peyri J. Subcutaneous sarcoidosis-clinicopathological study of 10 cases. *Br J Dermatol.* 2005;153:790-4.
- Ahmed I, Harshad SR. Subcutaneous sarcoidosis: is it a specific subset of cutaneous sarcoidosis frequently associated with systemic disease? *J Am Acad Dermatol.* 2006;54:55-60.
- Marcoval J, Penín RM, Maña J. Histopathological features of subcutaneous sarcoidosis. *Am J Dermatopathol.* 2020;42:233-43.
- Lopez-Sundh AE, Maestre-Orozco T, Gonzalez-Vela MC, Fernandez-Ayala M. Subcutaneous sarcoidosis: a case series of 19 patients. *J Postgrad Med.* 2021;67:154-7.

13. Norikawa N, Yamamoto T. Subcutaneous sarcoidosis on the digits. *Sarcoidosis Vasc Diffuse Lung Dis.* 2020;37:e2020010.
14. Alawneh D, Al-Shyoukh A, Edrees A. TNF inhibitor treating osseous sarcoidosis and dactylitis: case and literature review. *Clin Rheumatol.* 2020;39:2219-22.
15. López-Llunell C, Romaní J, Roé E, Giavedoni P, Vidal D, Wortsman X. Ultrasonographic patterns of cutaneous sarcoidosis. *J Ultrasound Med.* 2021;40:2521-6.