

## IMAGES IN DERMATOLOGY

### [Translated article] Long-Standing Proliferating Trichilemmal Cyst



### Quiste tricolemal proliferante de larga data

L. Linares-Gonzalez<sup>a,b</sup>, A. Ayén-Rodríguez<sup>a,b</sup>, R. Ruiz-Villaverde<sup>a,b,\*</sup>

<sup>a</sup> Servicio de Dermatología, Hospital Universitario San Cecilio, Granada, Spain

<sup>b</sup> Instituto de Investigación Biosanitaria ibs.GRANADA, Granada, Spain

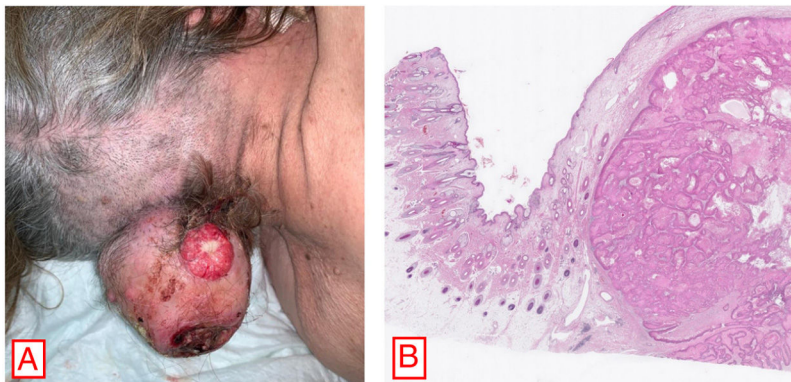


Figure 1

An 86-year-old woman was referred to an outpatient dermatology clinic for a subcutaneous tumor located on the vertex that had grown progressively over the preceding 8 years. Except for occasional bleeding after trauma, the lesion had been completely asymptomatic. Clinical examination revealed a subcutaneous, multilobulated, partially ulcerated tumor of 9 cm × 8 cm in the occipital region of the scalp (Fig. 1A). Examination of the skin and mucosa revealed no alterations. No locoregional adenopathy was detected on palpation. Computed tomography (CT) of the scalp and neck

showed no infiltration of the surrounding subcutaneous tissue or bone involvement. The histologic examination was compatible with a proliferating trichilemmal tumor of the scalp (Fig. 1B). Trichilemmal tumors or pilar cysts are considered cutaneous adnexal tumors that originate in the outer hair root sheath. Histology reveals the absence of a granular layer between the spinous and horny layers. Although it is considered a benign entity, it can sometimes give rise to a proliferating trichilemmal tumor, which in elderly patients must be distinguished from squamous cell carcinoma. Due to its capacity for local invasion, the first line of treatment is complete and wide surgical excision with safety margins.

DOI of original article:

<https://doi.org/10.1016/j.ad.2021.07.009>

\* Corresponding author.

E-mail address: [ismenios@hotmail.com](mailto:ismenios@hotmail.com) (R. Ruiz-Villaverde).

<https://doi.org/10.1016/j.ad.2021.07.017>

0001-7310/© 2021 AEDV. Published by Elsevier España, S.L.U. This is an open access article under the CC BY-NC-ND license (<http://creativecommons.org/licenses/by-nc-nd/4.0/>).