



ACADEMIA ESPAÑOLA  
DE DERMATOLOGÍA  
Y VENEREOLÓGIA

# ACTAS Dermo-Sifiliográficas

Full English text available at  
[www.actasdermo.org](http://www.actasdermo.org)



## CASE AND RESEARCH LETTER

### [Translated article] Oral Ivermectin to Treat Refractory Scabies in Children Weighing Less Than 15 kg: A Report of 4 Cases and Literature Review<sup>☆</sup>



#### Ivermectina oral como tratamiento de la escabiosis refractaria en niños menores de 15 kg. Descripción de cuatro casos y revisión de la literatura

Dear Editor:

Scabies is a highly prevalent parasitic disease that can have a significant impact on quality of life and even lead to serious complications such as streptococcal superinfection and associated kidney damage.<sup>1</sup> In young children treatment consists of topical therapy, although this can be poorly tolerated and treatment adherence is often suboptimal.<sup>2</sup> Ivermectin is a widely used antiparasitic that is effective for the treatment of scabies.<sup>1</sup> Its use is approved in adults and children >15 kg, although recent studies suggest that it may also be safe for lower-weight infants.<sup>2,3</sup>

We describe 4 cases of children weighing less than 15 kg who had scabies refractory to topical therapy and were successfully treated with oral ivermectin (Table 1).

The first patient (age, 16 mo; bodyweight, 8 kg) was referred to our department for nodular scabies. Mite furrows were evident on the feet and wrists. Dermoscopic examination revealed the presence of the delta wing sign (Fig. 1A–C). The patient received two 2-mg doses of ivermectin (250 µg/kg) separated by 7 days. The second patient (age, 13 mo; bodyweight, 13 kg) had a history of atopic dermatitis and was being treated with oral corticosteroids, which were prescribed by the attending pediatrician 2 months earlier. One month earlier the patient had presented

with generalized, scaly erythematous lesions, and had been diagnosed with Norwegian scabies (possibly related to immunosuppression secondary to systemic corticosteroid therapy) and treated with topical permethrin on multiple occasions (Table 1). Direct examination of a scale scraping confirmed the presence of *Sarcoptes scabiei*. The patient received two 3-mg doses of ivermectin (230 µg/kg) separated by 7 days. The third and fourth patients (age, 10 mo and 20 mo; bodyweight, 11 kg and 12 kg) presented with classical scabies lesions, consisting of mite furrows in the skin folds and on the trunk and wrists, as well as itchy vesicles and pustules on the palms and soles. They received two 3-mg doses of ivermectin (270 µg/kg and 250 µg/kg, respectively) separated by 7 days. All 4 cases showed a complete response after 3 weeks, and no adverse effects were observed.

Treatment of scabies in children weighing <15 kg can be complex: topical treatments can be difficult to apply and can cause skin irritation and systemic adverse effects. Ivermectin is an antiparasitic included in the World Health Organization's list of essential drugs, and its efficacy and tolerance for the treatment of scabies are similar to those of topical permethrin.<sup>1</sup> The adverse effects of ivermectin are mostly mild and include dizziness, headache, gastrointestinal symptoms, paresthesia, and eczema.<sup>4</sup>

A recent retrospective multicenter study of 170 children aged 4–64 months, weighing 4–14 kg (31 < 7.5 kg), who were treated with oral ivermectin (mean dose, 223 µg/kg; range, 94–556 µg/kg), reported a therapeutic response in 85% of participants, with minimal adverse effects. Seven patients had eczema and 2 had mild gastrointestinal disturbances. A dose >200 µg/kg and a dose interval <10 days were associated with a higher probability of remission. Although ivermectin was only available in tablet form, the authors reported no difficulties in administering the drug.<sup>2</sup> A systematic review of the literature published in 2018<sup>3</sup> found 9 studies with a total of 61 patients aged <5 years who were treated with ivermectin for various parasites, 24 of whom weighed <15 kg (no information was available on the weight of the other patients, although based on their age many likely weighed <15 kg), and reported a good therapeutic response among scabies patients, with no significant adverse effects. Of particular note is a randomized clinical trial by Brooks et al.<sup>5</sup> of 45 scabies patients aged 1 to 5 years who were treated with a dose of 200 µg/kg. Although the response rate (54%) was lower than that reported in

DOI of original article:

<https://doi.org/10.1016/j.ad.2021.01.007>

<sup>☆</sup> Please cite this article as: Morgado-Carrasco D, Piquero-Casals J, Creus-Vila L, Fustà-Novell X. Ivermectina oral como tratamiento de la escabiosis refractaria en niños menores de 15 kg. Descripción de cuatro casos y revisión de la literatura. Actas Dermosifiliogr. 2022;113:99–103.

<https://doi.org/10.1016/j.ad.2021.01.019>

0001-7310/© 2021 AEDV. Published by Elsevier España, S.L.U. This is an open access article under the CC BY-NC-ND license (<http://creativecommons.org/licenses/by-nc-nd/4.0/>).

**Table 1** Clinical and Epidemiological Characteristics and Therapeutic Response to Oral Ivermectin in Scabies Patients Weighing <15 kg Refractory to Topical Treatment.

Patient	Sex/age, m	Weight, kg	Comorbidities	Clinical presentation	Diagnosis	Prior treatments	Oral ivermectin dose	Concomitant topical treatment	Formulation*	Clinical response	Adverse effects
1	F/16	8	No	Nodular scabies (multiple nodules on the face, trunk, and extremities)	Clinical and dermoscopic (presence of multiple furrows with delta wing sign)	Topical 5% permethrin (8 applications at weekly intervals)	2 mg (0.25 mg/kg) on days 0 and 7 <sup>†</sup>	No	Suspension formulated in the hospital pharmacy using 3-mg tablets	Resolution of clinical picture at 3 wk	No adverse effects
2	M/13	13	Atopic dermatitis treated with oral corticosteroids (indicated by pediatrician)	Norwegian scabies	Clinical, confirmed by direct examination (Muller test)	Topical 5% permethrin (2 applications 1 wk apart)	3 mg (0.23 mg/kg) on days 0 and 7 <sup>†</sup>	Petrolatum	Crushed 3-mg tablet	Resolution of clinical picture at 3 wk	No adverse effects
3	M/10	11	No	Classical scabies (vesicular/pustular lesions on palms and soles)	Clinical and dermoscopic (presence of multiple furrows with delta wing sign)	Topical 5% permethrin (3 cycles of 2 applications at weekly intervals)	3 mg (0.27 mg/kg) on days 0 and 7 <sup>†</sup>	No	Crushed 3-mg tablet	Resolution of clinical picture at 3 wk	No adverse effects
4	F/20	12	No	Classical scabies (vesicular/pustular lesions on palms and soles)	Clinical and dermoscopic (presence of multiple furrows with delta wing sign)	Topical 5% permethrin (6 applications 1 week apart)	3 mg (0.25 mg/kg) on days 0 and 7 <sup>†</sup>	No	Crushed 3-mg tablet	Resolution of clinical picture at 3 wk	No adverse effects

\* Ivermectin was not available as a commercial preparation in Spain at that moment. Nowadays it is commercially available at a 12 mg dose (4 tablets containing 3 mg each).

<sup>†</sup> Parents (all of whom were symptomatic and had previously received topical permethrin treatment without clinical resolution) were prescribed ivermectin (0.2 mg/kg) on days 0 and 7, without associated topical treatment, and achieved complete remission.

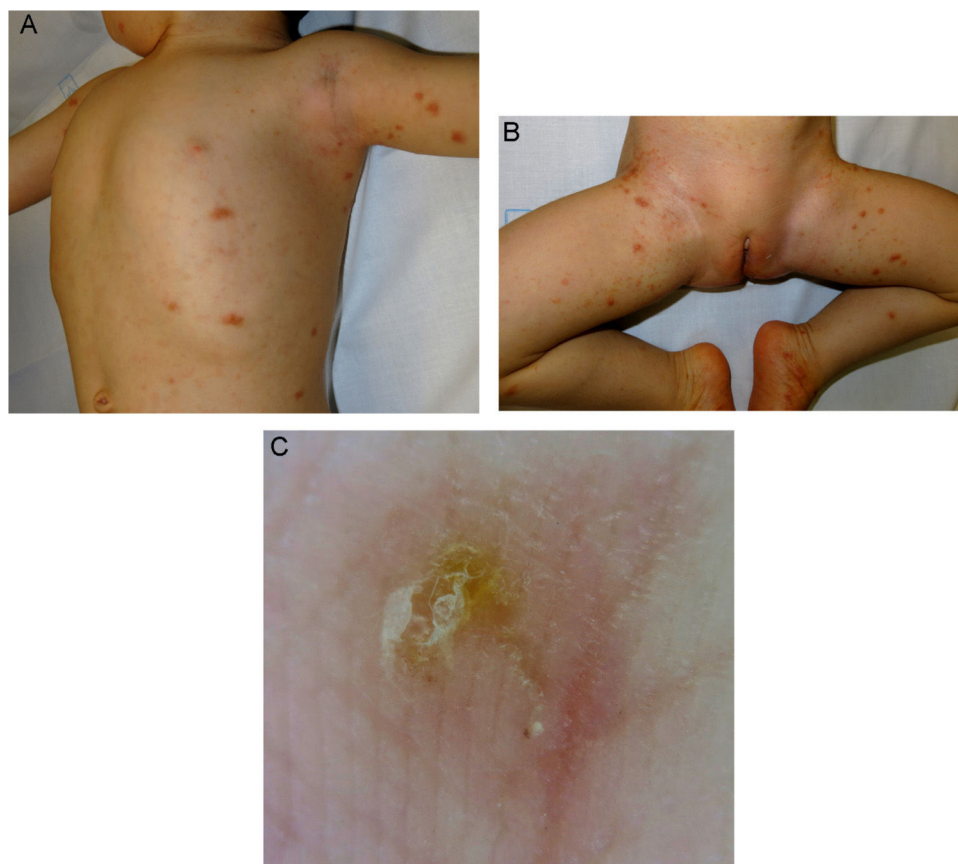
**Table 2** Studies of Oral Ivermectin for the Treatment of Parasitic Diseases in Children Weighing <15 kg\*.

Authors (year)	Type of Study	Children <5 y or <15 kg Bodyweight	Parasitic Disease	Ivermectin Dose	Clinical Response	Adverse Effects
Levy et al. (2020) <sup>2</sup>	Multicenter retrospective	170 children <15 kg bodyweight (age, 4–64 mo)	Scabies	Mean dose, 223 µg/kg (range, 94–556 µg/kg)	Complete response, 85%	Mild. Seven patients had eczema and 2 had gastrointestinal disorders
Romani et al. (2019) <sup>8</sup>	RCT	86 children aged <5 y <sup>†</sup>	Scabies (MDA)	200 µg/kg	Significant decrease in incidence of scabies and impetigo	Not specified
Wimmersberger et al. (2018) <sup>7</sup>	RCT	45 preschool children (mean age, 3.7 y) <sup>†</sup>	<i>Trichuris trichiura</i>	200 µg/kg	20.9% (similar to placebo)	Mild, no visceral toxicity or biochemical alterations
Haar et al. (2014) <sup>9</sup>	Nonrandomized prospective study	9 children <5 y <sup>†</sup>	Scabies (MDA)	200 µg/kg	Significant decrease in prevalence of scabies	No adverse effects were described
Bécourt et al. (2013) <sup>6</sup>	Retrospective study	15 children <15 kg (age, 3–22 mo)	Scabies	200 µg/kg	93% cure	Mild. Irritation was reported in 1 patient and transient intense pruritus in another
del Mar Sáez-De-Ocariz et al. (2002) <sup>10</sup>	Nonrandomized prospective study	7 children <15 kg (age <5 y)	Scabies (5) Larva migrans (2)	150–200 µg/kg	100% complete response	No adverse effects were described
Brooks et al. (2002) <sup>5</sup>	RCT	24 children <5 y <sup>†</sup>	Scabies	200 µg/kg	54% complete response	Mild. Pustular eruption in 8% of patients

Abbreviations: MDA, mass drug administration (i.e. treatment of all individuals in a community regardless of their status [scabies patients or contacts thereof]); RCT, randomized clinical trial.

\* Descriptions of individual cases not included.

† Study does not specify bodyweight of children, but based on their ages it is very likely that they weighed <15 kg.



**Figure 1** Nodular scabies. Multiple erythematous papules and nodules on the trunk and arms (A) and the lower extremities (B). C, Dermoscopy of a mite furrow on the right foot revealing the delta wing sign.

children who received 2 doses,<sup>1,2</sup> no moderate or serious adverse effects were observed. Bécourt et al.<sup>6</sup> conducted a retrospective study with 15 children weighing <15 kg (age, 3–22 mo) with scabies who were treated with 2 doses of oral ivermectin. A complete response was observed in 93% of patients, and adverse effects were both minimal and transient. A randomized clinical trial (not included in the aforementioned systematic review) evaluated the efficacy of oral ivermectin (200 µg/kg) for the treatment of the parasite *Trichuris trichiura* in 45 preschool children (mean age, 3.7 y).<sup>7</sup> The treatment was not effective, but was well tolerated, resulting in only mild adverse effects (Table 2). Laboratory studies performed at baseline and 72 hours after ivermectin treatment revealed no instances of anemia, plateletopenia, neutropenia, renal failure, or liver function alterations.

Several recent studies evaluating mass drug administration (MDA), which involves the treatment of all individuals in a community regardless of their status (scabies patients or contacts thereof) have reported encouraging findings in patients with distinct infections and infestations. One clinical trial compared 3 scabies treatment arms: oral ivermectin MDA (including 86 children <5 y), topical permethrin MDA, and standard topical permethrin therapy of scabies patients and their contacts. Evaluation of the 823 participants after 24 months revealed that the prevalence of scabies and impetigo were significantly lower in the oral ivermectin MDA arm. The incidence of adverse effects was not reported.<sup>8</sup>

Since mid-2021, oral ivermectin has been commercially available in Spain (Ivergalen, Galenicum Derma) at a dose of 12-mg (four 3-mg tablets), facilitating prescribing of this drug.

Oral ivermectin appears to be well tolerated in children weighing <15 kg with scabies. Randomized clinical trials are a priority given the high prevalence of various parasites at this age and the good results obtained with MDA of this drug.

## Funding

This work has not received any type of funding.

## Conflicts of interest

The authors declare that they have no conflicts of interest.

## References

1. Rosumeck S, Nast A, Dressler C. Evaluation of Ivermectin vs Permethrin for Treating Scabies-Summary of a Cochrane Review. *JAMA Dermatol.* 2019;155:730–2.
2. Levy M, Martin L, Bursztejn A-C, Chiaverini C, Miquel J, Mahé E, et al. Ivermectin safety in infants and children under 15 kg treated for scabies: a multicentric observational study. *Br J Dermatol.* 2020;182:1003–6.

3. Wilkins AL, Steer AC, Cranswick N, Gwee A. Question 1: Is it safe to use ivermectin in children less than five years of age and weighing less than 15 kg? Arch Dis Child. 2018;103:514–9.
4. Sanz-Navarro J, Feal C, Dauden E. Treatment of Human Scabies with Oral Ivermectin. Eczematous Eruptions as a New Non-Reported Adverse Event. Actas Dermosifiliogr. 2017;108:643–9.
5. Brooks PA, Grace RF. Ivermectin is better than benzyl benzoate for childhood scabies in developing countries. J Paediatr Child Health. 2002;38:401–4.
6. Bécourt C, Marguet C, Balguerie X, Joly P. Treatment of scabies with oral ivermectin in 15 infants: a retrospective study on tolerance and efficacy. Br J Dermatol. 2013;169:931–3.
7. Wimmersberger D, Coulibaly JT, Schulz JD, Puchkow M, Huwyler J, N’Gbeso Y, et al. Efficacy and Safety of Ivermectin Against Trichuris trichiura in Preschool-aged and School-aged Children: A Randomized Controlled Dose-finding Trial. Clin Infect Dis Off Publ Infect Dis Soc Am. 2018;67:1247–55.
8. Romani L, Whitfeld MJ, Koroivueta J, Kama M, Wand H, Tikod-uadua L, et al. Mass Drug Administration for Scabies - 2 Years of Follow-up. N Engl J Med. 2019;381:186–7.
9. Haar K, Romani L, Filimone R, Kishore K, Tuicakau M, Koroivueta J, et al. Scabies community prevalence and mass drug administration in two Fijian villages. Int J Dermatol. 2014;53:739–45.
10. del Mar Sáez-De-Ocariz M, McKinster CD, Orozco-Covarrubias L, Tamayo-Sánchez L, Ruiz-Maldonado R. Treatment of 18 children with scabies or cutaneous larva migrans using ivermectin. Clin Exp Dermatol. 2002;27:264–7.

D. Morgado-Carrasco<sup>a,\*</sup>, J. Piquero-Casals<sup>b</sup>, L. Creus-Vila<sup>c</sup>, X. Fustà-Novell<sup>c</sup>

<sup>a</sup> Servicio de Dermatología, Hospital de Figueres Fundació Salut Empordà, Spain

<sup>b</sup> Dermik, Clínica Dermatológica Multidisciplinar, Barcelona, Spain

<sup>c</sup> Servicio de Dermatología, Althaia, Xarxa Assistencial Universitària de Manresa, Barcelona, Spain

Corresponding author.

E-mail address: [morgadodaniel8@gmail.com](mailto:morgadodaniel8@gmail.com) (D. Morgado-Carrasco).