



# ACTAS Derma-Sifiliográficas

Full English text available at  
www.actasdermo.org



## CASE AND RESEARCH LETTERS

### Atypical Ulcerated Lesions in a Patient With Cogan Syndrome



#### Lesiones ulcerativas atípicas en un paciente con síndrome de Cogan

Dear Editor

Cogan syndrome (CS) is a rare vasculitis characterized by recurrent interstitial keratitis and audiovestibular symptoms including hearing loss, tinnitus, and vertigo. To date, cutaneous lesions have been only rarely described associated with this autoimmune disease.<sup>1</sup> We present the case of a patient with CS and multiple ulcerated lesions.

A 39-year-old white Spanish woman diagnosed with CS at age 31 years, with stromal keratitis and severe bilateral hearing loss, consulted for a 2-week history of ulcers that had started as pustules on the legs and then spread to the thighs, arms, abdomen, and back. At the time of onset, the patient was on treatment with methotrexate (25 mg/wk), prednisone (10 mg/d), and tozilizumab (8 mg/kg/mo). Physical examination revealed numerous pustules and ulcerated necrotic lesions on the legs, thighs, arms, back, and abdomen (Fig. 1A). On suspicion of ecthyma, topical antibiotics and oral cloxacillin were prescribed. Smear cultures for bacteria, fungi, and mycobacteria were all negative. Additional tests were within normal limits and the chest radiograph was normal. Two weeks later the patient presented further pustules and enlargement of those previously present. At no time did she report fever or malaise. Histopathology of a biopsy from an ulcer on the left thigh revealed an ulcerated epidermis with epidermal necrosis and pustules at the border, with an abscessified area of skin and a diffuse dermal inflammatory infiltrate formed by neutrophils, histiocytes, lymphocytes, and occasional multinucleated giant cells (Fig. 2A and B). No clear signs of vasculitis were observed. Immunofluorescence was negative. Bacterial cultures from the cutaneous biopsy and new smears were positive for *Pseudomonas aeruginosa*/*Staphylococcus haemolyticus*, and *Streptococcus pyogenes*/*Pseudomonas putida fluorescens*, respectively. Oral cefuroxime and ciprofloxacin were started but the lesions showed no improvement. It was then that prednisone (at a dose of up to 1 mg/kg/d) was prescribed. The patient responded favorably, and in 2 weeks the lesions had completely re-epithelized except for an ulcer in the surgical wound of the biopsy and a linear ulcer on the

left arm that had developed after trauma a week earlier, suggesting a pathergy phenomenon (Fig. 1B). At follow-up, no lesions were observed. At the time of writing, the patient remains asymptomatic and continues her usual therapy.

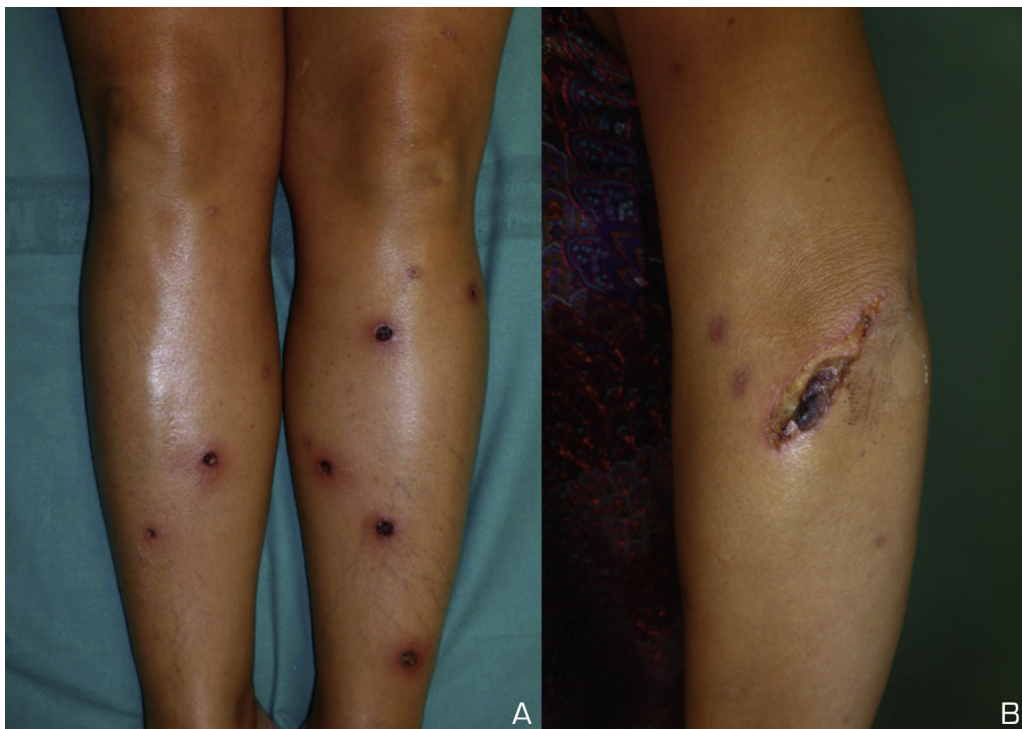
Diagnosis of the cutaneous lesions in our patient was difficult, and ecthyma was our initial provisional diagnosis. The lack of response—and even a deterioration—of the lesions after antibiotic therapy, the pathergy phenomenon, and the favorable response to steroids led us to consider a pyoderma gangrenosum (PG)-like neutrophilic dermatosis. However, the multiple lesions and the histopathology were not conclusive for either PG or other forms of neutrophilic dermatosis. Multiple lesions have rarely been described in PG.<sup>2</sup> In 70% of cases, PG is associated with an underlying disease such as inflammatory bowel disease (IBD), inflammatory arthritis, or a hematologic malignancy.<sup>3–5</sup>

Tirelli et al.<sup>6</sup> found about 250 reports of patients with CS, only 13 of whom had concomitant chronic IBD; of these, none experienced improvement after therapy.

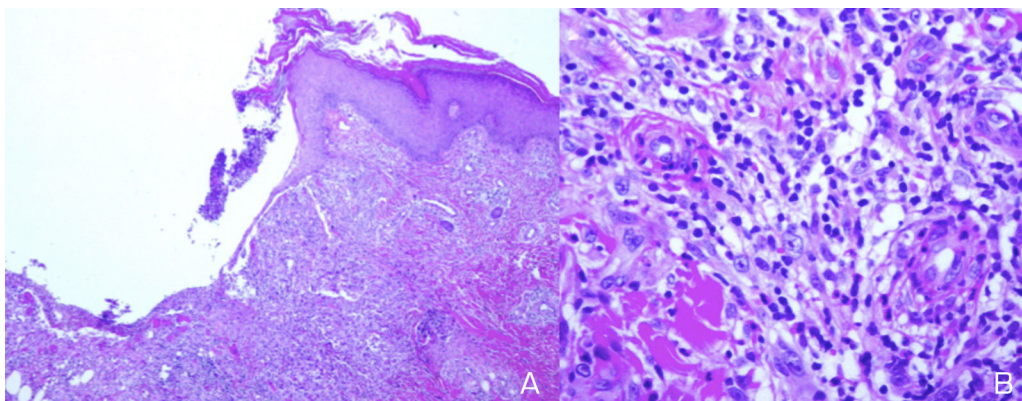
The etiology and pathogenesis of CS are unknown. Initially, the disease was thought to be caused by an infection, but it is now considered to be an autoimmune disorder.<sup>7</sup> In addition to the ocular and audiovestibular involvement, numerous systemic manifestations have been reported in CS, most commonly of cardiovascular, neurological, or gastrointestinal origin. Approximately 70% of patients have an underlying systemic disease. Vasculitis is considered to be the pathological mechanism<sup>8</sup>; however, even though swollen endothelial cells and focal fibrinoid deposits were seen in the biopsy from our patient, it was not possible to make a conclusive diagnosis of cutaneous vasculitis.

In a review of the literature, we have found that CS has rarely been associated with skin manifestations, and in most cases such manifestations are reported as rash or ulcers, with no further detailed clinical description or histopathology study. In a multicenter study that included 32 patients with CS, only 7 showed skin and mucous membrane involvement or chondritis: 3 cases of rash, with evidence of vasculitis in only 2 of them, 1 patient with photosensitivity, 1 with vitiligo, 2 with oral ulcers and 2 with chondritis.<sup>9</sup> Pagnini et al.<sup>1</sup> described 23 children with CS; only 3 presented skin manifestations, all of which were described as rashes. As far as we are aware, these multiple ulcerated necrotic lesions have not previously been described in association with CS.

In summary, we have described an unusual case of multiple ulcerated necrotic lesions in a patient with CS.



**Figure 1** (A) Ulcerated necrotic lesions on both lower legs. (B) Linear ulcer on the left arm exhibiting the pathergy phenomenon.



**Figure 2** (A) Ulcerated epidermis with a diffuse inflammatory infiltrate in the dermis. (B) Infiltrates formed of neutrophils, histiocytes, lymphocytes, and occasional multinucleated giant cells.

### Conflict of interests

The authors declare no conflict of interests.

### References

- Pagnini I, Zannin ME, Vittadello F, Sari M, Simonini G, Cimaz R, et al. Clinical features and outcome of Cogan syndrome. *J Pediatr.* 2012;160:303–7.
- Ye MJ, Ye JM. Pyoderma gangrenosum: a review of clinical features and outcomes of 23 cases requiring inpatient management. *Dermatol Res Pract.* 2014;2014:461467.
- Dasanu CA, Bockorny B, Alexandrescu DT. Pyoderma gangrenosum due to lenalidomide use for multiple myeloma. *J Oncol Pharm Pract.* 2014, pii:1078155214541975.
- Greenstein AJ, Janowitz HD, Sachar DB. The extraintestinal complications of Crohn's disease and ulcerative colitis: a study of 700 patients. *Medicine (Baltimore).* 1976;55:401–12.
- Perry HO, Winkelmann RK. Bullous pyoderma gangrenosum and leukemia. *Arch Dermatol.* 1972;106:901–5.
- Tirelli G, Tomietto P, Quatela E, Perrino F, Nicastro L, Cattin L, et al. Sudden hearing loss and Crohn disease: when Cogan syndrome must be suspected. *Am J Otolaryngol.* 2015;36: 590–7.
- Greco A, Gallo A, Fusconi M, Magliulo G, Turchetta R, Marinelli C, et al. Cogan's syndrome: an autoimmune inner ear disease. *Autoimmun Rev.* 2013;12:396–400.
- Cheson BD, Bluming AZ, Aloy J. Cogan's syndrome: a systemic vasculitis. *Am J Med.* 1976;60:549–55.
- Grasland A, Pouchot J, Hachulla E, Blétry O, Papo T, Vinceneux P. Typical and atypical Cogan's syndrome: 32 cases and review of the literature. *Rheumatology.* 2004;43:1007–15.

G. Solano-López<sup>a,\*</sup>, A. Montes-Torres<sup>a</sup>, E. Tomero<sup>b</sup>,  
J. Fraga<sup>c</sup>, D. De Argila<sup>a</sup>, E. Daudén<sup>a</sup>

<sup>a</sup> *Department of Dermatology, Hospital Universitario de la Princesa, Madrid, Spain*

<sup>b</sup> *Department of Rheumatology, Hospital Universitario de la Princesa, Madrid, Spain*

<sup>c</sup> *Department of Pathology, Hospital Universitario de la Princesa, Madrid, Spain*

\*Corresponding author.

E-mail address: [guitje1@hotmail.com](mailto:guitje1@hotmail.com) (G. Solano-López).

<http://dx.doi.org/10.1016/j.ad.2016.10.017>

0001-7310/

© 2016 AEDV. Published by Elsevier España, S.L.U. All rights reserved.

## Estudio piloto de valoración de dehiscencias posquirúrgicas tras sutura continua por planos



### Pilot Study to Evaluate Postsurgical Dehiscence After Continuous Suture by Tissue Planes

Sra. Directora:

El objetivo principal de la cirugía oncológica dermatológica es la extirpación del tumor con márgenes de seguridad suficientes que permitan una correcta monitorización posterior. No obstante, conseguir el mejor resultado, tanto funcional como estético, es un objetivo secundario al que cada día se concede mayor importancia, y que incluso se ha trasladado a la exéresis de lesiones benignas, muchas de ellas no cubiertas en la cartera de servicios de numerosos hospitales<sup>1</sup>.

Existen diferentes técnicas quirúrgicas para evitar la dehiscencia de la herida en el postoperatorio inmediato y posteriormente en el postoperatorio tardío. La técnica clásica que mejores resultados ha aportado ha sido la descrita por Weber y Wulc<sup>2</sup> en 1992. Esta técnica ha sido posteriormente modificada y mejorada por Serrano et al.<sup>3</sup> en 2015, consiguiendo que no se notasen los orificios de entrada y salida del hilo de sutura mediante la realización de la sutura oblicua subcutánea en todo su trayecto, enterrándola por tanto de forma completa.

En línea con la idea desarrollada por Serrano<sup>3</sup>, para evitar la dehiscencia de la herida y posteriormente de la cicatriz, realizamos una «sutura continua por planos»<sup>4</sup>, que consiste en una sutura subcutánea continua seguida de una sutura intradérmica, y cuya técnica se expuso previamente en la sección de vídeos quirúrgicos de ACTAS DERMOSIFILIOGRÁFICAS.

Con esta técnica mantenemos controladas las fuerzas de tensión hasta que la herida ha cicatrizado, siendo una técnica ágil y sencilla. No es necesario retirar el material de sutura. Para la sutura utilizamos un material reabsorbible a medio plazo para evitar la formación de granulomas a cuerpo extraño que se pueden producir al usar sutura no reabsorbible (Novosyn<sup>®</sup>, 3/0 una sutura sintética absorbible a medio plazo, de 90/10 poli —glicólico-co-L-láctido—, multifibrilar, trenzada e impregnada). Dos ventajas adicionales de esta técnica son la rapidez en su ejecución y el no necesitar de ayudante para ir cortando el material de sutura tras cada punto<sup>5</sup>.

Para determinar la dehiscencia producida en el postoperatorio inmediato y a medio plazo con la técnica mencionada y la realizada mediante cirugía convencional, realizamos en nuestra unidad un estudio piloto prospectivo no aleatorizado entre enero y diciembre de 2015. Este estudio fue aprobado por el comité ético de nuestro hospital. Todos los pacientes incluidos eran mayores de 18 años. Como variables se recogieron sexo, edad, diagnóstico clínico, longitud y anchura del ojal de incisión y anchura de la dehiscencia a los 3 y 6 meses respectivamente. Todas las lesiones extirpadas se localizaron en el tronco y en la raíz de los miembros inferiores.

Realizamos un análisis descriptivo global y por grupos a través de un análisis de normalidad de las variables cuantitativas continuas mediante la prueba de Kolmogorov-Smirnov, empleando para comparar estas variables el test «t» de Student o el test de Welch en las variables normales y el test U de Mann Whitney en las no normales. Asimismo, se empleó el test de Chi cuadrado para estudiar la asociación entre variables cualitativas. Se recogieron 65 pacientes, 37 intervenidos mediante sutura continua por planos y 28 con la técnica clásica de Weber (tabla 1). No se encontraron diferencias estadísticamente significativas en las variables edad, sexo, longitud y anchura del ojal entre ambos grupos. Los pacientes intervenidos mediante la sutura continua por planos presentaron una dehiscencia media de 4,88 mm, mientras que la dehiscencia media en el grupo de la sutura clásica fue de 7,25 mm, siendo la diferencia entre ambas medias estadísticamente significativa ( $p=0,002$ ).

En ninguna de las 2 técnicas se experimentó complicaciones de tipo infeccioso en el postoperatorio inmediato ni tardío tras seguir de forma estricta los protocolos de verificación pre y posquirúrgica realizados en nuestro centro<sup>6</sup>.

**Tabla 1** Comparativa de las 2 técnicas de sutura realizadas en los pacientes de nuestro estudio

	Continua por planos	Clásica	p
Edad	54,66 ± 19,93	50,67 ± 15,94	0,381
Sexo			0,880
V	23	13	
M	18	11	
Dehiscencia (cm)	0,49 ± 0,29	0,73 ± 0,27	0,002
Longitud ojal (cm)	4,48 ± 1,32	4,01 ± 1,48	0,203
Anchura ojal (cm)	2,19 ± 1,01	2,54 ± 1,18	0,251