

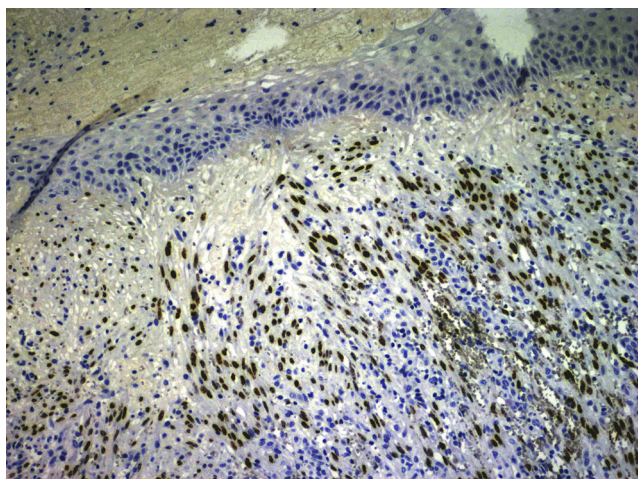Figure 3 Nuclear positivity for human herpes virus 8 (hematoxylin-eosin staining, original magnification $\times 20$).

in the literature are elderly, with the exception of a healthy 36-year-old white man. We do not know why certain vascular proliferations, such as angiolymphoid hyperplasia with eosinophilia, have a special predilection for the pinna, but we hypothesize that the sum of certain traumatic/infectious factors in an acral area with complex, fine, and insufficient vascularization could make access difficult for immune cells. All these conditions could favor the occurrence of these vascular tumors in certain individuals with immune dysfunction that has not been adequately studied. We highlight the importance of contemplating KS in the differential diagnosis of tumors with a vascular appearance involving the ears in immunologically competent individuals.

Conflict of interests

The authors declare no conflict of interest.

Bibliografía

1. Chang Y, Moore P. Twenty years of KSHV. *Viruses*. 2014;6:4258–64.
2. Rashidghamat E, Bunker CB, Bower M, Banerjee P. Kaposi sarcoma in HIV-negative men who have sex with men. *Br J Dermatol*. 2014;171:1267–8.
3. Naunton RF, Stoller FM. Kaposi's sarcoma of the auricle. *Laryngoscope*. 1960;70:1535–40.
4. Gibbs RC. Kaposi's sarcoma involving the ears. *Arch Dermatol*. 1968;98:104–5.
5. Stearns MP, Hibbard AA, Patterson HC. Kaposi's sarcoma of the ear: a case study. *J Laryngol Otol*. 1983;97:641–5.
6. Babuccu O, Kargi E, Hoşnüter M, Doğan BG. Atypical presentation of Kaposi's sarcoma in the external ear. *Kulak Burun Bogaz Ihtis Derg*. 2003;11:17–20.
7. Colletti G, Allevi F, Moneghini L, Rabbiosi D. Bilateral auricular classic Kaposi's sarcoma. *BMJ Case Rep*. 2013;6:2013.
8. Izquierdo Cuenca M, Pérez Ortín M, Gómez Martín-Zarco JM. *Acta Otorrinolaringol Esp*. 2013;64:448.
9. Busi M, Altieri E, Ciorba A, Aimoni C. Auricular involvement of a multifocal non-AIDS Kaposi's sarcoma: a case report. *Acta Otorhinolaryngol Ital*. 2014;34:146–9.

L. Francés Rodríguez^{a,*}, A. Bouret Lebrón^a,
C. Muñoz Ruíz^b, J. Bañuls Roca^{a,c}

^a *Dermatology Department, Hospital General Universitario de Alicante, Instituto de Investigación Sanitaria y Biomédica de Alicante (Isabial), Alicante, Spain*

^b *Immunology Department, Hospital General Universitario de Alicante, Instituto de Investigación Sanitaria y Biomédica de Alicante (Isabial), Alicante, Spain*

^c *Medicina Clínica Department, Dermatology Area, Miguel Hernández University, Sant Joan D'Alacant, Alicante, Spain*

* Corresponding author.

E-mail address: frances.rodriquez.laura@gmail.com
(L. Francés Rodríguez).

<http://dx.doi.org/10.1016/j.ad.2016.05.008>

Patient with disseminated tuberculosis and rare perianal involvement



Paciente con tuberculosis diseminada y un raro compromiso perianal

Dear Editor

Case description

A 59-year-old homeless male patient presented to the emergency department with a 3-month history of a rapidly enlarging, painful perianal mass associated with rectal bleeding. He also reported nocturnal sweats, fever, weight loss, and a chronic productive cough. The patient had no past medical history of note and was not on any medication, but he was a smoker and consumed marijuana on a daily

basis. He stated that he had unprotected sex with occasional women, but denied anal sex.

On inspection, the patient was cachectic, with a weight of 45 kg. Physical examination revealed numerous enlarged cervical lymph nodes, some measuring over a centimeter in diameter, and chest auscultation was abnormal. In the perianal area, multiple skin-colored nodules had coalesced into a larger mass associated with a well-defined, indurated, painful, hemorrhagic perianal ulcer (Fig. 1). Serology for HIV and hepatitis was negative, and kidney and liver function was normal. Chest X-ray and high-resolution computed tomography revealed widespread reticulonodular opacities in both lung fields (Fig. 2). Sputum bacilloscopy was positive for acid-alcohol-fast bacilli, confirming the diagnosis of active pulmonary tuberculosis. The GeneXpert MTB/RIF test on material from a biopsy of a cervical lymph node was positive for *Mycobacterium tuberculosis* DNA. On colonoscopy an isolated ulcer with positive bacilloscopy for acid-alcohol-fast bacilli was discovered in the cecum. Biopsy of the

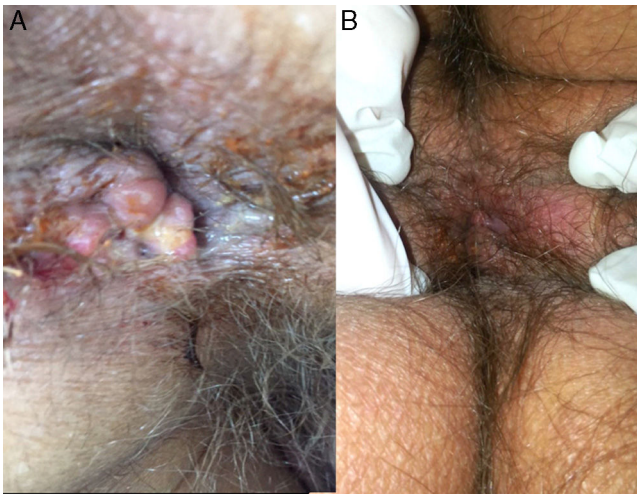


Figure 1 Clinical image of the perianal lesion. (A) Prior to diagnosis. (B) After 2 months of treatment.

perianal lesion revealed caseous necrosis and a granulomatous inflammatory process with positive bacilloscopy for acid-alcohol-fast bacilli and a GeneXpert MTB/RIF test that was positive for *M. tuberculosis* DNA, with a negative rifampicin resistance test (Fig. 3). Based on this information we made a diagnosis of disseminated tuberculosis (TB) with pulmonary, lymph node, intestinal, and perianal involvement. The patient started treatment with rifampicin, isoniazid, pyrazinamide, and ethambutol daily for 2 months, followed by rifampicin and isoniazid 3 times a week for 7 months (total treatment duration, 9 months). A good response was achieved after completing the first phase, with a decrease in the size of the perianal lesion (Fig. 1) and resolution of the systemic symptoms.

Discussion

M. tuberculosis is an aerobic gram-positive bacillus that is a member of mycobacterium tuberculosis complex. Approximately 2 billion people, a third of the world’s population, are infected by *M. tuberculosis*. Nine million new cases of active

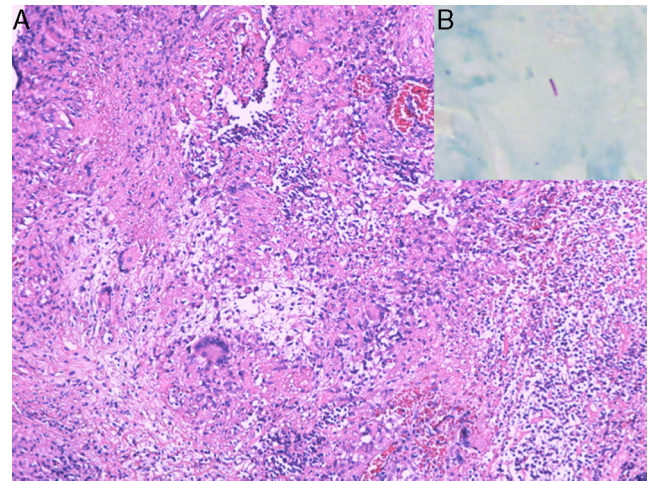


Figure 3 (A) Biopsy of the perianal lesion showing caseous necrosis and a granulomatous inflammatory process. Hematoxylin and eosin, original magnification $\times 40$. (B) Positive bacilloscopy for acid-alcohol-fast bacilli.

TB occur worldwide each year, leading to about 1.8 million deaths annually. The global incidence increased up to the year 2003, since which time there has been a slight fall. The incidence in Colombia is 25–35 cases per 100,000 people, this corresponds to a intermediate incidence in comparison to African countries, where 100–300 cases per 100,000 have been reported.¹

Extrapulmonary TB occurs in 15% of cases and can be the result of primary or reactivated TB. The organs the most commonly affected are the lymph nodes (40%), pleura (20%), urinary tract (15%), bone (10%), central nervous system (5%), and heart (3%). Multiple risk factors have been established for primary and disseminated TB, the most important of which are HIV infection (relative risk [RR], 30), hemodialysis (RR, 20), transplant (RR, 20), intravenous drugs abuse (RR, 20), and infection in the previous year (RR, 13).² A study on mortality in TB patients in Medellín, Colombia, detected social risk factors such as homelessness, drug addiction, or having no fixed address, in 58.1%.³

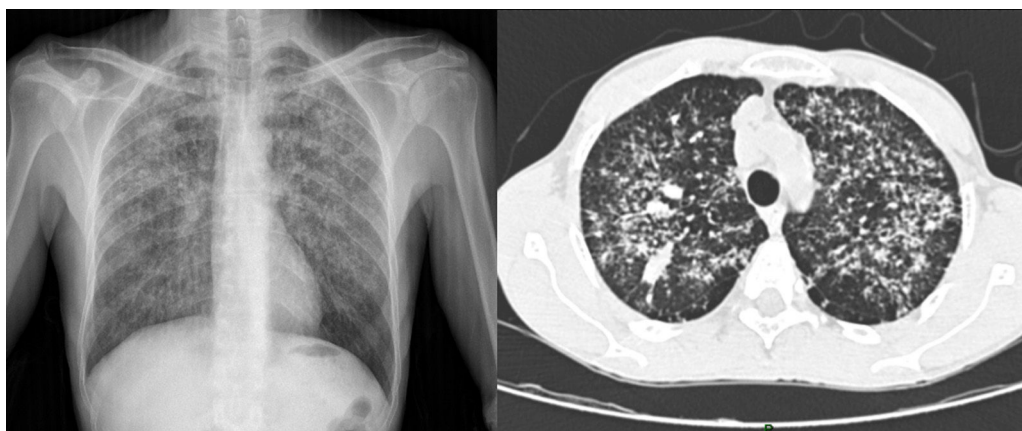

Figure 2 Chest X-ray and high-resolution computed tomography showing widespread bilateral reticulonodular opacities.

Gastrointestinal tract and skin involvement are very rare and have been reported in less than 1% of cases of extrapulmonary TB. Gastrointestinal TB can affect any organ of the digestive tract, but peritonitis is the most common presentation. When the intestine is compromised the infection is localized at the ileocecal valve in 85% of cases.⁴ Anal TB is a very rare condition, occurring in less than 1% of intestinal TB and in less than 0.0015% of all cases of TB. In 2008, Mathew et al.⁵ described the case of an 80-year-old patient with anal TB and reported that only 3 cases have been published in the United Kingdom. Perianal TB is categorized as periorificial cutaneous tuberculosis or tuberculosis cutis orificialis. It accounts for approximately 2% of cases of cutaneous TB. Tuberculosis cutis orificialis results from self-inoculation of *M. tuberculosis* into the periorificial oropharyngeal, anal, or genital mucosa from an initial pulmonary, intestinal, or genitourinary infection. Bacilli may reach the perianal area by hematogenous dissemination or by swallowing infected sputum. Numerous forms of anal TB have been described. The most common presentation is as an ulcerated lesion; fissures, verrucous forms, and masses have been reported in fewer cases. In 2009, Antonello et al.⁶ described the case of a 40-year-old HIV-positive patient with perianal TB that presented as an ulcerating mass, a compound lesion very similar to the finding in our patient. The patient presented by Cheon et al.⁷ in 2013 was a 46 year-old man diagnosed with Crohn disease 30 years earlier and treated with mesalazine with no improvement of his rectal ulcers. Anal TB was diagnosed and the patient presented a marked improvement after 3 months of treatment. Another case of anal TB was reported in a 42-year-old patient on Adalimumab therapy for psoriatic arthritis.⁸

The treatment of anal TB is the same as for other forms of extrapulmonary TB. Patients should receive rifampicin, isoniazid, pyrazinamide, and ethambutol daily for 2 months, followed by rifampicin and isoniazid 3 times a week for 7 months (total treatment time, 9 months).⁹ In order to prevent the appearance of active tuberculosis, the Centers for Disease Control and Prevention advocates targeted screening and treatment of latent tuberculosis infection with 9 months of isoniazid. A newer regimen of weekly combined therapy with isoniazid and rifapentine for 12 weeks was cost-effective in directly observed therapy programs, particularly for populations that would not otherwise complete therapy and are at high risk for conversion to active disease, such as homeless patients.¹⁰

Conflict of interests

The authors declare no conflict of interest.

Bibliografía

1. Zumla A, George A, Sharma V, Herbert RHN, Oxley A, Oliver M. The WHO 2014 global tuberculosis report—further to go. *Lancet Glob Health*. 2015;3:e10–2.
2. Zumla A, Raviglione M, Hafner R, von Reyn CF. Tuberculosis. *N Engl J Med*. 2013;368:745–55.
3. Villa L, Trompa IM, Montes FN, Gómez JG, Restrepo CA. Analysis of mortality caused by tuberculosis in Medellín, Colombia, 2012. *Biomédica*. 2014;34:425–32.
4. Lee J, Lim JK, Seo H, Lee SYSY, Choi KJ, Yoo SS, et al. Clinical relevance of ground glass opacity in 105 patients with miliary tuberculosis. *Respir Med*. 2014;108:924–30.
5. Mathew S. Anal tuberculosis: report of a case and review of literature. *Int J Surg*. 2008;6:e36–9.
6. Antonello VS, Hoff LS, Kaercher D Jr, Santos BR. Anoperineal tuberculosis in an HIV patient. *Braz J Infect Dis*. 2009;13:246–7.
7. Cheon JH, Moon W, Park SJ, Park MI, Kim SE, Choi YJ, et al. A case of intestinal tuberculosis with perianal fistula diagnosed after 30 years. *Korean J Gastroenterol*. 2013;62:370–4.
8. Luquín N, Masiá M, Noguera R, Gutiérrez F. Anal tuberculosis complicating anti-TNF α therapy. *BMJ Case Rep*. 2014:2014.
9. World Health Organization. Treatment of extrapulmonary TB and of TB in special situations. In: *Treatment of tuberculosis guidelines*. Switzerland: World Health Organization; 2010. p. 95–7.
10. Gupta V, Sugg N, Butners M, Allen-White G, Molnar A. Tuberculosis among the homeless—preventing another outbreak through community action. *N Engl J Med*. 2015;372:1483–5.

E. Uribe-Bojanini^{a,*}, C. Santa-Vélez^{a,b}, A. Ruiz-Suarez^c, N. Buchely-Ibarra^c

^a *Dermatology Department, Universidad CES, Medellín, Colombia*

^b *Hospital General de Medellín, Medellín, Colombia*

^c *Dermatopathology Department, Universidad CES, Medellín, Colombia*

* Corresponding author.

E-mail address: uribe.esteban@uces.edu.co (E. Uribe-Bojanini).

<http://dx.doi.org/10.1016/j.ad.2016.05.018>

Cutaneous Sarcoid with Livedoid Changes in a Patient with Hashimoto's Thyroiditis



Sarcoidosis cutánea con cambios livedoides en un paciente con tiroiditis de Hashimoto

Dear Editor:

Association of sarcoidosis and autoimmune thyroiditis is rare. We report a case of cutaneous sarcoid surrounded by

livedo on the lower extremities in a patient with Hashimoto's thyroiditis.

A 72-year-old female visited the Department of Dermatology of Hoshi General Hospital, complaining of asymptomatic reddish eruptions on the lower extremities which appeared six months previously. She had Hashimoto's thyroiditis for several years, but had been followed without medications. Physical examination showed multiple reddish, infiltrative round and irregular-shaped, up to 4-cm sized plaques on the anterior aspects of the bilateral thighs and lower legs (Fig. 1a). The erythematous plaques coalesced on the left thigh, and livedo was observed in the surround-