

ellos, en el que se aplicó clobetasol al 0,5% en crema, 2 veces al día, durante unas pocas semanas<sup>7,9</sup>.

En conclusión, se presenta un nuevo caso de acantoma de células claras en una localización rara como es la areola y el pezón. Hay que resaltar la necesidad de incluir esta entidad en el diagnóstico diferencial de las lesiones eczematosas persistentes del pezón. La remisión observada con corticoide tópico potente es un dato más a favor de que el acantoma de células claras podría tratarse de un proceso reactivo de la epidermis.

## Conflicto de intereses

Los autores declaran no tener ningún conflicto de intereses.

## Bibliografía

1. Degos R, Delort J, Civatte J, Polares Baptista A. Epidermal tumor with an unusual appearance: Clear cell acanthoma [Article in French]. *Ann Dermatol Syphiliogr (Paris)*. 1962;89:361–71.
2. Tempark T, Shwayder T. Clear cell acanthoma. *Clin Exp Dermatol*. 2012;37:831–7.
3. Fukushiro S, Takei Y, Ackermann AB. Pale-cell acanthosis. A distinctive histologic pattern of epidermal epithelium. *Am J Dermatopathol*. 1985;7:515–27.
4. García-Gavín J, González-Vilas D, Montero I, Rodríguez-Pazos L, Pereiro MM, Toribio J. Disseminated eruptive clear cell

acanthoma with spontaneous regression: Further evidence of an inflammatory origin? *Am J Dermatopathol*. 2011;33:599–602.

5. Kim DH, Kim CW, Kang SJ, Kim TY. A case of clear cell acanthoma presenting as nipple eczema. *Br J Dermatol*. 1999;141:950–1.
6. Um SH, Oh CW. Three cases of clear cell acanthoma on nipple and areola. *Korean J Dermatol*. 2003;41:85–8.
7. Nazzaro G, Cogi A, Gianotti R. A 26-year-old man with an eczematous lesion on the nipple. *Arch Dermatol*. 2012;148:641–6.
8. Park SY, Jung JY, Na JI, Byun HJ, Cho KH. A case of polypoid clear cell acanthoma on the nipple. *Ann Dermatol*. 2010;22:337–40.
9. Veiga RR, Barros RS, Santos JE, Abreu Junior JM, Bittencourt MdeJ, Miranda MF. Clear cell acanthoma of the areola and nipple: Clinical, histopathological, and immunohistochemical features of two Brazilian cases. *An Bras Dermatol*. 2013;88:84–9.

Y. Hidalgo-García<sup>a,\*</sup>, P. Gonzálvo<sup>b</sup>, S. Mallo-García<sup>a</sup> y C. Fernández-Sánchez<sup>a</sup>

<sup>a</sup> Servicio de Dermatología, Hospital de Cabueñes, Gijón, Asturias, España

<sup>b</sup> Servicio de Anatomía Patológica, Hospital de Cabueñes, Gijón, Asturias, España

\* Autor para correspondencia.

Correo electrónico: [yhidalgog@yahoo.es](mailto:yhidalgog@yahoo.es) (Y. Hidalgo-García).

<http://dx.doi.org/10.1016/j.ad.2016.04.008>

## Leukocytoclastic vasculitis related to cocaine-adulterated levamisole



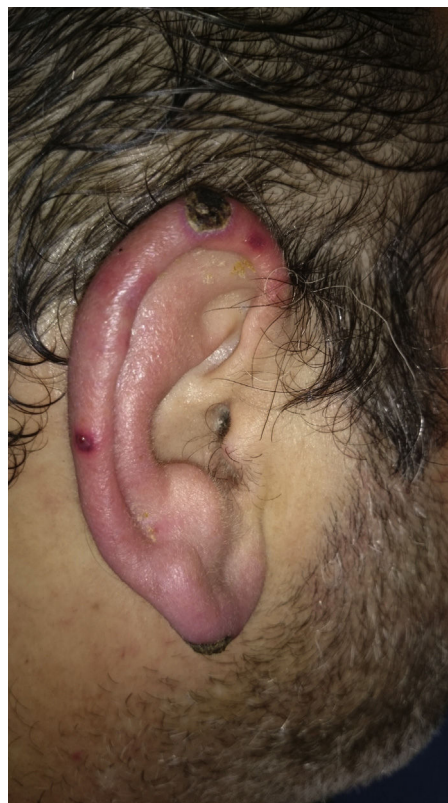### Vasculitis leucocitoclástica relacionada con cocaína adulterada con levamisol

Cocaine consumption has been increasing around the world in recent years and the associated complications are thus becoming more and more common.<sup>1</sup> Levamisole is often found in contaminated cocaine and can increase the length and intensity of the stimulant effect of this recreational drug.<sup>2,3</sup>

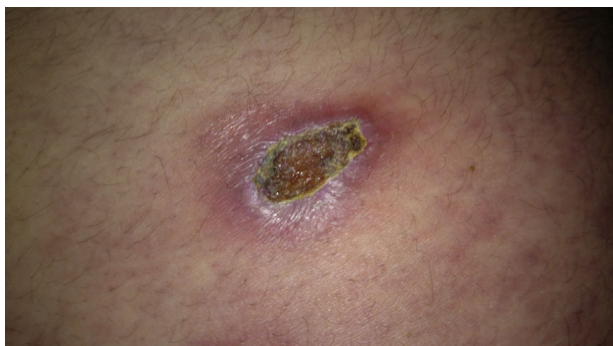### Case description

A 47-year-old man with no medical background of note attended the dermatology department for a 1-month history of painful skin lesions on both ears. He otherwise felt well. On further questioning, he denied having taken any new or different prescription drugs and reported no prodromal symptoms. However, he did state he was a smoker and a user of cocaine since the age of 25 years; of note, he had sniffed cocaine 3 days before the onset of the lesions.

At presentation, symmetrical, bilateral erythematous-violaceous patches were observed on his ears (Fig. 1) and on the lateral walls of the abdomen (Fig. 2). Over the following days, the lesions became infiltrated edematous papules and plaques that subsequently progressed to ulcerated necrotic plaques with an erythematous halo.



**Figure 1** Patches with a necrotic central area and erythematous borders on the right ear.



**Figure 2** Patch with a necrotic central area and erythematous border on the abdomen.

Full blood count and biochemistry were normal, including liver and kidney function tests. Urinalysis was unremarkable. Autoimmune screening revealed a polyclonal hypergammaglobulinemia, positive anticardiolipin M (48 U/ml), and positive antinuclear antibodies (titer, 1:160) with a speckled pattern. Complement was normal and the extractable nuclear antibodies panel (Smith, ribonucleoprotein, Ro, La, Scl-70, Jo-1), double-stranded DNA, antineutrophil cytoplasmic antibodies (ANCA), and cryoglobulins were negative. Serology for human immunodeficiency virus (HIV), hepatitis C virus (HCV) and hepatitis B virus (HBV) were negative and coagulation studies were normal. Chest X-ray did not show any relevant features. A full-thickness skin biopsy showed a leukocytoclastic vasculitis of the superficial and deep dermal and subcutaneous vascular plexuses, with some thrombotic features (Fig. 3). Urine drug screening was not performed. Based on these tests, we made a diagnosis of cutaneous leukocytoclastic vasculitis secondary to the use of levamisole-contaminated cocaine. The patient was treated with topical copper sulfate 1:1000 and betamethasone dipropionate, 0.05%, for 2 weeks, with an excellent response and complete clearance of the lesions without scarring, and no new lesions developed. The patient did not attend follow-up appointments.

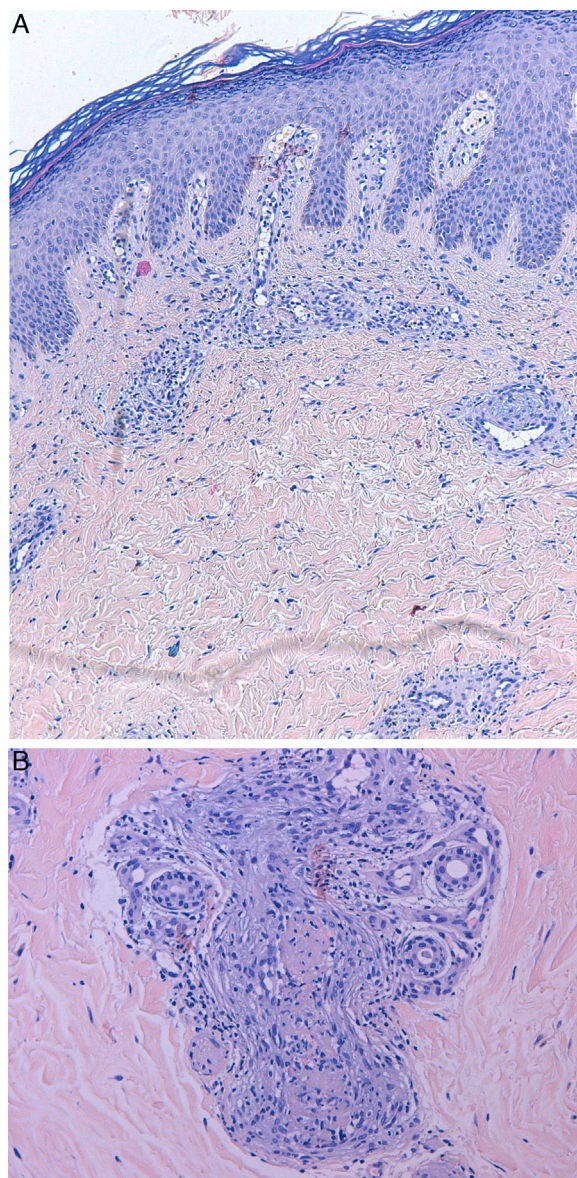
## Discussion

Skin lesions are rare after cocaine use; they usually develop 1–4 days after exposure to the drug. The clinical spectrum can be broad and may be associated with digital vasospasm, Raynaud phenomenon, livedo reticularis, Buerger's disease, urticarial vasculitis, bullous diseases, acral ulcers, gangrene, and small and medium vessel vasculitis.<sup>1–4</sup>

Lesions usually have a rapid onset, with a painful violaceous rash that tends to ulcerate and become necrotic, typically affecting the face (ears and cheeks) and lower legs. Systemic complications are uncommon except for joint pain, which is common.<sup>1,3–9</sup>

The pathogenesis of the condition is largely unknown, although some research points to tissue ischemia caused by blood vessel constriction, direct or indirect blood vessel damage induced by immune complexes, or thrombosis.<sup>1–3</sup>

Histopathologic features can include vascular thrombosis and leukocytoclastic vasculitis, with or without fibrinoid



**Figure 3** (A) Leukocytoclastic vasculitis of the superficial and deep dermal vascular plexuses, with some thrombotic features. Hematoxylin and eosin, original magnification  $\times 4$ . (B) Leukocytoclastic vasculitis with some thrombotic features. Hematoxylin and eosin, original magnification  $\times 20$ .

necrosis. These are nonspecific features and can be found in many other disorders.<sup>1,3,5</sup>

Patients may develop antiphospholipid antibodies (namely IgM anticardiolipin and lupus anticoagulant) and ANCA with a cytoplasmic (c-ANCA) or perinuclear (p-ANCA) pattern. C-ANCA antibodies almost exclusively target proteinase 3 (PR3) antigen whereas p-ANCA antibodies can bind multiple antigens, including myeloperoxidase, lactoferrin, human neutrophil elastase (HNE), and PR3; HNE is specifically targeted after cocaine use,<sup>1,3,4,10</sup> and this may induce neutropenia in some patients,<sup>1,9</sup> which can lead to confusion with other vasculitides, particularly with the ANCA-positive vasculitides (polyarteritis nodosa, microscopic polyangiitis, eosinophilic granulomatosis with

polyangiitis, granulomatosis with polyangiitis). As no pathognomonic laboratory or histopathologic criteria exist, the diagnosis is purely clinic and is made by exclusion. A detailed clinical history and a high level of clinical suspicion are paramount.<sup>1,3-9</sup>

The diagnostic approach to cases of suspected cocaine-induced cutaneous vasculitis should include complete blood count, biochemistry including liver and kidney function tests, erythrocyte sedimentation rate, urinalysis, chest X-ray, fecal occult blood, full thickness skin biopsy, antiphospholipid antibodies, coagulation studies including homocysteine and proteins C and S, cryoglobulins, serum ANCA and ANA antibodies, double-stranded DNA antibodies, rheumatoid factor and complement levels, and serology for HIV, HBV, and HCV. Other tests such as blood, urine, or skin microbiology should be performed as required.<sup>1,3,4</sup>

The skin lesions usually resolve within 2–3 weeks after cessation of cocaine use. Normalization of laboratory tests can take 2–14 months, though the neutropenia recovers fully in less than 10 days.<sup>1,3,5,7,8</sup>

There is no consensus regarding treatment of this condition. Obviously, removal of the cause is the most important measure, together with symptom relief. Good clinical outcomes have been reported with the use of nonsteroidal anti-inflammatory drugs for arthralgia and colchicine, dapsone, oral antihistamines, and pentoxifylline for the skin lesions.<sup>1,3,4</sup> Systemic corticosteroids have not been shown to be effective.

### Conflict of interest

The authors declare no conflict of interest.

### Bibliografía

1. Magliocca KR, Coker NA, Parker SR. The head, neck, and systemic manifestations of levamisole-adulterated cocaine use. *J Oral Maxillofac Surg.* 2013;71:487–92.
2. Larocque A, Hoffman RS. Levamisole in cocaine: unexpected news from an old acquaintance. *Clin Toxicol (Phila).* 2012;50:231–41.
3. Yachoui R, Kolasinski SL, Eid H. Limited cutaneous vasculitis associated with levamisole-adulterated cocaine. *J Clin Med Res.* 2012;4:358–9.
4. Salas-Espindola Y, Peniche-Castellanos A, López-Gehrke I, Mercadillo-Pérez P. Leukocytoclastic vasculitis related to cocaine use. *Actas Dermosifiliogr.* 2011;102:825–7.
5. Lawrence LA, Jiron JL, Lin HS, Folbe AJ. Levamisole-adulterated cocaine induced skin necrosis of nose, ears, and extremities. Case report. *Allergy Rhinol.* 2014;5:132–6.
6. Pillow MT, Hughes A. Levamisole-adulterated cocaine induced vasculitis with skin ulcerations. *West J Emerg Med.* 2013;14:149–50.
7. Souied O, Baydoun H, Ghandour Z, Mobarakai N. Levamisole-contaminated cocaine: an emergent cause of vasculitis and skin necrosis. *Case Rep Med.* 2014;2014:434717.
8. de la Hera I, Sanz V, Cullen D, Chico R, Petiti G, Villar M, et al. Necrosis of ears after use of cocaine probably adulterated with levamisole. *Dermatology.* 2011;223:25–8.
9. Chung C, Tumeah PC, Birnbaum R, Tan BH, Sharp L, McCoy E, et al. Characteristic purpura of the ears, vasculitis, and neutropenia – a potential public health epidemic associated with levamisole-adulterated cocaine. *J Am Acad Dermatol.* 2011;65:722–5.
10. Neynaber S, Mistry-Burchardi N, Rust C, Samtleben W, Burgdorf WH, Seitz MA, et al. PR3-ANCA-positive necrotizing multi-organ vasculitis following cocaine abuse. *Acta Derm Venereol.* 2008;88:594–6.

A. Imbernón-Moya\*, R. Chico, I. de la Hera, M.Á. Gallego-Valdés

*Servicios de Dermatología, del Hospital Universitario Severo Ochoa, Avda. de Orellana s/n. 28911 – Leganés (Madrid), Spain*

\* Corresponding author.

*E-mail address:* [adrian.imber88@hotmail.com](mailto:adrian.imber88@hotmail.com) (A. Imbernón-Moya).

<http://dx.doi.org/10.1016/j.ad.2016.04.015>

## Father-to-Newborn Transmission of Herpes Simplex Virus Infection: A Sweet but Bitter Kiss



### Herpes neonatal tras contacto con herpes labial paterno: dulce y amargo beso

*Dear Editor,*

While rare, neonatal herpes simplex virus (HSV) infection is one of the most severe perinatal infections. Only 10% of cases are acquired after birth. The disease is classified according to clinical presentation as follows: skin, eye, and mouth (SEM) disease (prevalence of ≈45%); central nervous system (CNS) disease (≈30%), and disseminated disease (≈25%), which has the worst prognosis.<sup>1</sup> No deaths have been reported for SEM disease, but 2% of those affected may

develop some degree of impairment by the age of 12 years.<sup>2</sup> Early recognition and treatment with high-dose acyclovir (60 mg/kg/d) reduces mortality and may improve long-term outcomes.<sup>3</sup>

We present the case of a 10-day-old newborn female admitted to the hospital with generalized skin lesions that had appeared 5 h previously. The lesions consisted of groups of vesicles and pustules overlying erythematous skin, affecting the trunk and tongue (Fig. 1). The infant did not have fever or neurologic symptoms and was systemically well. There had been no complications during the pregnancy, vaginal delivery, or immediate postpartum period. The mother had had systemic lupus erythematosus for the past 6 years, but this was clinically stable. She had had chickenpox during her childhood but had no genital lesions suggestive of herpes infection. The father, however, had active herpes simplex labialis and admitted to having repeatedly kissed his baby while he had active lesions. HSV type 1 was isolated from vesicular lesions in the neonate by real-time polymerase