


# ACTAS Dermo-Sifiliográficas

Full English text available at  
[www.actasdermo.org](http://www.actasdermo.org)



## REVIEW

# Skin manifestations of chronic kidney disease



J.C. Robles-Mendez, O. Vazquez-Martinez, J. Ocampo-Candiani\*

Dermatology Department, University Hospital "José Eleuterio González", Autonomous University of Nuevo León, Monterrey, Mexico

Received 18 May 2015; accepted 21 May 2015  
Available online 17 June 2015

### KEYWORDS

Chronic kidney disease;  
Nephrogenic systemic fibrosis;  
Calciophylaxis;  
Porphyria cutanea tarda

### PALABRAS CLAVE

Enfermedad renal crónica;  
Fibrosis sistémica nefrogénica;  
Calcifilaxis;  
Porfiria cutánea tarda

**Abstract** Skin manifestations associated with chronic kidney disease are very common. Most of these conditions present in the end stages and may affect the patient's quality of life. Knowledge of these entities can contribute to establishing an accurate diagnosis and prognosis. Severe renal pruritus is associated with increased mortality and a poor prognosis. Nail exploration can provide clues about albumin and urea levels. Nephrogenic systemic fibrosis is a preventable disease associated with gadolinium contrast. Comorbidities, such as diabetes mellitus and secondary hyperparathyroidism, can lead to acquired perforating dermatosis and calciophylaxis, respectively. Effective and innovative treatments are available for all of these conditions.  
© 2015 Elsevier España, S.L.U. and AEDV. All rights reserved.

### Manifestaciones Cutáneas de la Enfermedad Renal Crónica Skin manifestations of Chronic Kidney Disease

**Resumen** Las manifestaciones cutáneas asociadas a enfermedad renal crónica son muy comunes. La mayoría de estas enfermedades se presentan en la etapa terminal y pueden afectar la calidad de vida del paciente. El conocimiento de estas condiciones puede ser útil para establecer un diagnóstico y pronóstico preciso. El prurito renal severo está asociado a un incremento en la mortalidad y a un pobre pronóstico. La exploración ungueal puede proveer datos acerca del nivel plasmático de albumina y urea. La fibrosis sistémica nefrogénica es una enfermedad prevenible asociada a contrastes con gadolinio. Comorbilidades como la diabetes mellitus y el hiperparatiroidismo secundario, pueden causar dermatosis perforante adquirida y calcifilaxis, respectivamente. Existen tratamientos efectivos e innovadores para todos estos padecimientos.  
© 2015 Elsevier España, S.L.U. y AEDV. Todos los derechos reservados.

\* Corresponding author.

E-mail address: [Jocampo2000@yahoo.com.mx](mailto:Jocampo2000@yahoo.com.mx) (J. Ocampo-Candiani).

## Introduction

Patients with chronic kidney disease (CKD) commonly exhibit cutaneous manifestations associated with impaired renal function (Table 1). These skin lesions may affect their quality of life, and some conditions could even be life threatening. Knowledge of these lesions is important for an accurate diagnosis and prognosis. This review focuses mainly on classic specific disorders associated with CKD (Table 2), but other common nonspecific conditions are also discussed.

Although the pathogenesis is not clear in the majority of cases, effective and innovative treatments are available for these conditions (Table 3).

By definition, CKD comprises a structural renal injury (which may be evident in urine, blood, imaging studies or tissue biopsies) or a functional impairment (manifested as a decreased glomerular filtration rate of less than 60 ml/min/1.73 m<sup>2</sup>) over a period of 3 months. Most skin manifestations of renal impairment occur in patients with end-stage CKD (stage 5) with a glomerular filtration rate less than 15 ml/min/1.73 m<sup>2</sup>.<sup>1,2</sup>

## Renal pruritus

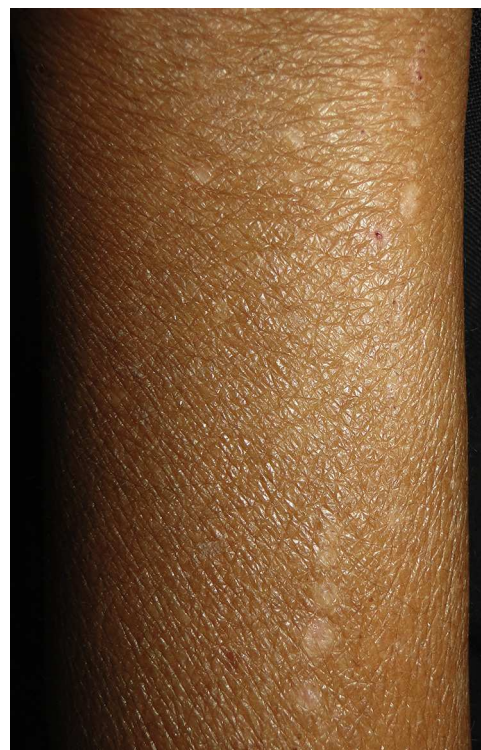Renal pruritus is observed in 50–90% of patients with end-stage CKD, primarily in individuals who have been on hemodialysis.<sup>3</sup> The severity rating scales typically used in renal pruritus include the visual analogue scale and the Yosovitch validated questionnaire.<sup>4</sup> Pruritus causes anxiety, depression and sleep disorders, and severe pruritus has been described as an independent risk factor for increased mortality and a poor prognosis.<sup>5</sup>

The cause of renal pruritus is multifactorial. Risk factors such as male sex and high levels of uraemic nitrogen, calcium, phosphorus,  $\beta_2$  microglobulin, magnesium, aluminium, vitamin A, histamine and mast cells, have been reported.<sup>6,7</sup>

Renal pruritus is considered to be a manifestation of a chronic inflammatory state, which involves cytokines such as TNF, IFN- $\gamma$ , and IL2 and acute phase reactants such as C-reactive protein. Pruritus is transmitted by C fibres. Opioids stimulate C fibres through  $\mu$  receptors and inhibit C fibres through  $\kappa$  receptors. C fibre stimulation via serotonin, histamine and prostaglandins might also play an important role. Abnormal innervation patterns, nerve damage and central sensitisation are additional proposed mechanisms. A genetic predisposition particularly associated with HLA B35 has been described.<sup>6,7</sup>

Clinical manifestations include localised or generalised pruritus, with the back being the most commonly affected site. Pruritus is often prolonged and severe and is exacerbated by heat, sweating and xerosis. Skin lesions, such as excoriations, lichen simplex, nodular prurigo and keratotic papules, may result from scratching (Fig. 1).<sup>6,7</sup>

In terms of treatment, the main objective is to relieve itching and improve the quality of life. Definitive treatment involves kidney transplantation. It is important to mention that antihistamines are not effective, and the majority of available treatments are only empirical and lack strong evidence.<sup>6,7</sup>



**Figure 1** Xerotic skin with excoriations marks secondary to renal pruritus.

General treatment consists of improving the quality of haemodialysis, increasing efficiency  $Kt/V$  urea  $> 1.4$  ( $Kt/V$  = dialysis adequacy.  $K$ , clearance.  $t$ , time.  $V$ , volume of distribution) using low calcium and magnesium dialysates, reducing calcium–phosphorus products and using more biocompatible membranes, such as those made of polymethylmethacrylate.<sup>8</sup>

Erythropoietin efficiently relieves itching by decreasing histamine levels. Its effect is not associated with haemoglobin levels and it is lost when administration is discontinued.<sup>9</sup> It is important to avoid xerosis, sweating and heat. Moisturisers constitute the first line of therapy, especially those containing gamma linoleic acid, glycerol and paraffin.<sup>10</sup> The addition of endocannabinoids to moisturisers has been proven effective.<sup>11</sup>

Topical treatment is preferred for localised pruritus. Studies have reported the efficacy of capsaicin and pramoxine. Capsaicin depletes P substance from C fibres, thus blocking pain and pruritus transmission; it is used as 0.025% cream four times daily.<sup>12</sup> Pramoxine lotion, a topical anaesthetic, used twice daily for 1 month has been proven effective.<sup>13</sup> The use of calcineurin inhibitors is controversial and is not recommended.<sup>14,15</sup>

Systemic treatment with gabapentin, a GABA agonist, is effective and safe. Due to its renal clearance, gabapentin is administered at low doses of 300 mg after each haemodialysis session.<sup>16–18</sup> The serotonin inhibitor 5 HT3 granisetron (1 mg twice daily for 1 month) is also effective.<sup>19,20</sup> The opioid agonist nalfurafine has proven to be effective.<sup>21</sup> Phototherapy with narrowband UVB has been used to decrease the production of cytokines by lymphocytes and to reduce phosphorus levels in the skin.<sup>22</sup> Among surgical treatments,

**Table 1** Classification of skin manifestations of chronic kidney disease and prevalence.

Classic specific disorders	Prevalence	Nonspecific disorders	Prevalence
Renal pruritus	50–90%	Xerosis	50–80%
Acquired perforating dermatosis	4.5–10%	Pigmentary changes	20–50%
Nephrogenic systemic fibrosis	Rare	Skin infections	40%
Calciophylaxis	1–4%	Uremic frost	1–3%
Porphyria cutanea tarda	1–18%	Nail disorders	30–60%
Pseudoporphyria	1–18%	Hair disorders	30–50%
		Mucosal alterations	50–90%

parathyroidectomy can be effective in cases with secondary hyperparathyroidism and high calcium–phosphorus products.<sup>23</sup> However, kidney transplantation is the definitive treatment.

### Acquired perforating dermatosis (APD)

APD is commonly observed in patients with end-stage CKD, especially in individuals with diabetes mellitus and individuals receiving haemodialysis.<sup>24–26</sup>

The pathogenesis of APD is unclear. APD is associated with diabetes mellitus, hypothyroidism, liver disease, malignancies and HIV infection. The mechanism involves transepidermal elimination of dermal components (collagen, elastin and cell detritus). Proposed trigger factors include minor trauma, such as scratching, microvascular changes associated with diabetes mellitus, skin calcium depositions with foreign body inflammatory response and genetic predisposition.<sup>24,26</sup>

Clinical manifestations include pigmented and umbilicated dome shaped papules with a depressed and scaling centre, located on the extensor surfaces of the arms and legs and less commonly, on the scalp, trunk and buttocks (Fig. 2). Koebner phenomenon may be present. This condition appears in outbreaks and typically resolves in 6–8 weeks with residual pigmentation and scarring. Differential diagnoses include prurigo nodularis and lichen planus.<sup>24,26</sup>

Histopathology findings include an excavated epidermis, acanthosis, cup shaped plugs composed of keratin, collagen and cell detritus that move from the epidermis to the exterior, and a perilesional inflammatory infiltrate composed of lymphocytes and neutrophils.<sup>24</sup>

Steroids (topical, oral or intralesional) are used to decrease inflammation and keratolytics and retinoids (topical or oral) are used to decrease epidermal thickness.<sup>27</sup>

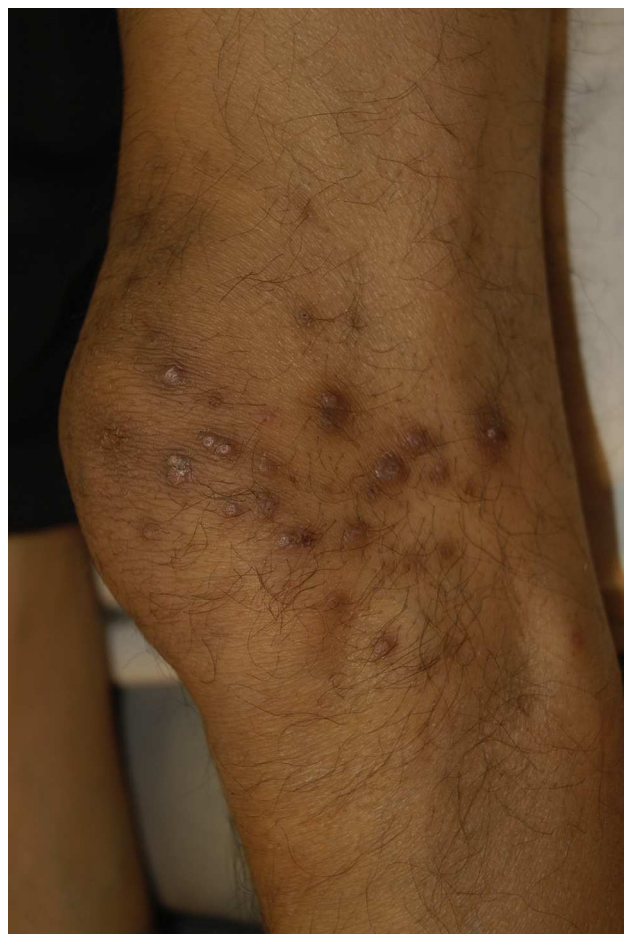Allopurinol, a xanthine-oxidase inhibitor, is used at a dose of 100 mg daily for 1–4 months; it has been proven effective in a series of cases. Allopurinol is thought to have antioxidant activity, thus decreasing free radicals involved in collagen damage.<sup>28</sup> Maxacalcitol (0.0025% ointment), a D vitamin analogue, was reported successful in four treated cases. It is applied twice daily for 2 months. Its mechanism of action remains unclear.<sup>29</sup>

UVB narrowband phototherapy has been used with success in a series of cases. Benefits are noted in 10–15 weeks.<sup>30</sup> Photodynamic therapy has also been reported to be effective.<sup>31</sup>

### Nephrogenic systemic fibrosis (NSF)

Formerly called nephrogenic fibrosing dermopathy, 380 cases of this rare disease have been registered at Yale University, and the first cases were recorded in 1997. No differences in gender and ethnicity were noted. NSF occurs in all ages, but predominantly in middle age.<sup>2,32</sup>

Ninety-five percent of the cases are associated with gadolinium, a contrast medium, which is used in MRI angiography in patients with low glomerular filtration rates.<sup>2,32</sup>



**Figure 2** Acquired perforating dermatosis. Pigmented and umbilicated dome shape papules with scaling centre. Image supplied by National Institute of Medical Science and Nutrition Salvador Zubiran.

**Table 2** Summary of classic specific disorders.

Disease	Risk factors	Pathogenesis	Clinical findings	Histopathology	Differential diagnosis
Renal pruritus	Hemodialysis, high levels of uraemic nitrogen, calcium and phosphorus	Chronic inflammatory state C fibres stimulation via opioids, serotonin, histamine and prostaglandins Abnormal innervation patterns, nerve damage and central sensitisation Genetic predisposition, HLA B35	Localised or generalised pruritus, with the back being the most common affected site Pruritus is often prolonged and severe and is exacerbated by heat, sweating and xerosis. Excoriations, lichen simplex, nodular prurigo result from scratching	Biopsy is usually not required	Other local or systemic disorders that cause pruritus
Acquired perforating dermatosis	Diabetes mellitus and hemodialysis Hypothyroidism, liver disease, malignancies and HIV infection	Transepidermal elimination of dermal components Trigger factors include minor trauma, microvascular changes and skin calcium depositions Genetic predisposition	Pigmented and umbilicated dome shaped papules with a depressed and scaling centre, located in the extensor surfaces of the arms and legs, and less commonly, in the scalp, trunk and buttocks	Acanthosis, cup shaped plugs composed of keratin, collagen and cell detritus that move from the epidermis to the exterior, and a perilesional inflammatory infiltrate composed of lymphocytes and neutrophils	Prurigo nodularis and lichen planus
Nephrogenic systemic fibrosis	Gadolinium use as contrast medium in MRI angiography Gadodiamide and gadopentetate are the most associated contrast media	Genetic predisposition (HLA A2) and an inflammatory state, allow gadolinium effectively enters the tissues Gadolinium is subsequently phagocytosed by macrophages, which release cytokines that attract circulating fibrocytes to the tissues, then the fibrocytes differentiate into fibroblast-like cells in the dermis leading to fibrosis	Indurated, erythematous-hyperchromic plaques with an orange peel, woody appearance. The lesions are bilateral and symmetrical on the legs and forearms Flexion contractures of adjacent limbs 5% of patients experience a rapid fulminant course in 2 weeks with multiple organ involvement	Thickened collagen bundles with clefts, mucin deposition and proliferation of spindled cells that stain positive for CD34 and procollagen 1. Multinucleated cells positive for CD68 and factor VIII are also present	Scleromyxedema, systemic sclerosis, eosinophilia-myalgia syndrome, toxic oil syndrome and eosinophilic fasciitis

Table 2 (Continuación)

Disease	Risk factors	Pathogenesis	Clinical findings	Histopathology	Differential diagnosis
Calciophylaxis	Secondary hyperparathyroidism and elevated calcium-phosphorus products	Increased calcium-phosphorus product Imbalance between inhibitors and inducers of vascular calcification	Painful, pink or purple, firm nodules or plaques, surrounded by livedo reticularis that progress to central and deep painful ulcers covered with black eschar. Calciophylaxis is bilateral and symmetrical and affects thighs, abdomen and buttocks	Calcification of the media, intimal hyperplasia of dermal and subcutaneous arterioles, thrombosis of dermal and subcutaneous vessels with ischaemic necrosis in the epidermis and lobular panniculitis with fat necrosis	Systemic vasculitis, coagulopathies, occlusive vasculopathies and bacterial and fungal infections
Porphyria cutanea tarda	Hemodialysis Type 1: hepatitis B and C, HIV-AIDS, alcohol, oestrogen and iron Type 2 is a hereditary, autosomal dominant disease	A defect in heme biosynthesis due to uroporphyrinogen decarboxylase deficiency In CKD, low levels of uroporphyrins are excreted; their accumulation in skin causes phototoxicity reactions	Blisters, erosions and crusts that are located on exposed areas, such as the back of hands and forearms and occasionally the face and feet. These lesions heal with scarring or milia and may be accompanied of hypertrichosis and hyperpigmentation and esclerodermoid plaques	Subepidermal cleft with minimal inflammation and festooned papillary dermis. Direct immune-fluorescence indicates linear and granular deposition of immunoglobulin G and C3 in the dermal-epidermal junction and around the vessels	Pseudoporphyria, other hereditary porphyrias drug-related phototoxic reactions, epidermolysis bullosa acquisita
Pseudo-porphyrria	Phototoxic drugs, such as tetracycline, furosemide, naproxen, amiodarone, nalidixic acid and isotretinoin, and exposure to ultraviolet light A	Phototoxic metabolites are formed. Patients with CKD have decreased glutathione levels in erythrocytes, making them susceptible to damage by free radicals	Blisters on the back of hands, forearms and other exposed areas that resolve with scarring and milia. Hypertrichosis on the face or sclerodermoid plaques are rarely observed	Subepidermal cleft with minimal inflammation. Direct immunofluorescence staining indicates immunoglobulin G and C3 deposition at the dermal-epidermal junction and around vessels	Hereditary porphyrias, drug-related phototoxic reactions, epidermolysis bullosa acquisita

MRI: magnetic resonance imaging, CKD: chronic kidney disease.

**Table 3** Treatment of classic specific disorders associated to chronic kidney disease.

Disorder	Treatment option	Dosage	Action mechanism
Renal pruritus	Improving the quality of hemodialysis	Increasing efficiency $Kt/V$ urea > 1.4, using low calcium and magnesium dialysates and using more biocompatible membranes	Reduce calcium-phosphorus products. Membranes of polymethylmethacrylate absorb and eliminate cytokines
	Erythropoietin	20–50 U/kg is administered thrice weekly	Decreasing histamine levels
	Moisturiser (gamma linoleic acid, glycerol and paraffin)	Three times a day	Prevent xerosis
	Capsaicin	0.025% cream four times daily	Depletes P substance from C fibres, thus blocking pain and pruritus transmission
	Pramoxine	Twice daily for 1 month	Topical anaesthetic
	Gabapentin	300 mg after each hemodialysis session	GABA agonist
	Granisetron	1 mg twice daily for 1 month	Serotonin inhibitor 5 HT3
	Nalfurafine	5 µg thrice weekly by intravenous infusion, immediately after each hemodialysis for 4 weeks	Opioid agonist. Inhibit C fibres by κ receptor
	Narrowband UVB phototherapy	Three sessions per week. Initial dose of 200 mJ/cm <sup>2</sup> , increasing 100 mJ/cm <sup>2</sup> at every session, until a maximum dose of 1500 mJ/cm	Decrease the production of cytokines by lymphocytes and phosphorus levels in the skin
	Parathyroidectomy		Effective in cases with secondary hyperparathyroidism and high calcium-phosphorus products
Acquired perforating dermatosis	Kidney transplant		Increased glomerular filtration
	Steroids (topical, oral or intralesional)		Decrease inflammation
	Keratolytics and retinoids (topical or oral)		Decrease epidermal thickness
	Allopurinol	100 mg daily for 1–4 months	Xanthine-oxidase inhibitor. It acts by an antioxidant action, thus decreasing free radicals involved in collagen damage
	Maxacalcitol	Twice daily for 2 months	D vitamin analogue. Mechanism of action remains unclear
	Narrowband UVB phototherapy	It begins at 400 mJ/cm <sup>2</sup> until a therapeutic range of 700–1600 mJ/cm <sup>2</sup> is achieved. Three sessions per week. After improvement is achieved, 1–2 sessions a week for maintenance	Anti-proliferative and anti-inflammatory effects; relief of pruritus
Nephrogenic Systemic Fibrosis	Photodynamic therapy	Single session with 5-aminolevulinic acid	Production of reactive oxygen species with cell apoptosis and necrosis
	Preventive measures	Gadoteridol is the safest option. In hemodialysis patients, two 4-h sessions should be performed in the first 3 h to remove the contrast	
	Prednisone	1 mg/kg every 24 h	Decrease inflammation

Table 3 (Continuación)

Disorder	Treatment option	Dosage	Action mechanism
Calciphylaxis	Extracorporeal photopheresis	Two treatments on consecutive days every 2 weeks for 6 months, then two treatments on consecutive days every 4 weeks for 6 months	Enhances the suppression of signals by inducing lymphocytes apoptosis and deflecting the signal of antigen-presenting cells
	Kidney transplant		Increased glomerular filtration and immunosuppression in transplantation
	Imatinib mesylate	400–600 mg/day are administered, for 4–24 weeks	Tyrosine kinase inhibitor, acts by inhibiting platelet-derived growth factor and c-Abl kinase, thus inhibiting the synthesis of collagen and fibronectin by dermal fibroblasts
	UV-A 1 phototherapy	Three sessions per week, at 60–120 J/cm <sup>2</sup> in 22–50 sessions	Alters the cytokine levels relating to fibrocytes to promote a less fibrotic environment
	Physical therapy		Improves the performance of daily activities and personal care
	Plasmapheresis, immunoglobulin G and photodynamic therapy		Anecdotal success
	Total or subtotal surgical parathyroidectomy		Reducing the production of parathyroid hormone
	Cinacalcet	30–60 mg/day orally	Calcium mimetic that increases sensitivity of the calcium receptor in the parathyroid gland, thus reducing the production of parathyroid hormone
	Etidronate	200 mg/day orally for 14 days	Inhibit vascular calcification
	Pamidronate	30 mg intravenously for five treatments over a period of 2 weeks	Inhibit vascular calcification
	Prednisone	30–50 mg orally every 24 h, for 3–5 weeks	Decrease inflammation
	Sodium thiosulfate	25 g is administered intravenously for 30–60 min, three times a week after each hemodialysis session	Displacing calcium from calcium phosphate, to form calcium thiosulfate, which is more soluble
	Improving the quality of hemodialysis	Increasing the frequency and duration of hemodialysis through the use of low calcium dialysate	Reduce calcium–phosphorus products
	Sevelamer		Phosphorus chelator that reduces the intestinal absorption of phosphorus. Reduce calcium–phosphorus products
General wound management	Debridement of necrotic tissue, antibiotics, analgesia, cures and vacuum dressing	To prevent infection and sepsis	
Hyperbaric oxygen therapy	Daily sessions for 60–90 min per week with 100% oxygen at 2.5 atmospheres of pressure	Stimulates angiogenesis and is toxic to anaerobic bacteria	

Table 3 (Continuación)

Disorder	Treatment option	Dosage	Action mechanism
Porphyria cutanea tarda	Cultured autologous fibroblasts and keratinocytes, adding iloprost	35 consecutive days	To coat ulcers. Iloprost is a vasodilator prostacyclin analogue
	Ulcer debridement, coated with partial autologous skin grafts		To prevent infection and sepsis, and to coat ulcer
	Preventive measures	Avoid sun exposure, use zinc oxide and titanium oxide-based sunscreen, avoid alcohol, estrogens, iron and treat comorbidities	Avoiding exacerbating factors
	Improving the quality of hemodialysis	To use high-flux membranes (polysulfone) with high flux dialysis (300 ml/h), during 4 h of hemodialysis, three times a week	Removing high plasma levels of uroporphyrins
	Phlebotomy	Low volume of 100 ml, twice weekly for 8 months, followed by 50 ml per week thereafter	Decrease in body stores of iron. Activating uroporphyrinogen decarboxylase
	Erythropoietin	20–50 U/kg is administered thrice weekly. When erythropoietin is combined with phlebotomy, a dose of 150–200 U/kg is used	Decrease in body stores of iron. Activating uroporphyrinogen decarboxylase
	Deferoxamine	2 g is administered intravenously every hemodialysis.	Chelating agent used to remove iron
Pseudo-porphyrria	Plasmapheresis	Two sessions, separated by 48 h	Removing high plasma levels of uroporphyrins
	Renal transplant		Increasing glomerular filtration, thus excreting uroporphyrins
	Preventive measures	Avoid sun exposure, trauma and related drugs	Avoiding exacerbating factors
	N-acetyl-cysteine	600–1200 mg/day orally for weeks	Precursor of glutathione with antioxidant properties

Gadodiamide and gadopentetate are the most common causes of contrast media associated with NSF. The poorer the glomerular filtration rate, the longer the half-life of gadolinium. In addition, 73.8% and 92.4% of gadolinium is excreted in a single haemodialysis session or two sessions, respectively, but gadolinium is not properly excreted in peritoneal dialysis.<sup>2,32</sup>

In patients with a genetic predisposition (HLA A2) or an inflammatory state, a hypercoagulable state or endothelial damage, gadolinium enters the tissues, 35–150-fold more effectively compared with healthy patients. Gadolinium is subsequently phagocytosed by macrophages, which release cytokines that attract circulating fibrocytes (CD34/procollagen I+) to the tissues. Once in the tissue, the fibrocytes differentiate into fibroblast-like cells in the dermis, leading to fibrosis.<sup>2,32</sup>

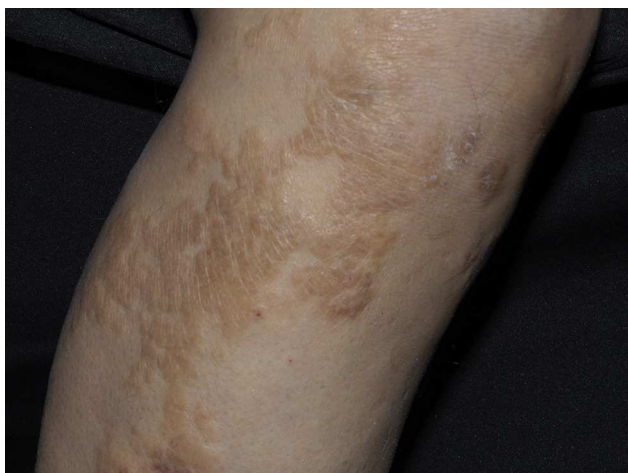Clinical manifestations include indurated, erythematous-hyperchromic plaques with an orange peel, woody or cobblestone appearance. Nodules and bullae may be present

on the hands and feet, or yellowish edematous plaques are noted on the sclera (Fig. 3). The lesions are bilateral and symmetrical on the legs and forearms. The condition is occasionally observed on the trunk and buttocks and generally spares the face.<sup>2,32</sup>

A burning, itching, and stinging pain occurs. Flexion contractures of adjacent limbs are noted, days to weeks after exposure to the contrast, and the condition tends to be chronic. Remission is achieved in a few cases, leaving atrophic and hypopigmented lesions; 5% of patients experience a rapid fulminant course in 2 weeks with multiple organ involvement (lungs, heart and oesophagus). Differential diagnoses include scleromyxedema, systemic sclerosis, eosinophilia-myalgia syndrome, toxic oil syndrome and eosinophilic fasciitis.<sup>2,32</sup>

The histopathology is characterised by thickened collagen bundles with clefts, mucin deposition and proliferation of spindle cells that stain positive for CD34 and procollagen





**Figure 3** Nephrogenic systemic fibrosis. Indurated hyperchromic plaques with orange peel and woody appearance. Image supplied by National Institute of Medical Science and Nutrition Salvador Zubiran.

1. Multinucleated cells positive for CD68 and factor VIII are also present.<sup>2,24,32</sup>

For prevention, if a macrocyclic contrast medium must be used, gadoteridol is the safest option. In haemodialysis patients, two 4-h sessions are required to remove the contrast; these sessions should be performed in the first 3 h.<sup>33</sup>

Most treatments demonstrate efficacy in anecdotal and cases reports. Steroids and immunosuppressants are generally ineffective. Oral prednisone may be used with some efficacy, but many adverse effects are observed.<sup>33</sup>

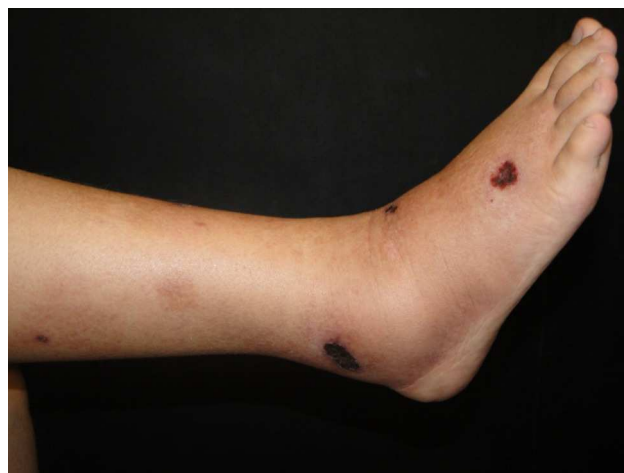Extracorporeal photopheresis is available in a few centres, but is prohibitively expensive. It has been proven to be effective in all patients, increasing softening of injuries and mobility ranges. Extracorporeal photopheresis enhances the suppression of signals by inducing lymphocyte apoptosis and deflecting the signal of antigen-presenting cells.<sup>34</sup>

Kidney transplantation offers improvement in 54% of patients and full remission has been achieved in some cases. It improves mobility ranges of flexion contracture, likely due to increased glomerular filtration and immunosuppression after transplantation.<sup>35,36</sup>

Imatinib mesylate, a tyrosine kinase inhibitor, acts by inhibiting platelet-derived growth factor and c-Abl kinase, thus inhibiting the synthesis of collagen and fibronectin by dermal fibroblasts. Doses of 400–600 mg/day are administered for 4–24 weeks, achieving mild to moderate success. The lesions are softened, but little improvement is noted in the range of motion.<sup>37</sup>

UV-A 1 phototherapy has been proven effective in smoothing skin lesions, with little improvement in range of motion. It is used at 60–120 J/cm<sup>2</sup> in 22–50 sessions.<sup>38</sup>

Plasmapheresis and immunoglobulin G exhibit anecdotal success.<sup>39</sup> Physical therapy improves the performance of daily activities and personal care, with little improvement in the range of motion.<sup>40</sup> In a case report, photodynamic therapy was effective along with kidney transplantation.<sup>41</sup>



**Figure 4** Calciphylaxis. Ulcers covered with black eschar.

## Calciphylaxis

Calciphylaxis occurs in patients with CKD on hemodialysis; it is associated with secondary hyperparathyroidism and elevated calcium-phosphorus products. Calciphylaxis is an obliterative vasculopathy caused by the deposition of calcium in the arterioles of the skin, leading to thrombosis and ischaemic necrosis with ulceration.<sup>2</sup>

Calciphylaxis is commonly observed in women, in patients with diabetes mellitus, obesity, hypoalbuminemia, liver cirrhosis, those who use warfarin, and those with systemic inflammation and malignancy. Sepsis can cause up to 80% mortality via skin ulcer infection.<sup>2</sup>

Its etiopathogenic mechanism is unclear. Predisposition plus a causal factor are necessary. Calcium–phosphorus products are increased in the majority of patients, but this increase is not sufficient alone to cause the condition. An imbalance between inhibitors and inducers of vascular calcification is noted. Osteopontin and bone morphogenic protein 2 serve as inducers, whereas GI protein matrix, fetuin and pyrophosphate act as inhibitors. Aluminium deposition may also be an inductor.<sup>2</sup>

Clinical manifestations include painful, pink or purple, firm nodules or plaques, surrounded by livedo reticularis that progress to central and deep, painful ulcers covered with black eschar and a reticulated depigmentation in the periphery (Fig. 4). Calciphylaxis is bilateral and symmetrical and affects adipose tissue areas, such as the thighs, abdomen and buttocks.<sup>42,43</sup>

Histopathologic findings include calcification of the media, intimal hyperplasia of dermal and subcutaneous arterioles, thrombosis of dermal and subcutaneous vessels with ischaemic necrosis in the epidermis and lobular panniculitis with fat necrosis. On radiography, linear calcium deposits are observed. The involvement of small blood vessels (0.5 mm) is the most specific sign; however, many patients exhibit vascular calcification without calciphylaxis.<sup>42,43</sup>

For therapy, early total or subtotal surgical parathyroidectomy increases survival. Cinacalcet is a calcium mimetic that increases sensitivity of the calcium receptor in the parathyroid gland, thus reducing the production of

parathyroid hormone. Cinacalcet is used in cases where parathyroidectomy is delayed or contraindicated. Treatment is discontinued once PTH reaches a normal level of 1.5 to prevent renal osteodystrophy.<sup>44</sup>

Among bisphosphonates, etidronate and pamidronate have proven to be effective. Prednisone is used in early unulcerated plaques.<sup>44</sup>

Sodium thiosulfate is administered either orally daily or intravenously at the end of haemodialysis for 3–5 months. Sodium thiosulfate offers symptomatic and radiological relief of tissue calcification, displacing calcium from calcium phosphate, to form calcium thiosulfate, which is more soluble than other salts and is excreted either by haemodialysis or by the kidneys. Sodium thiosulfate (25 g) is administered intravenously for 30–60 min, three times a week after each haemodialysis session. Metabolic acidosis is an important side effect of this drug.<sup>44</sup>

Dialysis improves this condition through using low calcium dialysate and increasing the frequency and duration of hemodialysis sessions. Sevelamer is a phosphorus chelator that reduces the intestinal absorption of phosphorus. Calcium–phosphorus product levels below 55 mg/dl are the objective.<sup>44</sup>

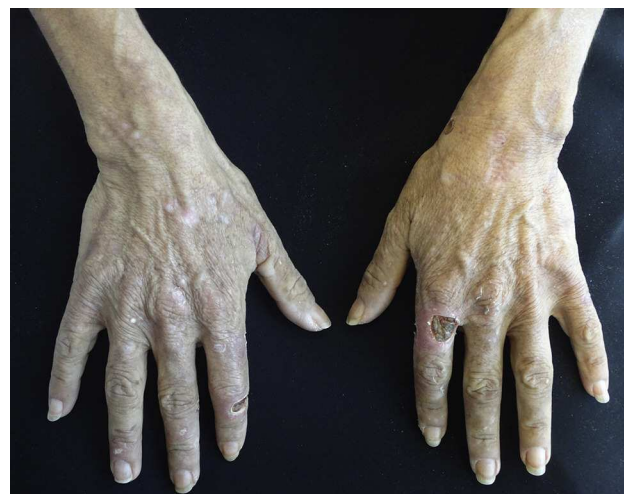
In wound management, debridement of necrotic tissue, antibiotics, analgesia, and vacuum dressing are important. Hyperbaric oxygen therapy stimulates angiogenesis and is toxic to anaerobic bacteria. It is used in daily sessions for 60–90 min per week with 100% oxygen at 2.5 atmospheres of pressure. Ulcer debridement is coated with partial autologous skin grafts. Successful attempts have been made to coat ulcers with cultured autologous fibroblasts and keratinocytes by adding iloprost infusion (vasodilator prostacyclin analogue) for 35 consecutive days.<sup>44</sup>

## Porphyria cutanea tarda

Porphyria cutanea tarda (PCT) occurs in 1.2–18% of patients with CKD and is more frequently observed in patients on haemodialysis. It is a bullous dermatosis caused by phototoxicity due to uroporphyrinogen decarboxylase deficiency, thus causing elevated levels of uroporphyrin and isocoporphyrin.<sup>42,45,46</sup>

PCT is classified as Type 1 when it is sporadic and acquired, and is caused by a liver enzyme deficiency. It is associated with hepatitis B and C, HIV-AIDS, alcohol consumption, oestrogen and iron. Type 2 is a hereditary, autosomal dominant disease caused by enzyme deficiency in all tissues. A defect in heme biosynthesis is due to uroporphyrinogen decarboxylase deficiency. It requires less than 30% activity of the enzyme to induce clinical manifestations.<sup>42</sup> In CKD, low levels of uroporphyrins are excreted and accumulate, causing phototoxicity reactions. Uroporphyrins cannot be removed by haemodialysis, but high-flux membranes improve elimination.<sup>42,45,46</sup>

Clinical manifestations include blisters, erosions and crusts that are located on exposed areas, such as the back of hands and forearms and occasionally the face and feet (Fig. 5). These lesions heal with scarring or milia and may be accompanied by hypertrichosis and hyperpigmentation of the face and by esclerodermoid plaques on the hands and face.<sup>42,45,46</sup>



**Figure 5** Porphyria cutanea tarda. Erosions and crusts on the back of the hands. Image supplied by National Institute of Medical Science and Nutrition Salvador Zubiran.

Laboratory findings include increased serum iron and ferritin, high urine levels of uroporphyrins I and III, and 7–8-carboxyl uroporphyrins, high plasma levels of uroporphyrin and increased levels of isocoporphyrin III in the faeces.<sup>42,45</sup>

Histopathology reveals a subepidermal cleft with minimal inflammation and festooned papillary dermis in the base of the cleft. The vessel wall is thickened. Direct immunofluorescence staining indicates linear and granular deposition of immunoglobulin G and C3 in the dermal-epidermal junction and around the vessels.<sup>42,45</sup>

For the treatment of PCT, sun exposure should be avoided; the use of zinc oxide and titanium oxide-based sunscreen is recommended. Treatment of comorbidities and to avoid exacerbating factors (iron and alcohol consumption, and estrogen using) are also important. Furthermore, it is important to use high-flux membranes (polysulfone) with high-flux dialysis (300 ml/h), during 4 h of haemodialysis, three times a week.<sup>47</sup>

Reduce body stores of iron in body stores of iron. Iron induces the enzyme 5-aminolevulinic synthase, which suppresses uroporphyrinogen decarboxylase. Further, it increases conversion of uroporphyrinogen into porphyrins. Phlebotomy is used at a low volume of 100 ml, twice weekly for 8 months, followed by 50 ml per week thereafter; normal phlebotomy is not tolerated due to anaemia.<sup>47</sup> Erythropoietin (20–50 U/kg) is administered thrice weekly. When erythropoietin is combined with phlebotomy, a dose of 150–200 U/kg, three times per week is used. Deferoxamine (2 g) is administered intravenously every haemodialysis session and is associated with long-term adverse effects.<sup>47</sup> In refractory cases, two plasma exchange treatments, separated by 48 h, are applied. Renal transplantation is the definitive treatment.<sup>47</sup>

## Pseudoporphyria

Pseudoporphyria is a bullous dermatosis induced by phototoxicity that exhibits the clinical and histopathologic features of PCT; however, normal uroporphyrin levels are

observed. The condition is associated with the use of phototoxic drugs such as tetracycline, furosemide, naproxen, amiodarone, nalidixic acid and isotretinoin, and exposure to ultraviolet light A.<sup>42,45</sup>

Regarding pathogenesis, phototoxic metabolites are formed. Patients with CKD have decreased glutathione levels in erythrocytes, making them susceptible to damage by free radicals. N acetyl-cysteine, a precursor of glutathione with antioxidant properties, is used to effectively treat these patients.<sup>42,45</sup>

Clinical manifestations include blisters on the back of the hands, forearms and other exposed areas that resolve with scarring and milia. Hypertrichosis on the face or sclerodermoid plaques is rarely observed. Uroporphyrin levels in plasma or urine are normal or slightly elevated.<sup>42,45</sup>

Histopathology reveals a subepidermal cleft with minimal inflammation and a thick vessel wall. Direct immunofluorescence staining indicates immunoglobulin G and C3 deposition at the dermal-epidermal junction and around vessels.<sup>42,45</sup>

N-acetyl-cysteine, a precursor of glutathione with antioxidant properties, has been effective therapy in several case reports. An oral dose of 600–1200 mg/day offers relief in 4–8 of weeks. Recurrence has been reported after discontinuing medication. It is recommendable to avoid exacerbating factors such as sun exposure, trauma and related drugs.<sup>48</sup>

## Benign nodular calcification

Firm papules, plaques and nodules appear in the joints and fingertips due to metastatic calcification affecting skin. Von Kossa stains calcium deposits black. Treatment is based on reducing calcium–phosphorus products and surgical removal.<sup>42</sup>

## Xerosis

Xerosis is the most common skin manifestation of CKD, occurring in 80% of patients. Etiopathogenic mechanisms include: Decreased hydration of the stratum corneum; decreased sweat gland and sebaceous gland size along with abnormal function related to hypervitaminosis A in dialysis patients, and the use of diuretics. Treatment is based on skin hydration and treatment of pruritus. Repetitive bathing must be avoided and the use of soft, neutral soaps is recommended.<sup>45</sup>

## Pigmentary changes

Dark brown pigmentation is caused by increased melanin production due to  $\beta$ -melanocyte stimulating hormone accumulation, which is caused by decreased excretion due to kidney failure. The yellowish tinge is caused by the accumulation of carotenoids and urochrome in the skin. Pallor is caused by anaemia due to ineffective erythropoiesis and increased haemolysis. Treatment is based on avoiding sun exposure and involves sunscreen use for hyperpigmentation as well as erythropoietin for anaemia associated with pallor.<sup>49,50</sup>

## Skin infections

Skin infections are caused by impaired cellular and humoral immunity. They are more common when diabetic nephropathy is the origin. The most common fungal infection is onychomycosis. The most frequent viral infections are common warts, herpes simplex and herpes zoster.<sup>49,50</sup>

## Uremic frost

Uremic frost is currently a rare manifestation. However when observed, the condition is often accompanied with increased BUN, ranging from 250 to 300 mg/dl. It is caused by the accumulation of urea in sweat. When the sweat evaporates, a crystal deposit remains on the skin that appears as a yellowish-white coating on the beard area, neck and trunk.<sup>49,50</sup>

## Nail disorders

**Mees lines.** These transverse bands of leukonychia are an alteration of the nail plate that occurs during periods of stress. In addition to its association with CKD, this condition appears in cases of poisoning by arsenic, thallium, and fluorine as well as severe infections, heart disease and malignancy.<sup>51</sup>

**Muehrcke's lines.** Double white transverse lines are caused by hypoalbuminemia related to nephrotic syndrome; Muehrcke lines are associated with serum albumin levels less than 2.2 g/dl. It originates by vascular compression through local oedema, which causes bleaching of the nail bed. Therefore, no change in position occurs as the nail grows. It has also been observed in cases of cirrhosis, malnutrition and chemotherapy use.<sup>52</sup>

**Lindsay nails (half and half).** This condition is related to azotaemia. A white proximal area and a distal pink red-brown area that does not fade under pressure are observed (Fig. 6). No changes are noted with nail growth because the lesion is located in the nail bed. An increase in the number of capillaries in the distal nail plate and a deposit of melanin pigmentation in the distal area are observed. This condition resolves with renal transplantation.<sup>53</sup>

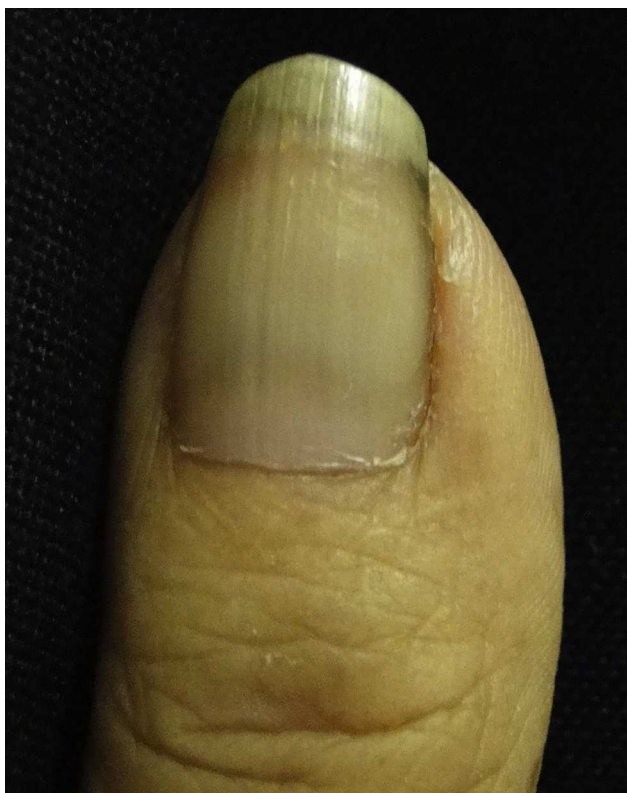
Other nail changes observed include leukonychia, koilonychia and splinter haemorrhages.<sup>49,50</sup>

## Hair disorders

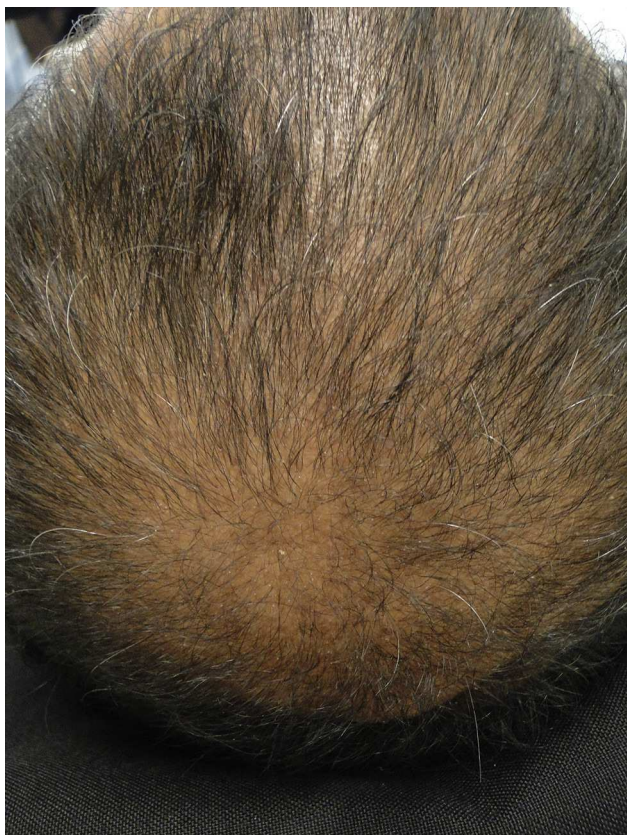Diffuse alopecia, the most common manifestation, is caused by telogen effluvium; xerosis, pruritus and medication use (Fig. 7). Sparse body hair is also present. Discoloration and dryness of the hair are attributed to a decreased sebum production. Treatment for hair loss is based on meeting nutritional requirements, which are increased in these patients.<sup>49,50</sup>

## Mucosal alterations

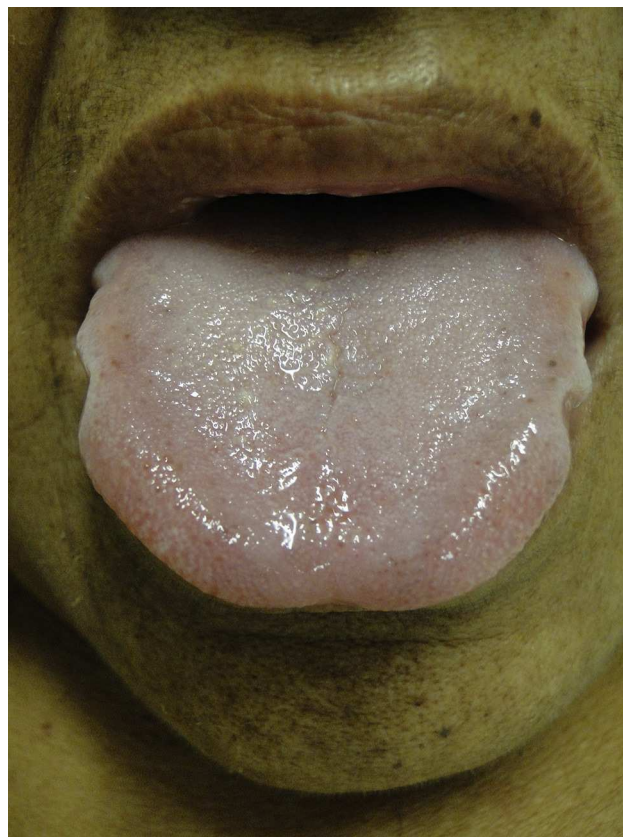
Xerostomia is the most common abnormality and is caused by oral breathing and dehydration. Macroglossia is also often observed (Fig. 8). Ulcerative stomatitis is observed with urea



**Figure 6** Half and Half nail. A white proximal area and a red-brown distal area are observed.



**Figure 7** Diffuse alopecia.



**Figure 8** Macroglossia. An enlarged tongue framed in its edge by teeth, pallor is also observed in the perioral skin.

serum levels greater 150 mg/dl and is associated with poor hygiene. Uraemic breath is due to increased urea concentrations in saliva and its transformation into ammonium. The condition is associated with urea levels >200 mg/dl. Treatment is based on maintaining good oral hygiene and meeting nutritional requirements.<sup>49,50</sup>

## Conclusions

Skin manifestations are very common in end-stage CKD. Severe renal pruritus is associated with increased mortality and a poor prognosis. Nephrogenic systemic fibrosis is a relatively new preventable disease associated with gadolinium. In a simple exploration of the nails, some findings indicate alterations in albumin and urea levels. Comorbidities such as diabetes mellitus and secondary hyperparathyroidism can lead to acquired perforating dermatosis and calciphylaxis, respectively. Effective and innovative treatments are available for all of these conditions.

## Ethical responsibilities

**Protection of human and animal subjects.** The authors declare that no experiments were performed on humans or animals for this investigation.

**Confidentiality of data.** The authors declare that they have followed the protocols of their work center on the publication of patient data.

**Right to privacy and informed consent.** The authors must have obtained the informed consent of the patients and/or subjects mentioned in the article. The author for correspondence must be in possession of this document.

## Conflict of interest

The authors declare that they have no conflict of interest.

## References

- Stevens PE, Levin A, Kidney Disease: Improving Global Outcomes Chronic Kidney Disease Guideline Development Work Group Members. Evaluation and management of chronic kidney disease: synopsis of the kidney disease: improving global outcomes 2012 clinical practice guideline. *Ann Intern Med.* 2013;158:825–30.
- Brewster UC. Dermatological disease in patients with CKD. *Am J Kidney Dis.* 2008;51:331–44.
- Dar NR, Akhter A. Clinical characteristics of uremic pruritus in patients undergoing haemodialysis. *J Coll Physicians Surg Pak.* 2006;16:94–6.
- Zucker I, Yosipovitch G, David M, Gafter U, Boner G. Prevalence and characterization of uremic pruritus in patients undergoing hemodialysis: uremic pruritus is still a major problem for patients with end-stage renal disease. *J Am Acad Dermatol.* 2003;49:842–6.
- Narita I, Alchi B, Omori K, Sato F, Ajiro J, Saga D, et al. Etiology and prognostic significance of severe uremic pruritus in chronic hemodialysis patients. *Kidney Int.* 2006;69:1626–32.
- Kfoury LW, Jurdi MA. Uremic pruritus. *J Nephrol.* 2012;25:644–52.
- Lugon JR. Uremic pruritus: a review. *Hemodial Int.* 2005;9:180–8.
- Hiroshige K, Kabashima N, Takasugi M, Kuroiwa A. Optimal dialysis improves uremic pruritus. *Am J Kidney Dis.* 1995;25:413–9.
- Pascual J, Teruel JL, Ortuño J. Erythropoietin therapy for uremic pruritus. *N Engl J Med.* 1992;327:734, author reply 734–735.
- Chen YC, Chiu WT, Wu MS. Therapeutic effect of topical gamma-linolenic acid on refractory uremic pruritus. *Am J Kidney Dis.* 2006;48:69–76.
- Szepietowski JC, Reich A, Szepietowski T. Emollients with endocannabinoids in the treatment of uremic pruritus: discussion of the therapeutic options. *Ther Apher Dial.* 2005;9:277–9.
- Tarnag DC, Cho YL, Liu HN, Huang TP. Hemodialysis-related pruritus: a double-blind, placebo-controlled, crossover study of capsaicin 0.025% cream. *Nephron.* 1996;72:617–22.
- Young TA, Patel TS, Camacho F, Clark A, Freedman BI, Kaur M, et al. A pramoxine-based anti-itch lotion is more effective than a control lotion for the treatment of uremic pruritus in adult hemodialysis patients. *J Dermatolog Treat.* 2009;20:76–81.
- Pauli-Magnus C, Klumpp S, Alschner DM, Kuhlmann U, Mettang T. Short-term efficacy of tacrolimus ointment in severe uremic pruritus. *Perit Dial Int.* 2000;20:802–3.
- Duque MI, Yosipovitch G, Fleischer AB, Willard J, Freedman BI. Lack of efficacy of tacrolimus ointment 0.1% for treatment of hemodialysis-related pruritus: a randomized, double-blind, vehicle-controlled study. *J Am Acad Dermatol.* 2005;52:3 Pt 1:519–21.
- Vila T, Gommer J, Scates AC. Role of gabapentin in the treatment of uremic pruritus. *Ann Pharmacother.* 2008;42:1080–4.
- Gunal AI, Ozalp G, Yoldas TK, Gunal SY, Kirciman E, Celiker H. Gabapentin therapy for pruritus in haemodialysis patients: a randomized, placebo-controlled, double-blind trial. *Nephrol Dial Transplant.* 2004;19:3137–9.
- Razeghi E, Eskandari D, Ganji MR, Meysamie AP, Togha M, Khashayar P. Gabapentin and uremic pruritus in hemodialysis patients. *Ren Fail.* 2009;31:85–90.
- Ashmore SD, Jones CH, Newstead CG, Daly MJ, Chrystyn H. Ondansetron therapy for uremic pruritus in hemodialysis patients. *Am J Kidney Dis.* 2000;35:827–31.
- Layegh P, Mojahedi MJ, Malekshah PE, Pezeshkpour F, Vahedian M, Nazemian F, et al. Effect of oral granisetron in uremic pruritus. *Indian J Dermatol Venereol Leprol.* 2007;73:231–4.
- Wikström B, Gellert R, Ladefoged SD, Danda Y, Akai M, Ide K, et al. Kappa-opioid system in uremic pruritus: multicenter, randomized, double-blind, placebo-controlled clinical studies. *J Am Soc Nephrol.* 2005;16:3742–7.
- Ada S, Seçkin D, Budakoğlu I, Özdemir FN. Treatment of uremic pruritus with narrowband ultraviolet B phototherapy: an open pilot study. *J Am Acad Dermatol.* 2005;53:149–51.
- Chou FF, Ho JC, Huang SC, Sheen-Chen SM. A study on pruritus after parathyroidectomy for secondary hyperparathyroidism. *J Am Coll Surg.* 2000;190:65–70.
- Kurban MS, Boueiz A, Kibbi AG. Cutaneous manifestations of chronic kidney disease. *Clin Dermatol.* 2008;26:255–64.
- Hari Kumar KV, Prajapati J, Pavan G, Parthasarathy A, Jha R, Modi KD. Acquired perforating dermatoses in patients with diabetic kidney disease on hemodialysis. *Hemodial Int.* 2010;14:73–7.
- González-Lara L, Gómez-Bernal S, Vázquez-López F, Vivanco-Allende B. Acquired perforating dermatosis: a report of 8 cases. *Actas Dermosifiliogr.* 2014;105:e39–43.
- Wagner G, Sachse MM. Acquired reactive perforating dermatosis. *J Dtsch Dermatol Ges.* 2013;11:723–30, 723–729.
- Tiltz H, Becker JC, Legat F, Schettini AP, Inzinger M, Massone C. Allopurinol in the treatment of acquired reactive perforating collagenosis. *An Bras Dermatol.* 2013;88:94–7.
- Yoshiya H, Okuyama R, Uhara H. Effectiveness of topical maxacalcitol for acquired perforating disorder. *J Am Acad Dermatol.* 2013;68:e181–2.
- Ohe S, Danno K, Sasaki H, Isei T, Okamoto H, Horio T. Treatment of acquired perforating dermatosis with narrowband ultraviolet B. *J Am Acad Dermatol.* 2004;50:892–4.
- Sezer E, Erkek E. Acquired perforating dermatosis successfully treated with photodynamic therapy. *Photodermatol Photoimmunol Photomed.* 2012;28:50–2.
- Girardi M, Kay J, Elston DM, Leboit PE, Abu-Alfa A, Cowper SE. Nephrogenic systemic fibrosis: clinicopathological definition and workup recommendations. *J Am Acad Dermatol.* 2011;65:1095–106, e1097.
- Knopp EA, Cowper SE. Nephrogenic systemic fibrosis: early recognition and treatment. *Semin Dial.* 2008;21:123–8.
- Mathur K, Morris S, Deighan C, Green R, Douglas KW. Extracorporeal photopheresis improves nephrogenic fibrosing dermopathy/nephrogenic systemic fibrosis: three case reports and review of literature. *J Clin Apher.* 2008;23:144–50.
- Leung N, Shaikh A, Cosio FG, Griffin MD, Textor SC, Gloor JM, et al. The outcome of patients with nephrogenic systemic fibrosis after successful kidney transplantation. *Am J Transplant.* 2010;10:558–62.
- Panesar M, Banerjee S, Barone GW. Clinical improvement of nephrogenic systemic fibrosis after kidney transplantation. *Clin Transplant.* 2008;22:803–8.
- Elmholdt TR, Buus NH, Ramsing M, Olesen AB. Antifibrotic effect after low-dose imatinib mesylate treatment in patients with nephrogenic systemic fibrosis: an open-label non-randomized, uncontrolled clinical trial. *J Eur Acad Dermatol Venereol.* 2013;27:779–84.

38. Tran KT, Prather HB, Cockerell CJ, Jacobe H. UV-A1 therapy for nephrogenic systemic fibrosis. *Arch Dermatol*. 2009;14:1170-4.
39. Poisson JL, Low A, Park YA. The treatment of nephrogenic systemic fibrosis with therapeutic plasma exchange. *J Clin Apher*. 2013;28:317-20.
40. Ramaizel L, Sliwa JA. Rehabilitation in nephrogenic systemic fibrosis. *PM&R*. 2009;1:684-6.
41. Schmook T, Budde K, Ulrich C, Neumayer HH, Fritsche L, Stockfleth E. Successful treatment of nephrogenic fibrosing dermopathy in a kidney transplant recipient with photodynamic therapy. *Nephrol Dial Transplant*. 2005;20:220-2.
42. Robinson-Bostom L, DiGiovanna JJ. Cutaneous manifestations of end-stage renal disease. *J Am Acad Dermatol*. 2000;43:975-86, quiz 987-990.
43. Daudén E, Oñate MJ. Calciphylaxis. *Dermatol Clin*. 2008;26:557-68, ix.
44. Ong S, Coulson IH. Diagnosis and treatment of calciphylaxis. *Skinmed*. 2012;10:166-70.
45. Markova A, Lester J, Wang J, Robinson-Bostom L. Diagnosis of common dermopathies in dialysis patients: a review and update. *Semin Dial*. 2012;25:408-18.
46. Pérez L, Fernández-Redondo V, Toribio J. Porphyria cutanea tarda in a dialyzed female patient. *Actas Dermosifiliogr*. 2006;97:115-7.
47. Shieh S, Cohen JL, Lim HW. Management of porphyria cutanea tarda in the setting of chronic renal failure: a case report and review. *J Am Acad Dermatol*. 2000;42:645-52.
48. Guiotoku MM, Pereira FeP, Miot HA, Marques ME. Pseudoporphyria induced by dialysis treated with oral N-acetylcysteine. *An Bras Dermatol*. 2011;86:383-5.
49. Hajheydari Z, Makhloogh A. Cutaneous and mucosal manifestations in patients on maintenance hemodialysis: a study of 101 patients in Sari, Iran. *Iran J Kidney Dis*. 2008;2:86-90.
50. Udayakumar P, Balasubramanian S, Ramalingam KS, Lakshmi C, Srinivas CR, Mathew AC. Cutaneous manifestations in patients with chronic renal failure on hemodialysis. *Indian J Dermatol Venereol Leprol*. 2006;72:119-25.
51. Chauhan S, D'Cruz S, Singh R, Sachdev A. Mees' lines. *Lancet*. 2008;372:1410.
52. Short N, Shah C. Muehrcke's lines. *Am J Med*. 2010;123:991-2.
53. Lin CJ, Wu CJ, Chen YC, Chen HH. Half and half nail secondary to chronic renal failure. *South Med J*. 2009;102:1189-90.