

## Bibliografía

1. Lenz G, Staudt LM. Aggressive Lymphomas. *N Engl J Med*. 2010;362:1417–29.
2. Grange F, Beylot-Barry M, Courville P, Maubec E, Bagot M, Vergier B, et al. Primary cutaneous diffuse large B-cell lymphoma, leg type: Clinicopathologic features and prognostic analysis in 60 cases. *Arch Dermatol*. 2007;143:1144–50.
3. Magro CM, Wang X, Subramaniam S, Darras N, Mathew S. Cutaneous double-hit B-cell lymphoma: An aggressive form of B-cell lymphoma with a propensity for cutaneous dissemination. *Am J Dermatopathol*. 2014;36:303–10.
4. Suárez AL, Pulitzer M, Horwitz S, Pulitzer M, Horwitz S, Moskowitz A, et al. Primary cutaneous B-cell lymphomas: Part I. Clinical features, diagnosis, and classification. *J Am Acad Dermatol*. 2013;69:329.e1-13.
5. Willemze R, Jaffe ES, Burg G, Cerroni L, Berti E, Swerdlow SH, et al. WHO-EORTC classification for cutaneous lymphomas. *Blood*. 2005;105:3768–85.
6. Muniesa C, Pujol RM, Estrach MT, Gallardo F, García-Muret MP, Climent J, et al. Primary cutaneous diffuse large B-cell lymphoma, leg type and secondary cutaneous involvement by testicular B-cell lymphoma share identical clinicopathological and immunophenotypical features. *J Am Acad Dermatol*. 2012;66:650–4.

C. Lloret-Ruiz\*, P. Molés-Poveda, N. Barrado-Solís y E. Gimeno-Carpio

*Servicio de Dermatología, Hospital Arnau de Vilanova, Valencia, España*

\*Autor para correspondencia.

Correo electrónico: [clloretuiz@gmail.com](mailto:clloretuiz@gmail.com)

(C. Lloret-Ruiz).

<http://dx.doi.org/10.1016/j.ad.2015.02.012>

## Psoriatic Cheilitis: A Report of 2 Cases Treated Successfully With Topical Tacrolimus and a Review of the Literature



### Queilitis psoriásica: Un reporte de 2 casos tratados con éxito con tacrolimus tópico y revisión de la literatura

Dear Editor,

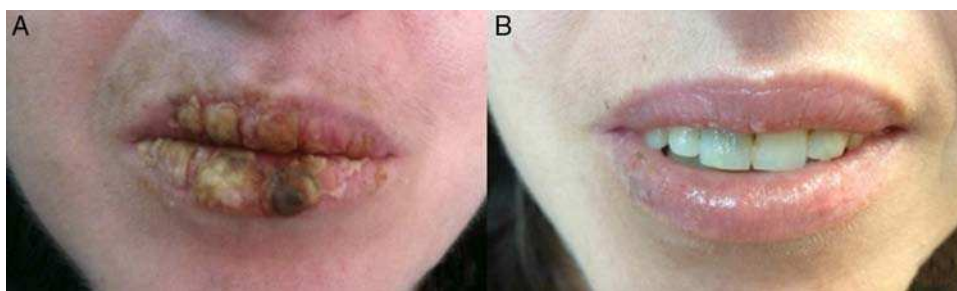
Psoriasis is a chronic inflammatory skin disease that typically affects the extremities, trunk, scalp, and nails. Psoriatic cheilitis as an exclusive presentation is very rare,<sup>1</sup> and to our knowledge, only 5 cases have been reported to date.<sup>2-6</sup> The absence of cutaneous lesions causes diagnostic difficulties that can result in misdiagnosis and inadequate treatment.

We report the cases of 2 young adults who presented with psoriasis of the vermillion of the lips as the only disease manifestation. Response to topical tacrolimus 0.1% treatment was good in both cases.

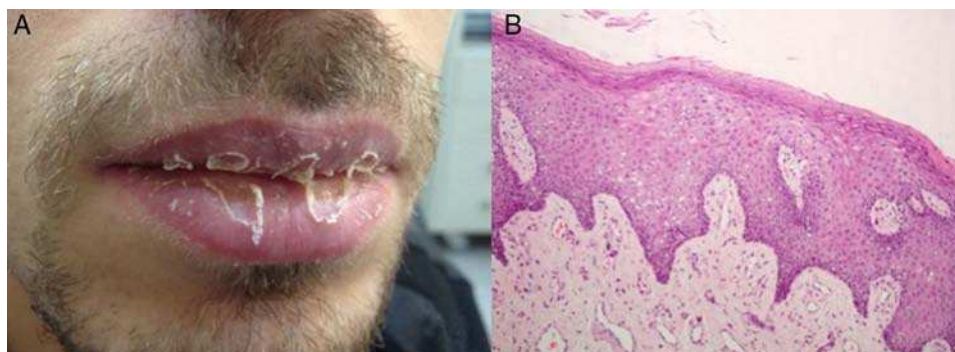The first case involved a 28-year-old white woman referred to our clinic with a 3-month history of scaly plaques on the vermillion of her lips and a clinical

diagnosis of contact cheilitis. Clinical examination revealed an erythematous fissured plaque over the entire upper and lower lip surface, covered by thick white-yellowish scales (Fig. 1A). Full body examination did not reveal any evidence of intraoral or cutaneous involvement. Apart from a 10-year history of Hashimoto thyroiditis, the patient's medical history was unremarkable. However, she did mention that her brother had psoriasis. Contact cheilitis was excluded following negative patch tests. Subsequent biopsy and histological examination confirmed the clinical suspicion of psoriasis. The patient received initial treatment with salicylic acid 5% ointment twice daily for 5 days, followed by a 1-month course of topical tacrolimus 0.1% twice daily, resulting in adequate control of disease activity (Fig. 1B). The patient is currently on maintenance treatment with twice-weekly application of tacrolimus 0.1% ointment.

The second case involved a 20-year-old white man referred to our clinic for further assessment of a 2-year history of recurrent erosive cheilitis, characterized by fissures and white-yellowish scales on the vermillion borders of both lips (Fig. 2A). Intraoral and cutaneous lesions were absent. The patient reported exacerbations, particularly during winter. His medical history was unremarkable; there was, however, a positive family history of psoriasis (his mother). After excluding contact cheilitis by patch



**Figure 1** (a) Thick white-yellowish scales strongly attached to the lips of patient #1 before treatment. (b) Resolution of lesions after treatment with topical tacrolimus.



**Figure 2** (a) Whitish scales on the vermilion borders of both lips in patient 2 before treatment. (b) Mounds of parakeratosis and hypogranulosis, acanthosis, and dilated, vertically elongated papillary vessels (hematoxylin-eosin, original magnification  $\times 20$ ).

**Table 1** Summary of cases of psoriatic cheilitis reported in the literature.

	Sex	Age, y	Skin lesions at presentation	Oral lesions	Treatment	Outcome	Exclusive lip involvement
Tosti et al. <sup>2</sup>	F	24	No	No	Steroid cream	CR	Yes
Rahman et al. <sup>3</sup>	F	20	No	No	Triamcinolone acetonide ointment	CR	Yes
Sehgal et al. <sup>4</sup>	F	16	No	No	Tacrolimus + calcipotriol + betamethasone dipropionate	CR	Yes
Ersoy-Evans et al. <sup>5</sup>	F	19	No	No	Fluticasone propionate 0.005% ointment	CR	No
Baz et al. <sup>6</sup>	F	22	No	No	Mometasone furoate 0.1%	CR	No
Current cases	M	20	No	No	Tacrolimus + salicylic acid	CR	Yes
	F	28	No	No	Tacrolimus + salicylic acid	CR	Yes

*Abbreviations:* CR, complete response; F, female; M, male.

testing, we performed a lip biopsy. Histopathology showed mounds of parakeratosis and hypogranulosis, acanthosis, and dilated and vertically elongated papillary vessels (Fig. 2B), leading to a diagnosis of psoriatic cheilitis. The patient was started on salicylic acid 5% twice daily for 3 days, followed by topical tacrolimus 0.1% twice daily for the next month. The treatment resulted in the gradual remission of lesions, but discontinuation led to a flare-up, which was managed with the same regimen. To avoid recurrences the patient was advised to use tacrolimus 0.1% twice weekly, with excellent results.

Perioral psoriasis is an unusual presentation of psoriasis. It is clinically characterized by cracking and scaling of the lips and can have a profound emotional, social, and physical impact on patients' lives.<sup>1,4</sup> In the vast majority of the cases, coexistence of typical psoriatic lesions elsewhere on the body facilitates diagnosis. To the best of our knowledge, exclusive lip involvement is very uncommon, with only 5 cases reported in the literature.<sup>2-6</sup> In 2 of these cases, involvement of the vermilion of the lips preceded cutaneous manifestations by at least 2 months.<sup>5,6</sup> Brenner et al.<sup>7</sup> reported a case of psoriatic cheilitis triggered by protruding teeth as a result of Koebner phenomenon; the condition was resolved by replacing the teeth with a nonirritating prosthesis. Table 1 summarizes the main epidemiological and clinical characteristics of all the cases reported to date, including ours. Perioral psoriasis as a single site of involvement can pose significant diagnostic difficulties. Due to a lack of specific diagnostic criteria, it has been suggested that a chronic course, with resistance to treatment and fre-

quent recurrences, should raise the suspicion of psoriatic cheilitis.<sup>1</sup> A positive family history and HLA typing have also been described as important in supporting the a diagnosis of perioral psoriasis.

Therapeutic modalities such as topical steroids and tacrolimus alone or in combination with calcipotriol have produced adequate response in patients with perioral psoriasis.<sup>2-6,8</sup> Tacrolimus, a calcineurin-inhibitor with anti-inflammatory properties, lacks the well-known adverse effects associated with steroids. Yamamoto and Nishioka<sup>9</sup> reported a case in which topical tacrolimus ointment was used to treat psoriasis of the vermilion of the lips, with very promising results. Moreover, this treatment combined with salicylic acid gel has been shown to increase the penetration and absorption of the drug, enhancing therapeutic action.<sup>10</sup>

In conclusion, we have described 2 new cases of psoriatic cheilitis with exclusive lip involvement treated successfully with topical tacrolimus 0.1% in combination with salicylic acid, indicating their possible therapeutic role in this troublesome localization. We suggest that psoriasis should be considered in cases of refractory long-standing eczema-like cheilitis, even in the absence of a positive family or personal history of psoriasis.

## Bibliografía

1. Sklavounou A, Laskaris G. Oral psoriasis: report of a case and review of the literature. *Dermatologica*. 1990;180:157-9.

2. Tosti A, Misciali C, Cameli N, Vincenzi C. Guess what! Psoriasis of the lips. *Eur J Dermatol*. 2001;11:589-90.
  3. Rahman MA, Fikree M. Perioral psoriasis. *J Eur Acad Dermatol Venereol*. 2000;14:521-2.
  4. Sehgal VN, Sehgal S, Verma P, Singh N, Rasool F. Exclusive plaque psoriasis of the lips: efficacy of combination therapy of topical tacrolimus, calcipotriol, and betamethasone dipropionate. *J Skin Med*. 2012;10:183.
  5. Ersoy-Evans S, Nuralina L, Erkin G, Ozkaya O. Psoriasis of the lips: a rare entity. *J Eur Acad Dermatol Venereol*. 2007;21:142-3.
  6. Baz K, Yazici AC, Usta A, Ikizoglu G, Apa DD. Isolated lip involvement in psoriasis. *Clin Exp Dermatol*. 2007;32:578-9.
  7. Brenner S, Lipitz R, Llie B, Krakowski A. Psoriasis of the lips: the unusual Köbner phenomenon caused by protruding upper teeth. *Dermatologica*. 1982;164:413-6.
  8. Martí N, Pinazo I, Revert A, Jordá E. Psoriasis of the lips. *J Dermatol Case Rep*. 2009;3:50-2.
  9. Yamamoto T, Nishioka K. Successful treatment with topical tacrolimus for oral psoriasis. *J Eur Acad Dermatol Venereol*. 2006;20:1137-8.
  10. Freeman AK, Linowski GJ, Brady C, Lind L, Vanveldhuisen P, Singer G, et al. Tacrolimus ointment for the treatment of psoriasis on the face and intertriginous areas. *J Am Acad Dermatol*. 2003;48:564-8.
- Z. Apalla<sup>b</sup>, E. Sotiriou<sup>b,\*</sup>, A. Trigoni<sup>a</sup>, D. Ioannides<sup>b</sup>  
<sup>a</sup> *State Clinic, Hospital of Skin and Venereal Diseases, Thessaloniki, Greece*  
<sup>b</sup> *First Dermatology Department, Aristotle University of Thessaloniki, Greece*
- \* Corresponding author.  
 E-mail address: [elenasotiriou@yahoo.gr](mailto:elenasotiriou@yahoo.gr) (E. Sotiriou).
- <http://dx.doi.org/10.1016/j.ad.2015.01.016>

## Uso del triángulo de Burow o escisión en «V» para la reparación de defectos infraorbitarios



## Use of the Burow Triangle or Wedge-shaped Resection During the Repair of Infraorbital Defects

La cirugía reconstructiva del rostro requiere el conocimiento de estructuras anatómicas y funcionales como la nariz, los párpados y los labios, por la importancia de preservar su función, forma y estética.

La reparación de defectos se puede llevar a cabo mediante diferentes técnicas quirúrgicas; la reconstrucción más sencilla y rápida la provee el cierre directo mediante un huso que conlleva un alargamiento de la incisión quirúrgica, con el fin de eliminar el excedente de piel en los extremos. Una técnica para retirar dicho excedente de piel es el triángulo de Burow o escisión en «V»<sup>1</sup>.

El párpado inferior está formado por el músculo periorbicular y revestido por piel delgada y laxa. Inmediatamente por debajo y medial se denomina área infraorbitaria, y por debajo y exterior zona malar; estas 2 por debajo dan lugar a la mejilla. Estas áreas cosméticas faciales tienen diferentes texturas, colores y densidades, desde una piel fina y con mínimo tejido celular subcutáneo (TCS) del párpado hasta la mejilla, donde la piel se engrosa y está fuertemente adherida al TCS<sup>2</sup>.

En la reparación de aquellos defectos que involucren el área infraorbitaria o malar se une piel de la mejilla al párpado con estas marcadas diferencias, y se acompañan del riesgo de provocar que el borde palpebral se evierta, alejándose de la superficie ocular y produciendo un ectropión<sup>3</sup>.

Presentamos una opción de cierre sencillo que minimiza esta posibilidad.

## Técnica quirúrgica

### Primer paso: diseño

La escisión en forma de huso debe ser marcada antes de anestesiar por la distorsión anatómica que esto provoca, luego se diseña el triángulo de Burow en el extremo interno (fig. 1 A).

### Segundo paso: incisión y divulsión de la piel

Es importante la divulsión de los tejidos hacia la mejilla para lograr un mejor deslizamiento. No realizar la divulsión hacia el párpado dada la fragilidad de la piel de la zona.

### Tercer paso: anclaje

El primer punto debe ser fijado en la punta de mayor tensión, es entre el punto a y a' que se observan en las figuras 1 B, C y D. Se realiza con sutura intradérmica no reabsorbible.

### Cuarto paso: suturas externas

Preferimos puntos en «U» horizontal sepultado en el párpado inferior.

En las figuras 2 y 3 se muestran pacientes que fueron intervenidos para la extirpación de un tumor maligno, y el cierre del defecto se efectuó con la técnica descrita.

### Puntos importantes

1. El primer punto a y a' es clave orientarlo en forma diagonal (fig. 1 B) y prevenir la tensión perpendicular al borde libre del párpado, lo que provocaría el ectropión.