



ACTAS Derma-Sifiliográficas

Full English text available at
www.actasdermo.org



CASE REPORT

Purpura Fulminans Associated with *Streptococcus pneumoniae* Septicemia in an Asplenic Pediatric Patient

S. Konda^a, D. Zell^b, C. Milikowski^b, J. Alonso-Llamazares^{b,*}

^a Department of Dermatology, Howard University College of Medicine, Washington, DC, United States

^b Department of Dermatology and Cutaneous Surgery, University of Miami Miller School of Medicine, Miami, United States

KEYWORDS

Purpura fulminans;
Hemorrhagic
necrosis;
*Streptococcus
pneumoniae*;
Sepsis;
Asplenia;
Immunosuppression;
Disseminated
intravascular
coagulation;
Thrombosis

PALABRAS CLAVE

Púrpura fulminante;
Necrosis
hemorrágica;
*Streptococcus
pneumoniae*;
Sepsis;
Asplenia;
Inmunosupresión;
Coagulación
intravascular
diseminada;
Trombosis

Abstract Purpura fulminans is a rapidly progressive syndrome of small-vessel thrombosis and hemorrhagic necrosis of the skin accompanied by disseminated intravascular coagulation. We describe a case of *Streptococcus pneumoniae* septicemia in an asplenic 5-year-old boy on oral tacrolimus, with a past medical history of multivisceral organ transplantation and subsequent development of purpura fulminans on his chest and distal extremities. The acute infectious form of purpura fulminans is usually caused by gram-negative bacteria. Cases secondary to gram-positive encapsulated bacteria usually occur when individuals are immuno-suppressed or have anatomic or functional asplenia. Our patient had both, which likely increased his susceptibility, and he responded well to antimicrobial therapy in addition to prophylactic coverage in the setting of his immunosuppression. We review the literature for similar cases due to *S. pneumoniae* in the pediatric population and discuss the etiology and treatment of purpura fulminans.

© 2011 Elsevier España, S.L. and AEDV. All rights reserved.

Púrpura fulminante en relación con septicemia por *Streptococcus pneumoniae* en un paciente pediátrico asplénico

Resumen La púrpura fulminante es un síndrome rápidamente progresivo de trombosis de pequeños vasos y necrosis hemorrágica de la piel que se acompaña de coagulación intravascular diseminada. Describimos un caso de septicemia por *Streptococcus pneumoniae* en un niño de 5 años de edad tratado con tacrolimus oral, con una historia médica previa de trasplante de múltiples vísceras y sin bazo, y el desarrollo subsiguiente de púrpura fulminante en su pecho y la parte distal de sus extremidades. La forma aguda infecciosa de púrpura fulminante es debida habitualmente a bacterias gramnegativas. Los casos secundarios a bacterias grampositivas encapsuladas ocurren por lo general cuando los individuos están inmunosuprimidos o presentan asplenia funcional o anatómica. Nuestro paciente presentaba ambas condiciones, lo cual con seguridad aumentó su susceptibilidad, y respondió bien a la terapia antimicrobiana

* Corresponding author.

E-mail address: jalonso2@med.miami.edu (J. Alonso-Llamazares).

además de la cobertura profiláctica en el contexto de su inmunosupresión. Revisamos la literatura buscando casos similares debidos a *Streptococcus pneumoniae* en la población pediátrica y discutimos la etiología y el tratamiento de la púrpura fulminante.

© 2011 Elsevier España, S.L. y AEDV. Todos los derechos reservados.

Case report

A 5-year-old Hispanic boy with a past medical history of premature birth at 24 weeks gestation and multivisceral organ transplantation (MVTx) at 2 years of age due to a hepatoblastoma with extensive abdominal compromise was admitted at the ICU with a fever of 103.4° F (39.7°C). He complained of pain in his neck and right leg. He denied the onset of dysuria, cough, or ear pain. The MVTx included the stomach, pancreas, liver, and small and large bowels. He was on oral tacrolimus 1.0mg twice daily to prevent rejection, which was held on admission, and ganciclovir prophylaxis to prevent cytomegalovirus infection secondary to immunosuppression. The transplant did not include a spleen and consequently he received a pneumococcal conjugate vaccine and was on penicillin prophylaxis due to increased risk of infection. He also had a right lower quadrant ileostomy with normal output and denied any gastrointestinal changes.

On initial examination he was in moderate distress, vasodilated, and hypotensive. After a sepsis workup, he was started with broad spectrum of empiric antibiotics including vancomycin, piperacillin, tazobactam, and ceftriaxone. Venous blood gases revealed a severe mixed acidosis and he was started on fluid resuscitation, pressor support, shock doses of hydrocortisone, and subsequently intubated. Lung edema worsened secondary to extracellular fluid leakage and worsening acute respiratory distress syndrome (ARDS) so transplant surgery placed bilateral pleural pigtail drains to improve ventilation. Hypocalcemia was addressed with continuous calcium infusion and renal failure secondary to sepsis was managed with continuous veno venous hemodiafiltration (CVVHDF).

The day after admission, ecchymoses and petechiae with consolidated irregular areas of blue-black hemorrhagic necrosis and a surrounding erythematous border were noted on his chest and distal extremities (Fig. 1). He had cyanotic nailbeds with delayed perfusion. We did not have baseline quantitative or functional coagulation assays and levels of protein C, protein S, and antithrombin III were not measured. The rash progressed to numerous tense bullae, which were drained without debridement of the epidermis, and topical mupirocin was applied with Telfa dressing. The drained fluid was sent for culture and had no microbial growth. The dermatology service was consulted and a skin biopsy from the right arm revealed intraepidermal vesicles with focal epidermal necrosis, dermal hemorrhage, and multiple thrombosed vessels in the superficial and reticular dermis without evidence of vasculitis (Figs. 2 and 3).

Blood cultures came back as predominantly gram positive cocci in chains consistent with *Streptococcus pneumoniae*. The antimicrobial regimen was adjusted to linezolid, vancomycin, meropenem, abelcet, and ganciclovir for active coverage of *S. pneumoniae* septicemia and

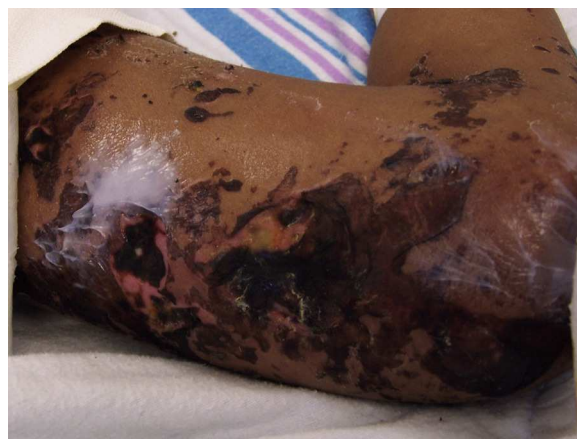

Figure 1 Widespread areas of purpura and necrosis on right lower extremity with lysed bullae and crusting.

prophylactic coverage of other flora. He remained afebrile with a resolving leukocytosis and negative blood cultures and the affected areas continued to resolve with scattered hemorrhagic vesicles and crusts. Heparin or clotting factors were not administered because the patient was improving clinically with the adjusted antibiotic regimen by the time the skin biopsy results were obtained. He was weaned to lower settings on the ventilator, his heart rate and blood pressure stabilized, and tacrolimus was restarted due to subtherapeutic levels. Both pleural pigtail drains were removed without complications and CVVHDF was discontinued. He continued to have intermittent hemodialysis and was eventually extubated without complications.

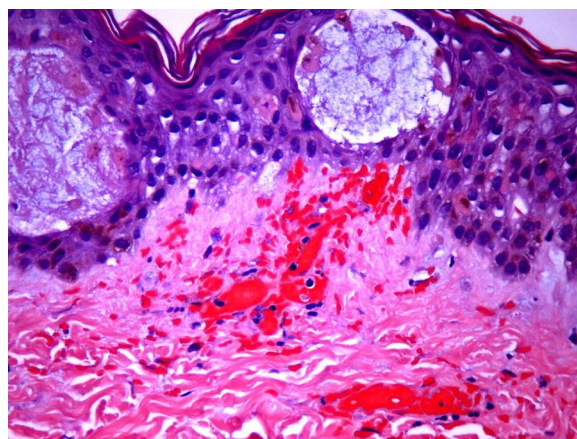


Figure 2 H&E 400×; focally necrotic keratinocytes, spongiotic vesicles, vascular thrombosis and red blood cell extravasation.

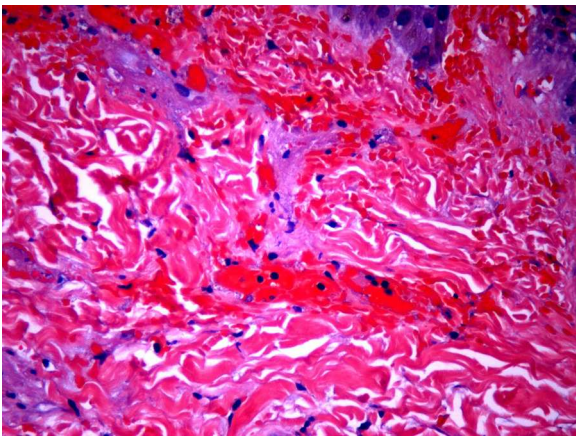


Figure 3 H&E 400 \times ; thrombosed vessel and red blood cell extravasation.

Discussion

Purpura fulminans, also known as purpura gangrenosa, was first described by Guelliot in 1884 and is a rapidly progressive syndrome of intravascular thrombosis and hemorrhagic infarction of the skin. It often occurs in infants and small children and is accompanied by vascular collapse, fever and DIC. The disease is further classified into three forms: neonatal purpura fulminans, idiopathic purpura fulminans, and acute infectious purpura fulminans.¹ We will focus on the third form, acute infectious purpura fulminans, which our pediatric patient was afflicted with.

Acute infectious purpura fulminans (AIPF) is the most common form and usually occurs in the setting of severe sepsis. It is characterized by large purpura, fever, hypotension, and DIC, although all four features may not be present in every patient. The most common infectious culprits are meningococcus and varicella, followed by gram-negative bacilli, staphylococci, *Rickettsia*, measles and streptococci, as described in our case.¹ Including our case, from 1938 to 2011, there have been 19 documented pediatric cases of purpura fulminans in the setting of *S. pneumoniae* septicemia (Table 1). Anatomic or functional asplenia was present in 9 out of 19 patients (47%) and for those cases with documented outcomes, 11 out of 18 patients survived (61%). There was no correlation between the absence or presence of a spleen and survival rates – 5 of 9 asplenic patients survived (56%) and 6 of 9 splenic patients survived (67%).

Gram-negative bacteria are the primary offenders in AIPF due to their ability to harbor endotoxins, such as lipopolysaccharide, in the outer membrane of their cell wall. These endotoxins are potent stimulators of the inflammatory cytokines interleukin (IL)-12, interferon- γ , tumor necrosis factor- α (TNF- α), and IL-1, which consume antithrombin III and proteins C and S. This alters the balance of anticoagulant and procoagulant activity, and ultimately results in a clinical picture of septic shock and DIC. The culprit in our case was a gram-positive encapsulated bacterium, *S. pneumoniae*, which is rare and often occurs in individuals with immuno-suppression or anatomic or functional asplenia – our patient was afflicted with both. Instead of producing endotoxin, *S. pneumoniae* releases

a high-molecular-weight, glycan-teichoic acid fragment released by hydrolysis of the muramic acid-alanine bonds in the bacterial cell wall. This glycan-teichoic acid fragment is pro-inflammatory and propagates the production of TNF- α , IL-1, prostaglandins, and activation of the complement cascade. In return, vascular endothelial cells express increased cell surface leukocyte adhesion molecules, decreased surface co-factors for thrombin activation of protein C, decreased tissue-type plasminogen activator, and increased type 1 plasminogen inhibitor. This cascade ultimately results in DIC and the production of purpura.²

Treatment recommendations for prothrombotic disorders underlying purpura fulminans are still evolving. Management includes supportive therapy, replacement of blood products and clotting factors as appropriate, correction of acid-base and electrolyte abnormalities, and early use of oxygen and mechanical ventilation. Heparin is usually administered as a standard initial therapy to inhibit thrombus formation and consumption of coagulation factors. To avoid further thrombosis, some clinicians favor administering heparin prior to replacement of clotting factors. Protein C has both anti-inflammatory and anticoagulant properties and low levels can be repleted with plasma-derived protein C zymogen concentrates or drotrecogin alpha (activated). Fresh frozen plasma (FFP) is also a source of protein C and protein S, but frequent administration is required to maintain adequate plasma levels. Antithrombin III replacement has also been shown to normalize levels and reverse DIC. Patients who need long-term anticoagulation are transitioned to warfarin therapy with overlapping protein C substitution to prevent warfarin-induced skin necrosis.

Documentation of treatment was obtained for 9 out of 19 patients (Table 1). Treatment modalities included antibiotics, heparin, fresh frozen plasma, cryoprecipitate, and activated protein C. Even though heparin is generally recommended as a standard initial therapy, it was administered to only one patient – in a case from 1970.³ Similarly, only one patient received activated protein C, three received FFP, and one received FFP and cryoprecipitate. Interestingly, 5 of 6 patients survived (83%) after receiving heparin or clotting factors with antibiotics and 3 of 3 patients survived (100%) after receiving antibiotics alone, including our patient. Larger sample sizes are warranted to determine the impact of each of these therapies on survival outcomes of pediatric patients with purpura fulminans.

Additional therapies have been shown to slow the progression of the disease including, recombinant tissue plasminogen activator, prostacyclin, topical nitroglycerin, IV dextran, plasmapheresis, and regional anesthesia. Epsilon aminocaproic acid, vitamin K, ketanserin, hyperbaric oxygen, leech saliva (hirudin), and glucocorticoids have also been utilized with limited anecdotal benefit.

Necrotic tissue should be promptly excised with subsequent wound closure. Further surgical procedures such as escharotomies, fasciotomies, or major amputations might be required once the patient has been stabilized. When amputation is necessary, stump wounds may heal by secondary intention from wound debridement, split-thickness skin grafting, tissue and muscle flaps, plantar skin free transfer, skin expansion, artificial skin, hyperbaric oxygen therapy, and in difficult cases, tissue-engineered skin. In our opinion, early diagnosis and aggressive antibiotic

Table 1 Pediatric purpura fulminans cases due to *Streptococcus pneumoniae*.

Source	Age	History and clinical presentation	Treatment	Outcome
Uhr, 1938 ⁴	9/M	Sepsis	Sulfanilamide	Survived
Adner et al., 1970 ³	5/M	Post-splenectomy for ITP; meningitis and sepsis	Heparin, penicillin G	Survived
Coonrod and Leach, 1976 ⁵	16/M	Post-splenectomy for hypersplenism; sepsis	Died before treatment initiated	Died
Lanzkowsky et al., 1976 ⁶	Child	Post-splenectomy for Hodgkin's disease; sepsis		Died
Cohen et al., 1990 ⁷	2/F	Asplenic; sepsis		Died
Ryan et al., 1993 ⁸	8 month/M	Asplenic; sepsis		Survived
	1/F	Sepsis with Waterhouse–Friderichsen syndrome		Died
Centers for Disease Control and Prevention, 1995 ⁹	3 infants/children (<5 y)	Sepsis		Two died
Cnota et al., 1999 ¹⁰	Child	Meningitis		Unknown
Galanakis et al., 1999 ¹¹	6 month/F	Multiple organ failure, sepsis	FFP, aspirin, penicillin, ceftriaxone, dexamethasone	Survived
Pancharoen et al., 2002 ¹²	3/F	Congenital asplenia; sepsis	Ceftriaxone	Survived
Noguera et al., 2004 ²	13 month/M	Sepsis	FFP, cefotaxime, vancomycin	Survived
Lokeshwar et al., 2006 ¹³	5 month/F	Sepsis	Penicillin G, APC	Survived
Meiners et al., 2006 ¹⁴	11 month/F	Polysplenia; sepsis		Survived
Bertran et al., 2009 ¹⁵	3/F	Congenital asplenia, recurrent pneumonias; sepsis with Waterhouse–Friderichsen syndrome, multiple organ failure	PRBCs, FFP, cryoprecipitate, platelets, corticosteroids, cefotaxime	Died
Intan et al., 2009 ¹	7 month/M	Sepsis	PRBCs, FFP, penicillin, cefotaxime, vancomycin	Survived
Konda et al., 2011 (current case)	5/M	MVTx without a spleen; ARDS, acute renal failure, sepsis	Linezolid, vancomycin, meropenem	Survived

ARDS, acute respiratory distress syndrome; PRBCs, packed red blood cells; APC, activated protein C; FFP, fresh frozen plasma; MVT, multivisceral transplantation.

treatment were key factors in the successful outcome of our patient.

Conflict of interest

The authors declare that they have no conflict of interest.

References

- Intan IH, Rozita AR, Norlijah O. Pneumococcal sepsis presenting as purpura fulminans in a healthy infant. *Ann Trop Paediatr*. 2009;29:235–8.
- Noguera A, Fortuny C, Pons M, Cambra F, Palomeque A. Pneumococcal-associated purpura fulminans in a healthy infant. *Pediatr Emerg Care*. 2004;20:528–30.
- Adner MM, Kauff RE, Sherman JD. Purpura fulminans in a child with pneumococcal septicemia two years after splenectomy. *JAMA*. 1970;213:1681–3.
- Uhr JS. Gangrene of the toes following pneumococemia: treatment with sulfanilamide. *Am J Dis Child*. 1938;56:1317–8.
- Coonrod JD, Leach RP. Antigenemia in fulminant pneumococemia. *Ann Intern Med*. 1976;84:561–3.
- Lanzkowsky P, Shende A, Karayalcin G, Aral I. Staging laparotomy and splenectomy: treatment and complications of Hodgkin's disease in children. *Am J Hematol*. 1976;1:393–404.

7. Cohen JR, Lackner R, Keller A, Douglas B. The surgical implications of purpura fulminans. *Ann Vasc Surg.* 1990;4:276–9.
8. Ryan CA, Wenman W, Henningsen C, Tse S. Fatal childhood pneumococcal Waterhouse–Friderichsen syndrome. *Pediatr Infect Dis J.* 1993;12:250–1.
9. Centers for Disease Control and Prevention. Hemorrhage and shock associated with invasive pneumococcal infection in healthy infants and children – New Mexico, 1993–1994. *MMWR Morb Mortal Wkly Rep.* 1995;43:949–52.
10. Cnota JF, Barton LL, Rhee KH. Purpura fulminans associated with *Streptococcus pneumoniae* infection in a child. *Pediatr Emerg Care.* 1999;15:187–8.
11. Galanakis E, Apokotou M, Alfadaki S, Gesouli E, Lapatsanis P. Purpura fulminans complicating pneumococcal sepsis. *Eur J Pediatr.* 1999;158:171.
12. Pancharoen C, Chatchatee P, Ngamphaiboon J, Thisyakorn U. Recurrent purpura fulminans associated with drug-resistant *Streptococcus pneumoniae* infection in an asplenic girl. *Pediatr Infect Dis J.* 2002;21:80–1.
13. Lokeshwar MR, Singhal T, Udani SV, Kapadia FN. Treatment of acute infectious purpura fulminans with activated protein C. *Indian Pediatr.* 2006;43:535–8.
14. Meiners PM, Leon-Villapalos J, Dziejwski P. Pneumococcal septicemia with Purpura fulminans in an 11-month-old child. *J Plast Reconstr Aesthet Surg.* 2006;59:1377–80.
15. Bertran SK, Donoso FA, Cruces RP, Diaz RF, Arriagada SD. Congenital asplenia and pneumococcal purpura fulminans in a pediatric patient: case report with pathological findings and review. *Rev Chilena Infectol.* 2009;26:55–9.