

La incidencia de las queratosis actínicas en el área palpebral ha aumentado en las últimas 2 décadas. La TFD se ha demostrado efectiva en el tratamiento de carcinoma basocelular, queratosis actínica y enfermedad de Bowen. Recientemente se han comunicado series de casos de pacientes con tumores en el área palpebral tratados eficazmente con TFD¹. En estos casos se recomienda realizar curetaje previo de la lesión, utilizar metil 5-aminolevulinato tópico y repetir una segunda sesión una semana después. Esta opción de tratamiento ofrece mejores resultados estético-funcionales, menor tasa de morbilidad que la asociada a la cirugía, y un menor coste económico que esta última⁵. Entre las limitaciones de este tratamiento destaca el riesgo de daño fototóxico ocular y la necesidad de seguimiento por la posibilidad de recurrencias a largo plazo.

Otra alternativa terapéutica eficaz en casos seleccionados es el imiquimod tópico al 5%. Su aplicación 5 veces por semana durante 6 semanas se ha demostrado eficaz en el tratamiento de tumores de localización periocular⁶. Sin embargo, su uso es controvertido en tumores localizados en el borde libre del párpado o a menos de 5 mm del mismo, por la posibilidad de efectos adversos locales en la región ocular.

En nuestro paciente la evolución fue satisfactoria con TFD, quedando únicamente la presencia de una lesión de queratosis seborreica residual, que no se eliminó con el tratamiento. En conclusión, debemos resaltar que los tumores del área palpebral suponen un reto terapéutico para el dermatólogo. La cirugía continúa siendo el tratamiento de elección, sin embargo la terapia fotodinámica constituye una opción terapéutica no invasiva, eficaz y bien tolerada por el paciente, que ofrece buenos resultados cosméticos y funcionales para tumores localizados en áreas de difícil

tratamiento, tal como pudimos comprobar en el caso presentado.

Bibliografía

1. Togsverd-Bo K, Hædersdal M, Wulf HC. Photodynamic therapy for tumors on the eyelid margins. *Arch Dermatol.* 2009;145:944-7.
2. deSousa J-L, Leibovitch I, Malhotra R, O'Donnell B, Sullivan T, Selva D. Techniques and outcomes of total upper and lower eyelid reconstruction. *Arch Ophthalmol.* 2007;125:1601-9.
3. Braathen LR, Szeimies RM, Basset-Seguín N, Bissonnette R, Foley P, Pariser D, et al. Guidelines on the use of photodynamic therapy for nonmelanoma skin cancer: an international consensus. *International Society for Photodynamic Therapy in Dermatology, 2005. J Am Acad Dermatol.* 2007;56:125-43.
4. Kotimäki J. Photodynamic therapy of eyelid basal cell carcinoma. *J Eur Acad Dermatol Venereol.* 2009;23:1083-7.
5. Vanaclocha F, Daudén E, Badía X, Guillén C, Conejo-Mir JS, Sainz de Los Terreros M, et al. Cost-effectiveness of treatment of superficial basal cell carcinoma: surgical excision vs imiquimod 5% cream. *Br J Dermatol.* 2007;156:769-71.
6. Choontanom R, Thanos S, Busse H, Stupp T. Treatment of basal cell carcinoma of the eyelids with 5% topical imiquimod: a 3-year follow-up study. *Graefes Arch Clin Exp Ophthalmol.* 2007;245:1217-20.

F. Toledo-Alberola*, I. Belinchón-Romero,
J. Guijarro-Llorca y P. Albares-Tendero

Servicio de Dermatología, Hospital General Universitario de Alicante, Alicante, España

* Autor para correspondencia.

Correo electrónico: ftoledo@coma.es (F. Toledo-Alberola).

<http://dx.doi.org/10.1016/j.ad.2011.10.021>

Primary Cutaneous Aspergillosis Complicating Tumor Necrosis Factor- α Blockade Therapy in a Patient With Psoriasis[☆]

Aspergilosis cutánea primaria que complica el tratamiento con inhibidores del factor de necrosis tumoral α en un paciente con psoriasis

To the Editor:

A 52-year-old male farmer with a history of generalized plaque psoriasis and psoriatic arthritis was being treated with etanercept 50 mg once weekly for 3 years with a good response. He presented to our department with painful erythematous nodular lesions on the right forearm (Fig. 1A)

and in the left periorbital region (Fig. 1B). The lesions had appeared 10 days earlier, following a rabbit bite on the forearm. There were no associated systemic symptoms or fever.

A cutaneous biopsy was performed, and as we suspected a fungal infection, the patient was started on itraconazole 100 mg twice daily and etanercept was withdrawn. The biopsy showed an inflammatory infiltrate consisting primarily of polymorphonuclear cells forming abscess-like areas (Fig. 2). Periodic acid-Schiff (PAS) and Grocott-Gomori methenamine-silver staining did not reveal any fungi, but skin culture on solid Sabouraud medium with gentamicin and chloramphenicol (25 °C) revealed *Aspergillus fumigatus* (Fig. 3). The potassium hydroxide (KOH 10%) test did not show hyphae in the microbiological sample and the polymerase chain reaction (PCR) for fungal DNA in the skin was negative. Blood tests and the chest X-ray were normal.

The lesions resolved completely with 4 weeks of treatment with itraconazole. One week after the end of treatment, the patient restarted etanercept and developed no further lesions.

Aspergillus species are ubiquitous and infection occurs most commonly in immunosuppressed individuals,¹⁻³ like

[☆] The work should be attributed to: Department of Dermatology and Venereology, Centro Hospitalar de São João EPE, Porto, Portugal.

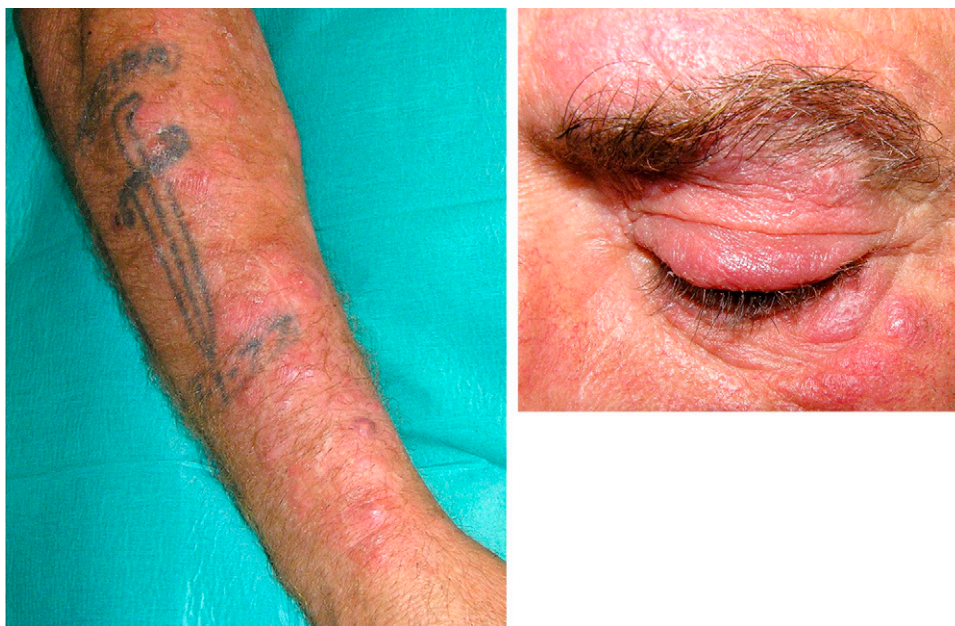

Figure 1 (A) Multiple painful erythematous nodules on the right forearm. (B) Multiple painful erythematous nodules in the left periorbital region.

our patient; indeed, after *Candida* species, these fungi are the most frequent opportunistic pathogens in this group of patients.^{1,2} Cutaneous aspergillosis is normally a manifestation of disseminated disease, which typically begins as a pulmonary infection.¹ Primary cutaneous aspergillosis is rare but it can occur, especially in the case of skin injury,⁴ such as that caused by a rabbit bite.

The skin manifestations of cutaneous aspergillosis are non-specific but are usually characterized by erythematous to violaceous indurated nodules progressing to ulcers with a central eschar.¹ In our case, an early diagnosis prevented this progression.

The erythematous nodules on the forearm of our patient were distributed in a sporotrichoid (lymphocutaneous) pattern, which is seen more often in sporotrichosis and atypical mycobacterial infections (particularly due to *Mycobacterium marinum*) than in aspergillosis. Other unusual agents associated with the sporotrichoid pattern are *Nocardia* species, pyogenic bacteria (*Staphylococcus aureus*, *Streptococcus pyogenes*), and *Pseudallescheria boydii*. Noninfectious causes of this pattern include lymphoma, Langerhans cell histiocytosis, and in-transit metastases. Additionally, perineural spread of leprosy can mimic a lymphocutaneous pattern.⁵

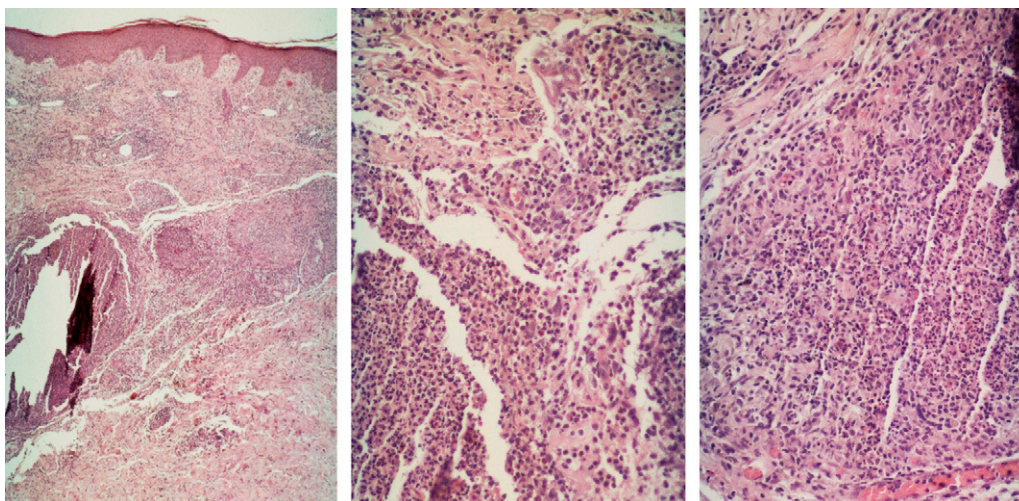


Figure 2 Histological image showing abscess-like areas.

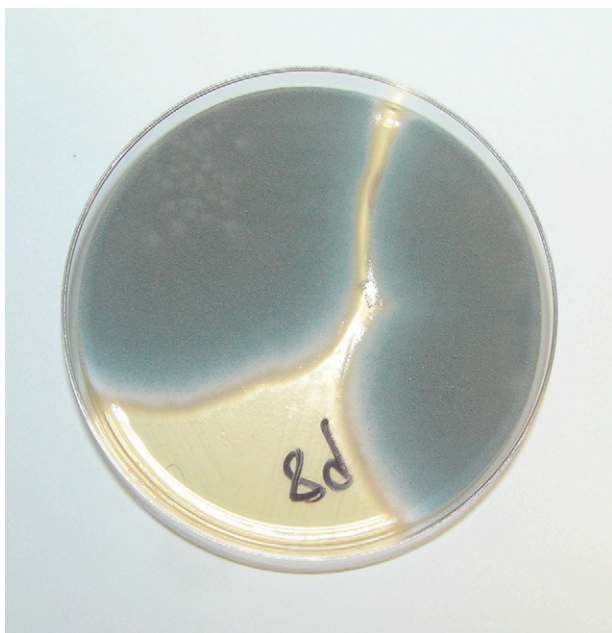


Figure 3 Two colonies of *Aspergillus fumigatus* growing on solid Sabouraud medium with gentamicin and chloramphenicol (25 °C).

The patient also had periorbital lesions, which probably resulted from self-inoculation, with the forearm being the most likely portal of entry.

A diagnosis of aspergillosis is supported by the presence of septated hyphae with acute-angle branching under microscopic examination with special fungal stains (PAS, Grocott),^{1,4} but it must be confirmed by culture.⁴ In disseminated disease, which was not the case in our patient, the serum galactomannan antigen detection test is useful to establish an early diagnosis.⁶ PCR-based testing, which was negative in our case, has yet to be standardized and validated for this purpose.⁶

There are no treatment guidelines for primary cutaneous aspergillosis as there are for disseminated disease,⁶ but reported cases have been successfully treated with amphotericin B, itraconazole, or voriconazole, with or without surgical resection.^{2-4,7} Cutaneous aspergillosis may respond better to treatment than other forms of aspergillosis because it is recognized early, hence allowing rapid institution of treatment,³ as occurred in our case.

Our patient was immunosuppressed due to treatment with etanercept. There are no published data about primary cutaneous aspergillosis in patients treated with tumor necrosis factor- α (TNF- α) blockers but disseminated aspergillosis accounts for 23% of invasive fungal infections in these patients.⁸ TNF- α appears to have an important role in host defenses against *A. fumigatus*, enhancing leukocyte recruitment⁹ and phagocytosis.¹⁰ Furthermore, TNF- α blockade has been seen to increase mortality in animal models infected with *Aspergillus*.⁹ TNF- α blockade appears to increase susceptibility to fungal infections via the

following mechanisms: decreased production of interferon- γ with decreased cellular immune response, decreased toll-like receptor 4 expression with diminished fungal recognition ability, and decreased granuloma formation and phagocytosis.¹¹

To the best of our knowledge, this is the first report of primary cutaneous aspergillosis in a patient with psoriasis treated with a TNF- α blocker. Our case shows the need to monitor patients treated with these blockers and to retain a high index of suspicion of infections, in particular those caused by fungi. Finally, it demonstrates how a patient recently treated with etanercept responded well to anti-fungal therapy.

References

1. Isaac M. Cutaneous aspergillosis. *Dermatol Clin*. 1996; 14:137-40.
2. Galimberti R, Kowalczyk A, Hidalgo Parra I, Gonzalez Ramos M, Flores V. Cutaneous aspergillosis: a report of six cases. *Br J Dermatol*. 1998;139:522-6.
3. Chakrabarti A, Gupta V, Biswas G, Kumar B, Sakhuja VK. Primary cutaneous aspergillosis: our experience in 10 years. *J Infect*. 1998;37:24-7.
4. van Burik JA, Colven R, Spach DH. Cutaneous aspergillosis. *J Clin Microbiol*. 1998;36:3115-21.
5. Sobera JO, Elewski BE. Fungal diseases. In: Bologna JL, Jorizzo JL, Rapini RP, editors. *Bologna: dermatology*. 2nd ed. St Louis: Elsevier; 2008. p. 1135-63.
6. Walsh TJ, Anaissie EJ, Denning DW, Herbrecht R, Kontoyannis DP, Marr KA, et al. Treatment of aspergillosis: clinical practice guidelines of the Infectious Diseases Society of America. *Clin Infect Dis*. 2008;46:327-60.
7. Craiglow B, Hinds G, Antaya R, Girardi M. Primary cutaneous aspergillosis in an immunocompetent patient: successful treatment with oral voriconazole. *Pediatr Dermatol*. 2009;26:493-5.
8. Tsiodras S, Samonis G, Boumpas DT, Kontoyannis DP. Fungal infections complicating tumor necrosis factor α blockade therapy. *Mayo Clin Proc*. 2008;83:181-94.
9. Mehrad B, Strieter RM, Standiford TJ. Role of TNF- α in pulmonary host defense in murine invasive aspergillosis. *J Immunol*. 1999;162:1633-40.
10. Roilides E, Dimitriadou-Georgiadou A, Sein T, Kaditsoglou I, Walsh TJ. Tumor necrosis factor- α enhances antifungal activities of polymorphonuclear and mononuclear phagocytes against *Aspergillus fumigatus*. *Infect Immun*. 1998;66:5999-6003.
11. van der Meer JW, Popa C, Netea MG. Side effects of anticytokine strategies. *Neth J Med*. 2005;63:78-80 [editorial].

F. Osório^{a,*}, S. Magina^{a,b}, F. Azevedo^a

^a *Department of Dermatology and Venereology, Centro Hospitalar de São João EPE, Porto, Portugal*

^b *Institute of Pharmacology and Therapeutics, Faculdade de Medicina da Universidade do Porto, Portugal*

* Corresponding author.

E-mail address: filipaosorio@gmail.com (F. Osório).

<http://dx.doi.org/10.1016/j.ad.2011.12.014>