

- tures and regressing melanoma with nevoid features. *J Cutan Pathol.* 2009;36:913–6.
4. Ferrara G, Giorgio CM, Zalaudek I, Broganelli P, Pellacani G, Tomasini C, et al. Sclerosing nevus with pseudomelanomatous features (nevus with regression-like fibrosis): Clinical and dermoscopic features of a recently characterized histopathologic entity. *Dermatology.* 2009;219:202–8.
 5. Larre Borges A, Zalaudek I, Longo C, Dufrechou L, Argenziano G, Lallas A, et al. Melanocytic nevi with special features: Clinical-dermoscopic and reflectance confocal microscopic-findings. *J Eur Acad Dermatol Venereol.* 2014;28:833–45.

U. Floristán Muruzábal,^{a,*} F.J. Pinedo Moraleda,^b
R. Gamo Villegas,^a J.L. López Estebanz^a

^a Servicio de Dermatología, Hospital Universitario Fundación Alcorcón, Alcorcón, Madrid, Spain

^b Servicio de Anatomía Patológica, Hospital Universitario Fundación Alcorcón, Alcorcón, Madrid, Spain

* Corresponding author.

E-mail address: uxuafloristan@hotmail.com

(U. Floristán Muruzábal).

Allergic Contact Dermatitis Due to Capryloyl Salicylic Acid[☆]



Dermatitis alérgica de contacto por ácido capriloil salicílico

To the Editor:

When cosmetic allergy is suspected, it is essential to include the personal care products used by the patient in the patch tests as not only will this facilitate a more exact diagnosis, but also it may make it possible to identify new allergens. The collaboration of the pharmaceutical and cosmetics industries is fundamental to this approach, as it is those companies that will have to supply us with the components of the specific products. We present a case of allergic contact dermatitis to capryloyl salicylic acid present in an antiwrinkle cream. A 40-year-old woman consulted for a pruritic erythematous rash that arose on her face 10 days after starting to apply an antiwrinkle cream (Revitalift Laser X3 Day Cream by L'Oreal). The condition resolved after interruption of the use of the cream and a week of treatment with a topical corticosteroid. Patch testing was performed using the standard series of the Spanish Contact Dermatitis and Skin Allergy Research Group (GEIDAC), a cosmetics series (Chemotechnique, Sweden), and the specific cream used by the patient, with readings taken at 48 and 96 hours, in accordance with the recommendations of the European Society of Contact Dermatitis (ESCD). In the final reading at 96 hours, a positive reaction (++) was observed to the specific cream used by the patient and negative reactions to the other allergens in the standard and cosmetics series. We contacted the company that marketed the cream involved and they provided us with the 27 ingredients of the cream, thus enabling us to complete the study. A positive allergic reaction (++) to 1% capryloyl salicylic acid in alcohol was observed in the readings taken at 48 and 96 hours (Fig. 1). This same substance showed no allergic responses after patch testing in 15 healthy controls.

Capryloyl salicylic acid (5-capryloyl salicylic acid, CAS no. 78418-01-6, also known as 2-hydroxy-5-octanoylbenzoic

acid) is a lipophilic derivative of salicylic acid that promotes epidermal renewal, stimulates collagen formation, combats chronic actinic photodamage,¹ and increases skin resilience to UV radiation. It is attributed comedolytic,² antiacne,³ antibacterial, and anti-inflammatory⁴ properties. This substance is widely used, mainly by the French cosmetics industry, and it can be included in facial emollients, antiaging formulations, products for the treatment of acne, sunscreens, and facial hygiene products.⁵

De Groot et al.⁵ recently published the first 2 cases of contact allergy to capryloyl salicylic acid, using 1% capryloyl salicylic acid in alcohol in the patch testing of their patients. According to those authors, the allergenicity of this substance may derive more from the salicylic or benzoic part of the molecule than from the caprylic acid fraction. However, Roberts et al.⁶ concluded that 5-capryloyl salicylic acid was probably not the agent responsible for the allergy of the patients described by de Groot et al.; in their opinion, the allergy was due to its 3-capryloyl salicylic acid isomer, a contaminant of 5-capryloyl salicylic acid.

We have described a third case of allergic contact dermatitis to capryloyl salicylic acid, the diagnosis of which was made possible by patch testing the ingredients provided by the company marketing the cream used by the patient, as these substances are not included in other test series. The description of further cases in which capryloyl salicylic acid is implicated will clarify the allergenic potential of this substance.

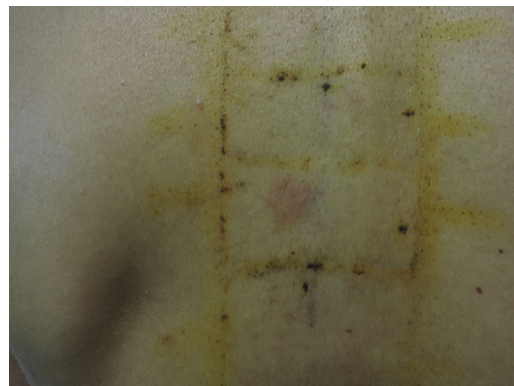


Figure 1 Positive allergic reaction to capryloyl salicylic acid.

[☆] Please cite this article as: González-Pérez R, Carnero-González L, Martínez-González MI. Dermatitis alérgica de contacto por ácido capriloil salicílico. *Actas Dermosifiliogr.* 2016;107:694–695.

Conflicts of Interest

The authors declare that they have no conflicts of interest.

References

- Oresajo C, Yatskayer M, Hansenne I. Clinical tolerance and efficacy of capryloyl salicylic acid peel compared to a glycolic acid peel in subjects with fine lines/wrinkles and hyperpigmented skin. *J Cosmet Dermatol.* 2008;7:259–62.
- Uhoda E, Piérard-Franchimont C, Piérard GE. Comedolysis by a lipohydroxyacid formulation in acne-prone subjects. *Eur J Dermatol.* 2003;13:65–8.
- Bissonnette R, Bolduc C, Seité S, Nigen S, Provost N, Maari C, et al. Randomized study comparing the efficacy and tolerance of a lipophilic hydroxy acid derivative of salicylic acid and 5% benzoyl peroxide in the treatment of facial acne vulgaris. *J Cosmet Dermatol.* 2009;8:19–23.
- Saint-Léger D, Lévêque JL, Verschoore M. The use of hydroxy acids on the skin: Characteristics of C8-lipoxyhydroxy acid. *J Cosmet Dermatol.* 2007;6:59–65.
- De Groot A, Rustemeyer T, Hissink D, Bakker M. Contact allergy to capryloyl salicylic acid. *Contact Dermatitis.* 2014;71:185–7.
- Roberts DW, Aptula AO. Contact allergy to capryloyl salicylic acid: A mechanistic chemistry and structure-activity perspective. *Contact Dermatitis.* 2015;72:347–51.

R. González-Pérez,* L. Carnero-González,
M.I. Martínez-González

*Servicio de Dermatología, Hospital Universitario Araba,
Vitoria-Gasteiz, Araba, Spain*

*Corresponding author.

*E-mail address: ricardo.gonzalezperez@osakidetza.eus
(R. González-Pérez).*

Multimodal Treatment of Calciphylaxis With Sodium Thiosulfate, Alprostadil, and Hyperbaric Oxygen Therapy[☆]



Tratamiento multimodal de la calcifilaxis con tiosulfato sódico, alprostadil y oxigenoterapia hiperbárica

To the Editor:

Calciphylaxis is characterized by calcification of the media of the small arteries and arterioles of the skin, provoking cutaneous ischemia. It affects patients with end-stage renal disease (ESRD) on hemodialysis and carries a high morbidity and mortality, with death most commonly due to sepsis.¹ We describe the case of a patient with calciphylaxis treated successfully with multimodal therapy including sodium thiosulfate (ST) and prostaglandins.

The patient was a 51-year-old woman on hemodialysis for ESRD secondary to polycystic kidney disease. She consulted for ulcers that had appeared on her abdomen and right thigh more than a year earlier; the ulcers produced intense pain refractory to opioid analgesia. Physical examination revealed deep, foul-smelling skin ulcers up to 10 cm in diameter on the anterior surface of the thighs and lower abdomen, with areas of superficial necrotic eschar. The ulcers were situated in extensive areas of livedo racemosa and retiform purpura (Fig. 1, A and B). Important findings in the blood tests were secondary hyperparathyroidism with parathormone levels of 895.8 pg/mL (normal range, 15–65 mg/mL), calcium 9.4 mg/dL (normal range, 8.2–10.3 mg/dL), and phosphorus,

5.8 mg/dL (normal range, 2.7–4.5 mg/dL). Further additional tests to exclude other causes of livedo racemosa, including antinuclear antibodies, antineutrophil cytoplasmic antibodies with antityeloperoxidase and antiproteinase-3 activity, cryoglobulins, anticardiolipin antibodies, and anticitrullinated peptide antibodies, were normal or negative. Skin biopsy showed calcification of the media of vessels in the subcutaneous cellular tissue with focal calcium deposits in subdermal lobules, confirming the diagnosis of calciphylaxis.

The patient was treated with intravenous (IV) ST, 25 mg, administered immediately after each hemodialysis session, with no clinical response. She was receiving 3 hemodialysis sessions per week. Nausea was the only adverse effect. After 36 sessions of IV ST with no clinical response, we added treatment with IV alprostadil, 60 µg, administered during each hemodialysis session. From the first infusion of alprostadil, the patient reported rapid pain relief that enabled the opioids to be withdrawn. With this combination, the skin ulcers and livedo racemosa improved progressively. In order to accelerate healing of the skin ulcers and to reduce the risk of infection, we added treatment with monthly intralesional infiltrations of 10 mL of ST solution, 1/6M, around the borders of the ulcers, without previous anesthesia, and hyperbaric oxygen therapy for 3 months. Hyperbaric oxygen therapy was performed on Monday to Friday each week, with a duration of 60 min per session, at an absolute pressure to 2.4 atmospheres, with a total of 70 sessions. After 5 months of treatment, all the skin ulcers and the livedo racemosa had resolved (Fig. 1, C and D). For more than a year, the patient has continued on maintenance treatment with IV alprostadil during the hemodialysis sessions combined with IV ST after each session and occasional ST infiltrations when small ulcers develop. This multimodal therapy has achieved good overall control of this severe disease more than 2 years after its onset.

The medical treatments most widely used for calciphylaxis are IV ST and the bisphosphonates.² ST has a vasodilator effect that reduces pain and is a chelator of calcium salts, making them more soluble.³ Alprostadil, or prostaglandin

[☆] Please cite this article as: Ossorio-García L, Jiménez-Gallo D, Arjona-Aguilera C, Linares-Barríos M. Tratamiento multimodal de la calcifilaxis con tiosulfato sódico, alprostadil y oxigenoterapia hiperbárica. *Actas Dermosifiliogr.* 2016;107:695–697.